



PATIENT

Hayden Brown

PRESENTING CLINICAL SIGNS

SPECIES

panting during the scan- MCT mass- AUS for met check
Abnormal PE/Chem/CBC/UA Results: azotemic (labs not available)

Canine

ULTRASONOGRAPHIC EXAMINATION OF THE ABDOMEN

BREED

Urinary System

Bernese Mtn Dog

The urinary bladder is moderately distended with anechoic urine. The Bladder wall, trigone, ureteral papillae and visible urethra (to a depth of 2cm) appear normal with no evidence of wall thickening, mucosal irregularities, masses or cystic calculi.

SEX

Neutered Male

The prostate is normal in size and shape for this neutered male dog. The parenchyma is homogenous and the external margins are smooth. The prostatic urethra appears normal with no evidence of irregularity, invasion, mass effect or calculi.

AGE

8 Years

The left kidney has a normal shape and size (5.9 cm) with significant pyelectasia at 0.57 cm. Overall echogenicity is slightly hyperechoic with poor corticomedullary distinction and a typical 1:3 cortex:medulla ratio. There is no evidence of perinephric inflammation or effusion. There is no evidence of nephroliths, infarcts or hydroureter. Renal vasculature is normal.

WEIGHT

95 Pounds

The right kidney has a normal shape and size (5.6 cm) with significant pyelectasia at 0.55 cm. Overall echogenicity is slightly hyperechoic with poor corticomedullary distinction and a typical 1:3 cortex:medulla ratio. There is no evidence of perinephric inflammation or effusion. There is no evidence of nephroliths, infarcts or hydroureter. Renal vasculature is normal.

INTERPRETED BY

Kathleen Sennello DVM,
MS, Diplomate ACVIM
(Small Animal Internal
Medicine)

Adrenal Glands

The left adrenal gland is normal in size measuring 0.68 cm at the caudal pole. It is observed in its normal position cranial to the left renal artery. It is normal in appearance (uniformly hypoechoic) and shape with no evidence of a mass effect.

The right adrenal gland is normal in size measuring 0.64 cm at the caudal pole. It is observed in its normal position between the cranial aspect of the right kidney and the caudal vena cava. It is normal in appearance (uniformly hypoechoic) and shape with no evidence of a mass effect.

IMAGING BY

Loetitia Saint-Jacques,
LVT

Spleen

The spleen is large and slightly irregular. The spleen echotexture is heterogenous and mottled. The blood flow through the hilus and splenic parenchyma appears normal. There is an ill-defined hypoechoic nodule visualized measuring 0.44 cm.

HOSPITAL NAME

North Fork VH

Liver

The liver is subjectively normal in size, and echogenicity with smooth peripheral margins. The parenchyma is heterogenous in echotexture with subtle, indistinct focal mottling. The visible portions of the vasculature and biliary tract appear normal. No focal nodules or cystic lesions are observed.

REFERRING VET

Dr. Kristi Whitten

INVOICE

36040

The gallbladder lumen is moderately distended. The wall of the gall bladder is not thickened and has a smooth mucosal surface. Luminal contents are primarily anechoic. The cystic and common bile ducts are normal/not visible.

DATE

3/9/22



PATIENT

Hayden Brown

SPECIES

Canine

BREED

Bernese Mtn Dog

SEX

Neutered Male

AGE

8 Years

WEIGHT

95 Pounds

INTERPRETED BY

Kathleen Sennello DVM,
MS, Diplomate ACVIM
(Small Animal Internal
Medicine)

IMAGING BY

Loetitia Saint-Jacques,
LVT

HOSPITAL NAME

North Fork VH

REFERRING VET

Dr. Kristi Whitten

INVOICE

36040

DATE

3/9/22

Gastrointestinal

The stomach contains minimal luminal contents. It measures at a normal thickness of <0.7cm with some variability due to the presence of rugal folds. The distinction of the gastric wall layers is adequate and there is no impression of reduced peristaltic activity. No masses or focal lesions were observed.

The visualized areas of duodenum, jejunum and ileum have a relatively uniform diameter with minimal fluid distension. Wall thickness is normal. Bowel loops follow a curvilinear path with distinct wall layering maintaining the typical 1:3 muscularis:mucosa layer ratio. The duodenum measured as normal (between 0.3-0.5cm in wall thickness) and the jejunum measured as normal (between 0.2-0.47cm.) Visualized peristalsis appears appropriate. There were no focal lesions consistent with obstruction or a mass effect observed.

The ileocecal junction was visualized and exhibited normal intact wall layering and is subjectively of normal thickness. Sections of colon are visualized with formed fecal material and gas shadowing distally. There is no observed focal or generalized colon wall thickening or loss of layering.

Pancreas

The pancreas is normal and isoechoic to surrounding mesentery. There is no evidence of nodules or cystic lesions. There is no evidence of regional mesenteric inflammation or fluid.

Free Abdomen

Evaluation of the peritoneal cavity did not reveal any evidence of effusion. There is an occasional prominent mesenteric lymph node visualized measuring 0.55, 0.32, 0.36 cm. the omentum is of normal echogenicity.

Other

A brief view of the heart was submitted. No significant pericardial effusion was seen.

There is a hypoechoic lesion appearing to be a subcutaneous nodule measuring 0.41 cm x 1.08 cm.

There is a hypoechoic mass lesion measuring 3.14 cm in depth and 4.46 cm in diameter, which is hypoechoic and solid, and appears to be subcutaneous. This is labeled as the primary mast cell tumor diagnosed.

PRIMARY FINDINGS

- Large, irregular, mottled spleen with hypoechoic ill-defined nodule – The diffuse splenic changes are non-specific and could be consistent with lymphoid hyperplasia, extramedullary hematopoiesis, infiltrative neoplasia, inflammation, other. Cytology or histopathology would be necessary to get a definitive diagnosis.
- Heterogeneous liver – The diffuse hepatic changes are non-specific and could be consistent with vacuolar hepatopathy, nodular hyperplasia, inflammatory/immune-mediated disease, fibrosis, extramedullary hematopoiesis, toxic hepatopathy (e.g., copper), infiltrative neoplasia (less likely) or other hepatopathy.
- Decreased corticomedullary distinction and pyelectasia in both kidneys – Pyelectasia of



PATIENT

Hayden Brown

the left/right kidney could be consistent with pyelonephritis, chronic renal disease, secondary to PU/PD or fluid therapy (if applicable), other. Mild loss of corticomedullary distinction in both kidneys could be consistent with chronic degenerative disease or interstitial nephrosis.

SPECIES

Canine

- Large, hypoechoic subcutaneous mass effect – This lesion is labeled as the primary mast cell tumor that was identified.

BREED

Bernese Mtn Dog

SECONDARY FINDINGS

- Prominent/visible mesenteric lymph nodes – The prominent abdominal lymph nodes are most consistent with reactive lymphadenitis or lymphoid hyperplasia. Neoplastic infiltration is considered less likely.
- Hypoechoic lesion possibly consistent with a subcutaneous mass – Recommend fine needle aspirate of this lesion to evaluate for possible additional mast cell tumor.

SEX

Neutered Male

AGE

8 Years

There are no overt abdominal mass lesions consistent with metastasis visualized. The spleen is large and mottled, and somewhat irregular. The spleen should be aspirated to look for evidence of infiltrative mast cell disease. Additionally, the liver is somewhat heterogeneous. The appearance of the liver is likely age related and benign, but a fine needle aspirate is recommended.

WEIGHT

95 Pounds

The changes observed in the kidneys are consistent with chronic renal disease. There is bilateral pyelectasia present with no observed obstruction. Recommend urinalysis and culture and blood pressure evaluation.

INTERPRETED BY

Kathleen Sennello DVM,
MS, Diplomate ACVIM
(Small Animal Internal
Medicine)

There is a small hypoechoic subcutaneous structure visualized. Recommend a fine needle aspirate of this lesion to evaluate for possible mast cell disease.

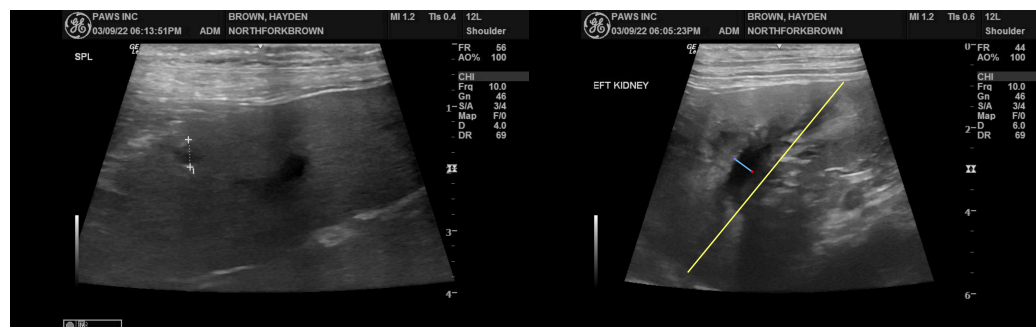IMAGING BY

Loetitia Saint-Jacques,
LVT

Depending on the cytologic results of this additional testing, consider consultation with a veterinary oncologist regarding treatment recommendations and prognosis.

HOSPITAL NAME

North Fork VH



REFERRING VET

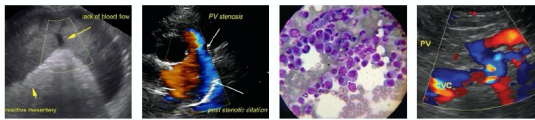
Dr. Kristi Whitten

INVOICE

36040

DATE

3/9/22



PATIENT

Hayden Brown

SPECIES

Canine

BREED

Bernese Mtn Dog

SEX

Neutered Male

AGE

8 Years

WEIGHT

95 Pounds

INTERPRETED BY

Kathleen Sennello DVM,
MS, Diplomate ACVIM
(Small Animal Internal
Medicine)

IMAGING BY

Loetitia Saint-Jacques,
LVT

HOSPITAL NAME

North Fork VH

REFERRING VET

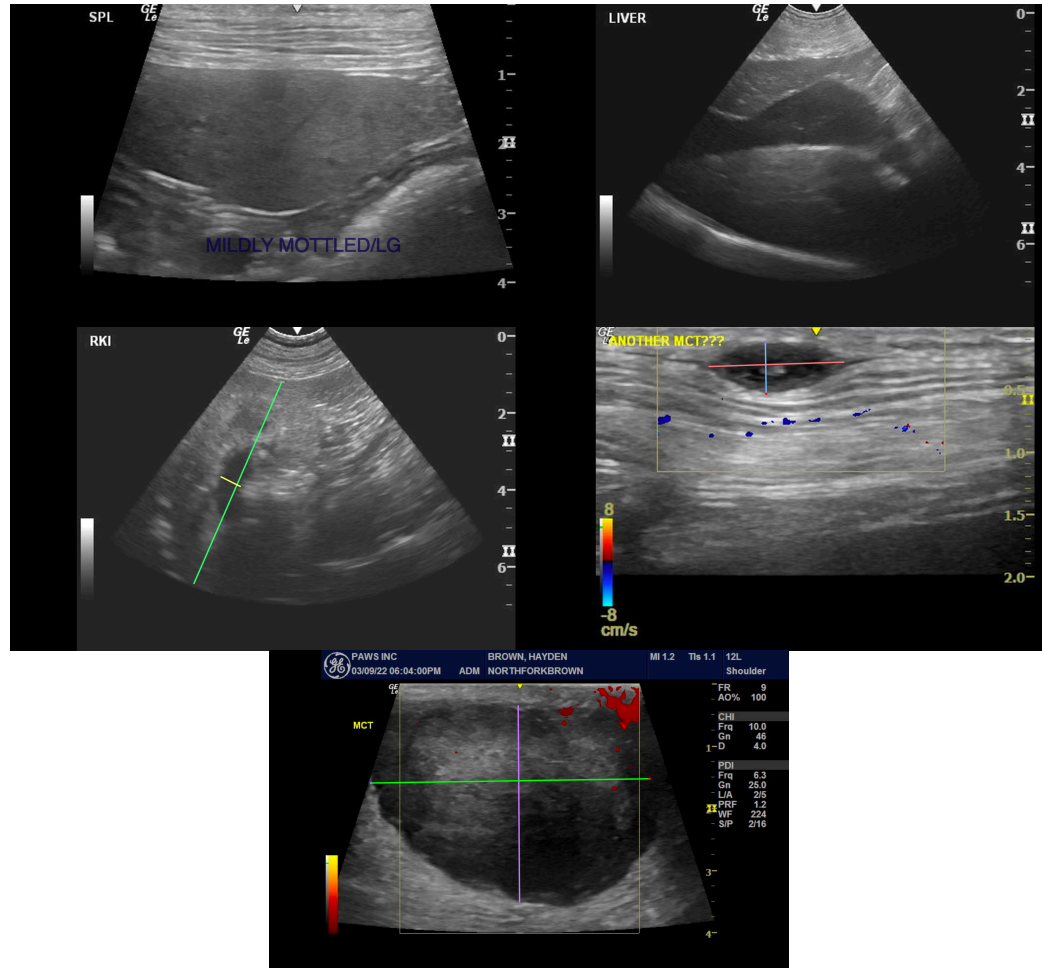
Dr. Kristi Whitten

INVOICE

36040

DATE

3/9/22



The information and recommendations provided are based on the images presented by the referring veterinarian/sonographer. No evaluation can be communicated regarding pathology that was not visible in the image/video clips provided.

Thank you for this referral. If the clinical or image interpretation does not parallel your findings or if I can be of any further assistance please contact me.

Kathleen Sennello DVM,MS, Diplomate ACVIM (Small animal Internal Medicine)
kathleen.sennello@sonopath.com