



PATIENT

Rosie Villa

SPECIES

Canine

BREED

Boxer X

SEX

Spayed Female

AGE

8

WEIGHT

N/A

INTERPRETED BY

Kathleen Sennello DVM,
MS, Diplomate ACVIM
(Small Animal Internal
Medicine)

IMAGING PERFORMED BY

Diane McFadden

HOSPITAL NAME

AH of Roxbury

REFERRING VET

Dr. Elia

INVOICE

45817

DATE

3/9/23

PRESENTING CLINICAL SIGNS

Staging for hemangiosarcoma /melanoma of the mouth. Melanoma panel negative. not on any meds
Abnormal PE/Chem/CBC/UA Results: UA" pH 9, wbc's 4-10, prot 2+, USPG 1.032

ULTRASONOGRAPHIC EXAMINATION OF THE ABDOMEN

Urinary System

Urinary bladder is adequately distended with primarily anechoic contents and occasional echogenic non-shadowing debris. Apical urinary bladder wall is diffusely thick (0.60 cm). Mucosa is hyperechoic and irregular. No masses or cystoliths are observed. The trigone and visible pelvic urethra are normal thickness with a smooth mucosal surface.

The right kidney is normal in size (7.33 cm), shape and echogenicity. It has smooth peripheral margination. There is a normal 1:3 cortex to medulla ratio with appropriate corticomedullary distinction. There is no evidence of pyelectasia, mineral or infarcts observed.

The left kidney is normal in size (6.53 cm), shape and echogenicity. It has smooth peripheral margination. There is a normal 1:3 cortex to medulla ratio with appropriate corticomedullary distinction. There is no evidence of pyelectasia, mineral or infarcts observed.

Adrenal Glands

The right adrenal gland is normal in size (2.23 cm long x 1.0 cm at the cranial pole and 0.47 cm at the caudal pole), shape and contour. Corticomedullary structure is unremarkable. Visible surrounding vasculature appears normal.

The left adrenal gland is normal in size (2.91 cm long x 0.79 cm at the cranial pole and 0.64 cm at the caudal pole), shape and contour. Corticomedullary structure is unremarkable. Visible surrounding vasculature appears normal.

Spleen

The spleen is subjectively normal in size with a normal smooth capsular contour. Parenchyma is appropriately finely textured and homogenous with normal echogenicity relative to surrounding tissue (hyperechoic to liver). No focal nodules or masses are observed. Splenic vasculature appears normal.

Liver

The liver is subjectively normal in size with normal smooth curvilinear peripheral contour. Parenchyma is appropriately hypoechoic to the spleen in echogenicity and appropriately mildly coarse and homogenous in echotexture. No focal lesions are observed. Visible vasculature and biliary tree appear normal without distension or congestion.

The gallbladder is non-distended in size. The wall is smooth without visible thickening. Luminal contents are primarily anechoic. There is no evidence of cystic or common bile duct dilation.

Gastrointestinal

The stomach wall is normal in thickness (canine < 0.5 cm and feline < 0.4 cm) and layering. The lumen of the stomach is empty with no evidence of obstruction, foreign material or infiltrative disease. Pyloric outflow tract appears patent.

The visible small intestines are normal in wall thickness and layering (canine duodenum < 0.5 cm and feline duodenum < 0.4 cm; other < 0.3 cm). Small intestinal motility appears adequate (1-3 contractions



PATIENT

Rosie Villa

per min). The lumen of the small intestine is empty with no evidence of obstruction, foreign material or infiltrative disease.

SPECIES

Canine

The visible colon is normal in wall thickness (< 0.2 cm) and layering. Contents are consistent with normal formed feces and gas.

BREED

Boxer X

Pancreas

The pancreatic parenchyma is appropriately isoechoic to surrounding tissue. Visible capsule is smooth and normal in contour. There is no visible pancreatic duct dilation. There is no evidence of active peripancreatic inflammation.

SEX

Spayed Female

Free Abdomen

There is no evidence of free peritoneal effusion noted in these images.

AGE

8

There is no apparent lymphadenopathy noted in these images.

WEIGHT

N/A

ULTRASONOGRAPHIC FINDINGS

- **Chronic Cystitis** - Urinary bladder wall changes are most consistent with chronic cystitis. Infiltrative neoplasia cannot be ruled out but is considered less likely give the location and diffuse nature of the changes.

INTERPRETATION OF THE FINDINGS & FURTHER RECOMMENDATIONS

Given this patient's reported pyuria and proteinuria, a urine culture is recommended if not recently evaluated. Beyond that, consultation with a veterinary oncologist is recommended for additional treatment and follow up recommendations.

INTERPRETED BY

Kathleen Sennello DVM, MS, Diplomate ACVIM (Small Animal Internal Medicine)

IMAGING PERFORMED BY

Diane McFadden

HOSPITAL NAME

AH of Roxbury

REFERRING VET

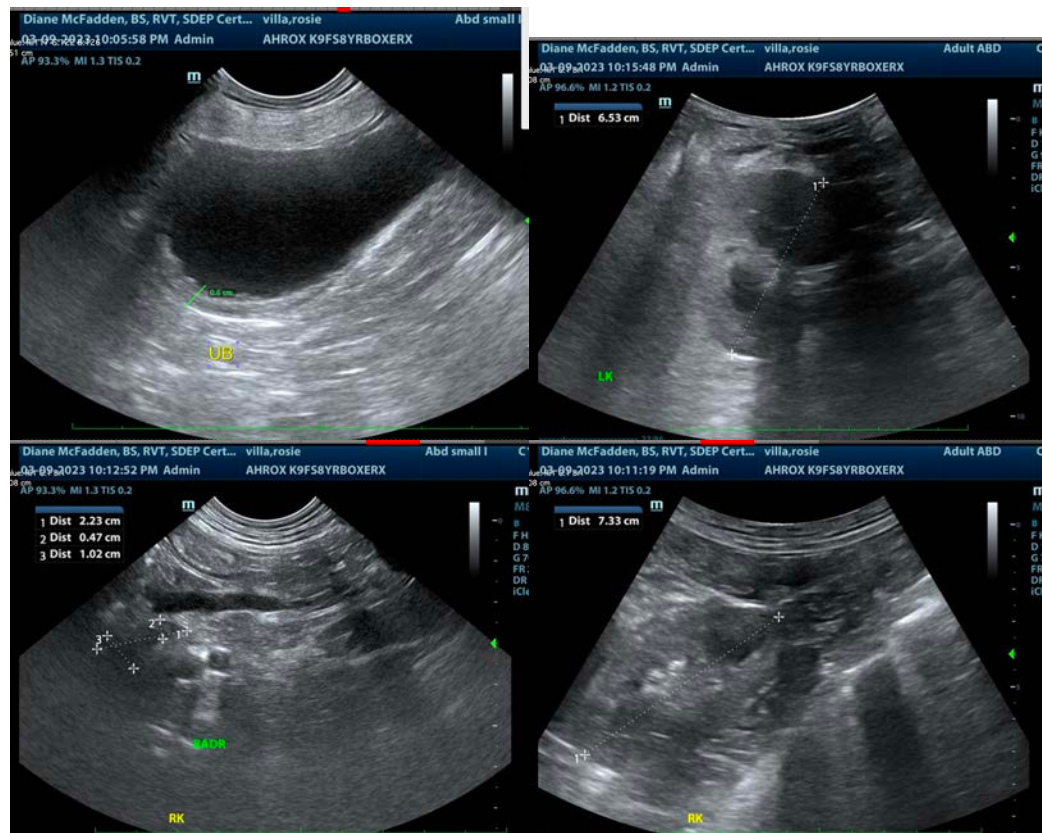
Dr. Elia

INVOICE

45817

DATE

3/9/23





PATIENT

Rosie Villa

SPECIES

Canine

BREED

Boxer X

SEX

Spayed Female

AGE

8

WEIGHT

N/A

INTERPRETED BY

Kathleen Sennello DVM,
MS, Diplomate ACVIM
(Small Animal Internal
Medicine)

IMAGING PERFORMED BY

Diane McFadden

HOSPITAL NAME

AH of Roxbury

REFERRING VET

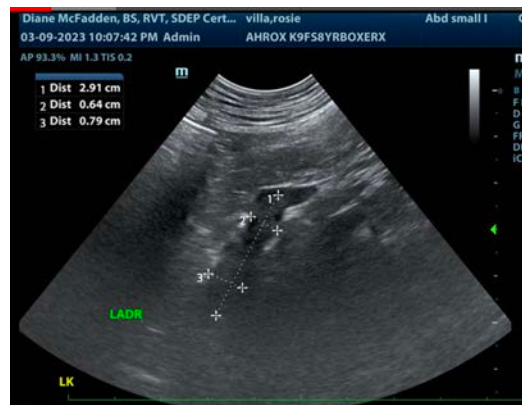Dr. Elia

INVOICE

45817

DATE

3/9/23



The information and recommendations provided are based on the images presented by the referring veterinarian/sonographer. No evaluation can be communicated regarding pathology that was not visible in the image/video clips provided.

Thank you for this referral. If the clinical or image interpretation does not parallel your findings or if I can be of any further assistance please contact me.

Beth Johnson, DVM, DACVIM
Beth.Johnson@sonopath.com