

**DATE**

3/8/22

PRESENTING CLINICAL SIGNS

Occasional vomiting/diarrhea 1-2 times per month. Blood in stool.

Current Medications: Z/D diet started 1/2022.

Lab Results: 1/18/21: Neutrophils 11455, Eosinophils 1015. 1/24/22: PSL high of 40, platelet count high of 813. Urine: USG on the cusp of high end, fat droplets 21-50.

Date of Previous IntraPet Ultrasound: No previous.

Sedation: Not required to complete full diagnostic ultrasound.

Stat Report: Not requested.

Imaging Performed By: Stephanie Pearce RDCS, RVT.

PATIENT

Tess Usaszewski

SPECIES

Feline

BREED

Domestic Shorthair

SEX

Spayed Female

AGE

12/6/11

WEIGHT

12.8 lbs

ULTRASONOGRAPHIC EXAMINATION OF THE ABDOMEN**Urinary System**

The urinary bladder is moderately distended with mild primarily suspended echogenic debris present. The Bladder wall, trigone, ureteral papillae and visible urethra (to a depth of 2cm) appear normal with no evidence of wall thickening, mucosal irregularities, masses or calculi. Echogenic debris of this type can be associated with small crystals, cellular debris and proteinaceous debris.

The left kidney has a normal shape and size (3.96 cm). Overall echogenicity is normal with adequate corticomedullary distinction and a typical 1:3 cortex:medulla ratio. There is no evidence of perinephric inflammation or effusion. There is no evidence of pyelectasia, nephroliths, infarcts or hydroureter. Renal vasculature is normal.

The right kidney has a normal shape and size (4.2 cm). Overall echogenicity is normal with adequate corticomedullary distinction and a typical 1:3 cortex:medulla ratio. There is no evidence of perinephric inflammation or effusion. There is no evidence of pyelectasia, nephroliths, infarcts or hydroureter. Renal vasculature is normal.

INTERPRETED BY

Kathleen Sennello
DVM, MS, Diplomate
ACVIM (Small Animal
Internal Medicine)

Adrenal Glands

The left adrenal gland is normal in size measuring 0.35 cm at the caudal pole. It is observed in its normal position cranial to the left renal artery. It is normal in appearance (uniformly hypoechoic) and shape with no evidence of a mass effect.

The right adrenal gland is normal in size measuring 0.38 cm at the caudal pole. It is observed in its normal position between the cranial aspect of the right kidney and the caudal vena cava. It is normal in appearance (uniformly hypoechoic) and shape with no evidence of a mass effect.

HOSPITAL NAME

Bel Air VH

Spleen

The spleen is subjectively normal in size, echotexture is homogenous, and the splenic capsule is smooth with no irregularities. The blood flow through the hilus and splenic parenchyma appears normal. No focal parenchymal abnormalities are visualized.

REFERRING VET

Dr. Stevenson

INVOICE

96635

Liver

The liver is subjectively normal in size, and echogenicity with smooth peripheral margins. The parenchyma is homogenous echotexture. The visible portions of the vasculature and biliary tract appear normal. No focal nodules or cystic lesions are observed. The gallbladder lumen is moderately distended. The wall of the gallbladder is not thickened and has a smooth mucosal surface. Luminal contents are primarily anechoic. The cystic and common bile ducts are normal/not visible.

Gastrointestinal

The stomach contains minimal luminal contents. It measures at a normal thickness of <0.36cm with some variability due to the presence of rugal folds. The distinction of the gastric wall layers is adequate and there is no impression of reduced peristaltic activity. No masses or focal lesions were observed.

The visualized areas of duodenum, jejunum and ileum have a uniform diameter with minimal fluid distension. Wall thickness is normal to slightly increased. The duodenum measured 0.33 cm and the jejunum measured 0.27 cm. Bowel loops follow a typical curvilinear path with distinct wall layering, but some areas display a prominent muscularis layer which does not display the typical 1:3 muscularis:mucosa layer ratio. Visualized peristalsis appears appropriate. There were no focal lesions consistent with obstruction or a mass effect observed.

The ileocecal junction was visualized and exhibited normal intact wall layering and is subjectively of normal thickness. Sections of colon are visualized with formed fecal material and gas shadowing distally. There is no observed focal or generalized colon wall thickening or loss of layering.

Pancreas

The pancreas is prominent and hypoechoic as compared to the surrounding isoechoic mesentery. There is no evidence of nodules or cystic lesions. There is no evidence of regional mesenteric inflammation or fluid.

Free Abdomen

Evaluation of the peritoneal cavity did not reveal any evidence of effusion, or subjective lymphadenomegaly. The Medial iliac nodes appear normal and there was no evidence of a caudal aortic thrombus at the bifurcation. The omentum is of normal uniform echogenicity.

ULTRASONOGRAPHIC FINDINGS

PRIMARY FINDINGS:

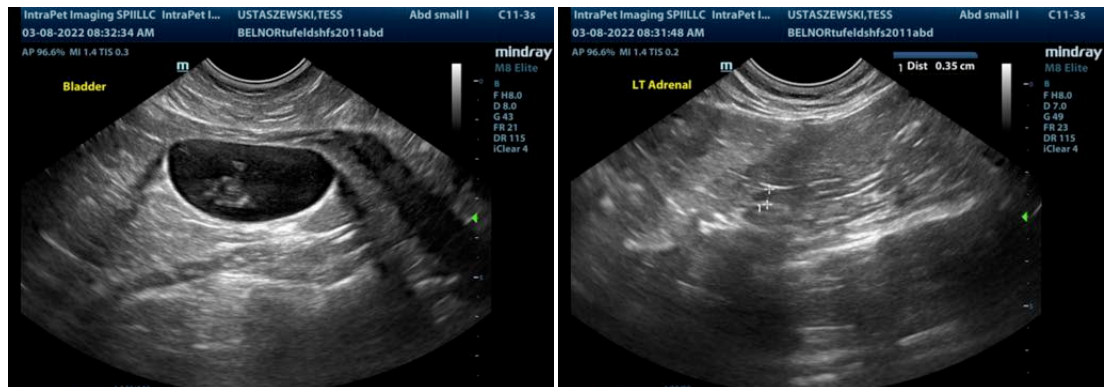
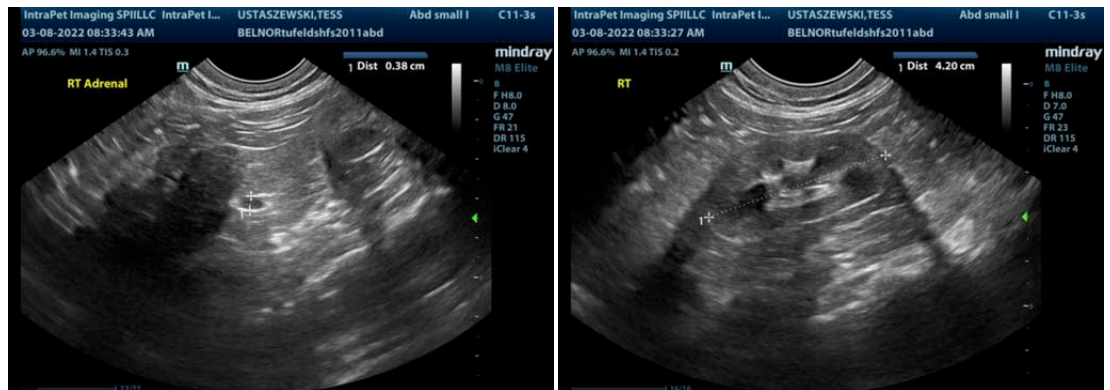
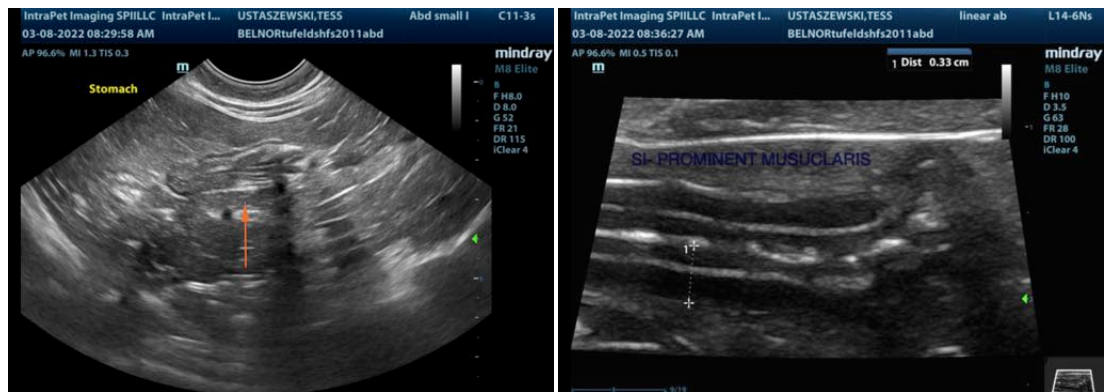
- Echogenic debris in the urinary bladder. The echogenic debris in the bladder lumen could be consistent with cells, crystals, and/or mucus. Recommend urinalysis and culture.
- Hypoechoic, prominent pancreas. The pancreatic changes are most consistent with mild pancreatitis or a recent episode of pancreatic inflammation.
- Prominent muscularis layer to the small intestine. The small intestinal wall changes are most consistent with an inflammatory process (i.e., inflammatory bowel disease) with a low possibility of emerging lymphoma.

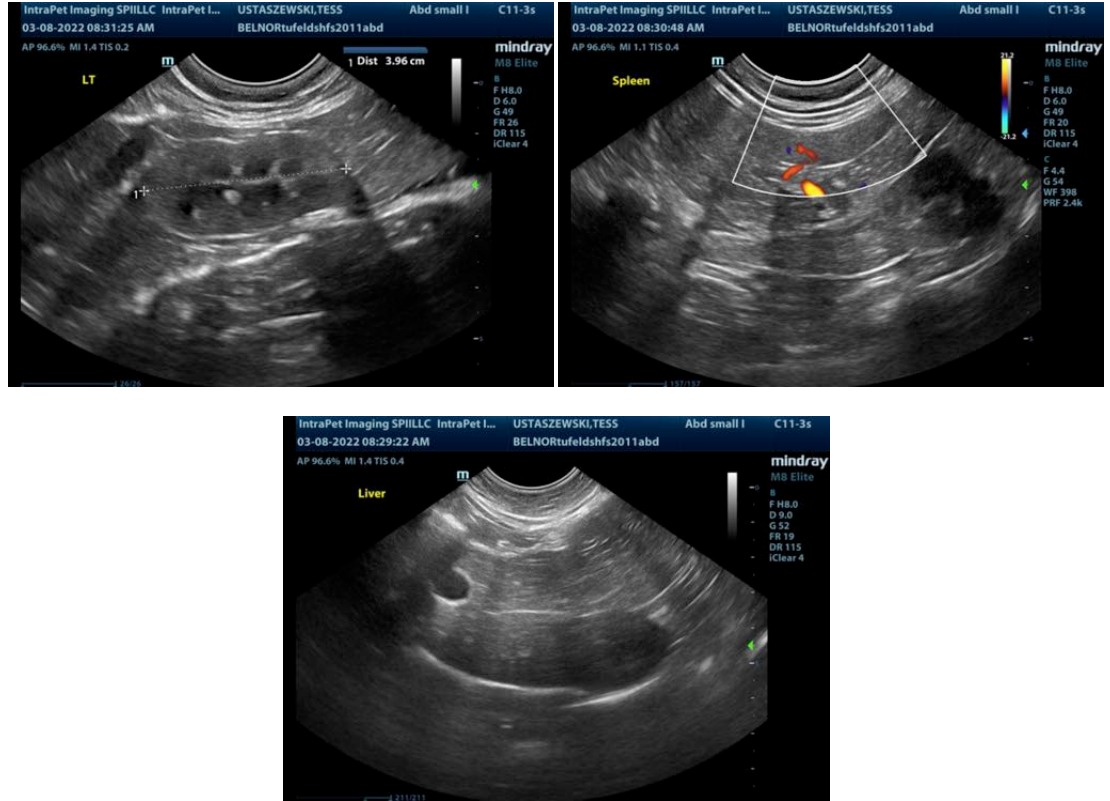
INTERPRETATION OF THE FINDINGS & FURTHER RECOMMENDATIONS

No large focal lesions are observed associated with the gastrointestinal tract. There is a diffusely thickened muscularis layer, which can sometimes associated with inflammatory type processes. Consider a GI panel to Texas A&M for a qualitative fPLI, TLI, cobalamin and folate to further evaluate the pancreatic and small intestinal changes observed. Consider such differentials as dietary intolerance/food allergy, GI parasitism, IBD and less likely intestinal neoplasia.

- Consider a novel protein/hydrolyzed protein prescription diet. You have already made a switch to Z/D diet. If you do not feel that this has been beneficial then you can consider an alternate product.
- Recommend chronic probiotic therapy.

- Recommend the aforementioned GI panel.
- Consider obtaining GI biopsies (upper and lower GI endoscopy?)
- Consider three view thoracic radiographs to rule out concurrent thoracic disease/involvement.
- If not already done consider empirical deworming and testing.





The information and recommendations provided are based on the images presented by the referring veterinarian. No evaluation can be communicated regarding pathology that was not visible in the image/video clips provided.

Thank you for this referral. If the clinical or image interpretation does not parallel your findings or if I can be of any further assistance please contact me.

Kathleen Sennello DVM,MS, Diplomate ACVIM (Small animal Internal Medicine)
kathleen.sennello@sonopath.com