

**DATE PRESENTING CLINICAL SIGNS**

3/8/22 History of hematuria, no bladder stones seen on radiographs, not responding to Enrofloxacin or Convenia inj.

PATIENT Current Medications: Enrofloxacin 22.7mg SID.

Radiographs: See attached.

KitKat Cecala Date of Previous IntraPet Ultrasound: No previous.

Sedation: Not required to complete full diagnostic ultrasound.

Stat Report: Not requested.

SPECIES

Feline

ULTRASONOGRAPHIC EXAMINATION OF THE ABDOMEN**BREED** *Urinary System*

DSH

The urinary bladder is moderately distended with anechoic urine. The Bladder wall is irregular with a large vascular mass evident in the ventral portion of the bladder, measuring 1.61 cm x 1.07 cm. This is approaching the area of the trigone, but there is no evidence of ureteral obstruction or dilation, and the proximal urethra appears relatively normal. No evidence of cystic calculi.

SEX

Spayed Female

The left kidney has a normal shape and size (3.79 cm). Overall echogenicity is normal with adequate corticomedullary distinction and a typical 1:3 cortex:medulla ratio. There is no evidence of perinephric inflammation or effusion. There is no evidence of pyelectasia, nephroliths, infarcts or hydroureter. Renal vasculature is normal.

AGE

8/27/10

The right kidney has a normal shape and size (3.99 cm). Overall echogenicity is normal with adequate corticomedullary distinction and a typical 1:3 cortex:medulla ratio. There is no evidence of perinephric inflammation or effusion. There is no evidence of pyelectasia, nephroliths, infarcts or hydroureter. Renal vasculature is normal.

WEIGHT

10 Pounds

INTERPRETED BY

Kathleen Sennello DVM,
MS, Diplomate ACVIM
(Small Animal Internal
Medicine)

Adrenal Glands

The left adrenal gland is normal in size measuring 0.41 cm at the caudal pole. It is observed in its normal position cranial to the left renal artery. It is normal in appearance (uniformly hypoechoic) and shape with no evidence of a mass effect.

The right adrenal gland is normal in size measuring 0.49 cm at the caudal pole. It is observed in its normal position between the cranial aspect of the right kidney and the caudal vena cava. It is normal in appearance (uniformly hypoechoic) and shape with no evidence of a mass effect.

IMAGING PERFORMED BY

Stephanie Pearce
RDMS, RVT

Spleen

The spleen is subjectively normal in size, echotexture is homogenous, and the splenic capsule is smooth with no irregularities. The blood flow through the hilus and splenic parenchyma appears normal. No focal parenchymal abnormalities are visualized.

HOSPITAL NAME

Creswell Vet Clinic

Liver

The liver is subjectively normal in size, and echogenicity with smooth peripheral margins. The parenchyma is homogenous echotexture. The visible portions of the vasculature and biliary tract appear normal. No focal nodules or cystic lesions are observed.

REFERRING VET

Dr. Cullum

The gall bladder lumen is moderately distended. The wall of the gall bladder is not thickened and has a smooth mucosal surface. There is a moderate amount of non-organized echogenic debris. The cystic and common bile ducts are normal/not visible.

INVOICE

35961

Gastrointestinal

The stomach contains minimal luminal contents. It measures at a normal thickness of <0.36cm with some variability due to the presence of rugal folds. The distinction of the gastric wall layers is adequate and there is no impression of reduced peristaltic activity. No masses or focal lesions were observed.

The visualized areas of duodenum, jejunum and ileum have a uniform diameter with minimal fluid distension. Wall thickness is normal to slightly increased. Bowel loops follow a typical curvilinear path with distinct wall layering, but some areas display a prominent muscularis layer which does not display the typical 1:3 muscularis:mucosa layer ratio. Jejunum wall measured 0.21 cm. Visualized peristalsis appears appropriate. There were no focal lesions consistent with obstruction or a mass effect observed.

The ileocecal junction was visualized and exhibited normal intact wall layering and is subjectively of normal thickness. Sections of colon are visualized with formed fecal material and gas shadowing distally. There is no observed focal or generalized colon wall thickening or loss of layering.

Pancreas

The pancreas is normal and isoechoic to surrounding mesentery. There is no evidence of nodules or cystic lesions. There is no evidence of regional mesenteric inflammation or fluid.

Free Abdomen

Evaluation of the peritoneal cavity did not reveal any evidence of effusion, or subjective lymphadenomegaly. The Medial iliac nodes appear normal and there was no evidence of a caudal aortic thrombus at the bifurcation. The omentum is of normal uniform echogenicity.

PRIMARY FINDINGS

- Large vascular mass effect within the urinary bladder – most consistent with a bladder tumor, no evidence of obstruction.

SECONDARY FINDINGS

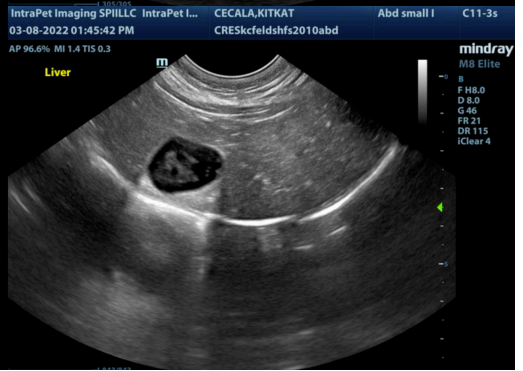
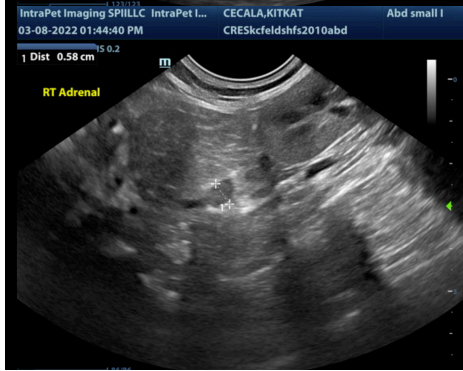
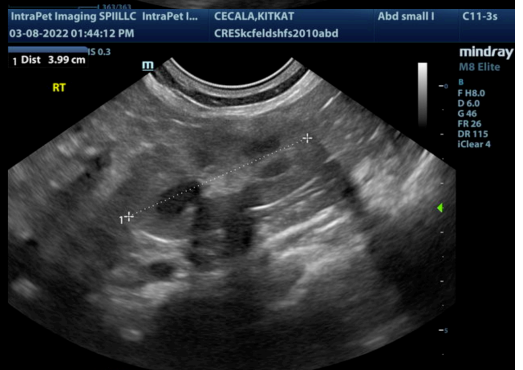
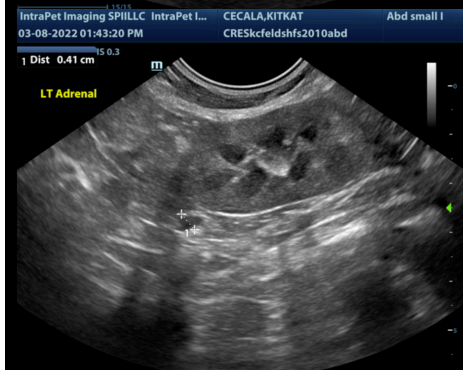
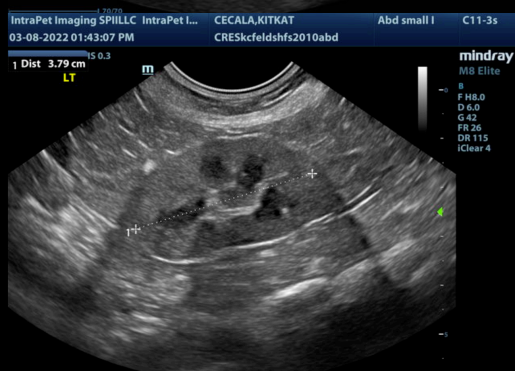
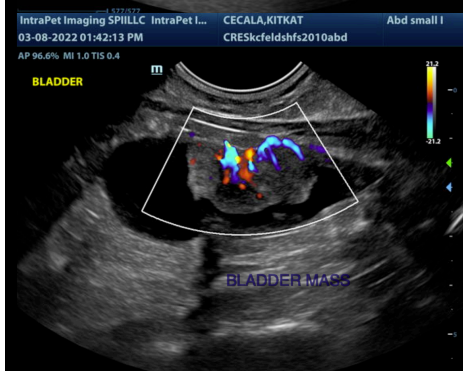
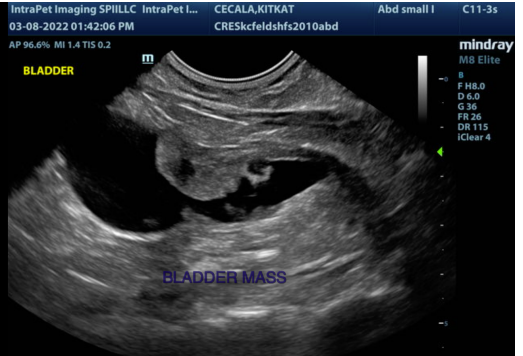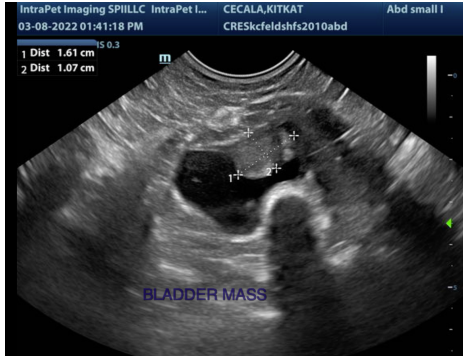
- Mild gallbladder debris
- Prominent muscularis layer to the small intestine - In the absence of any underlying GI signs or weight loss, this is likely an incidental finding in an older cat.

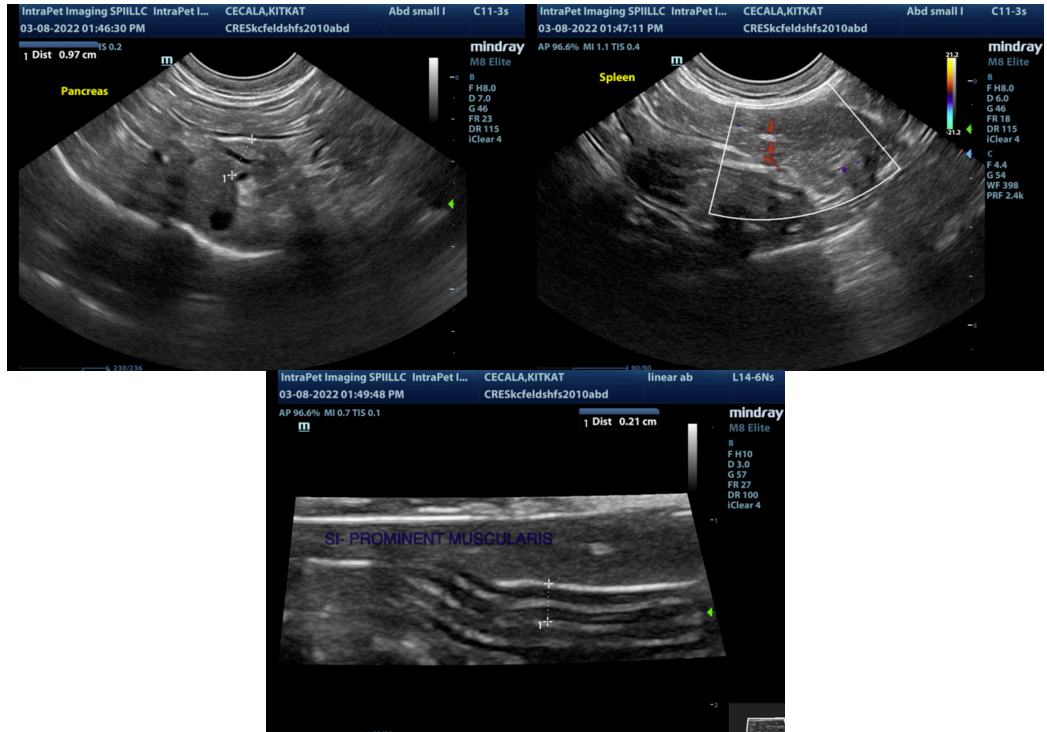
INTERPRETATION OF THE FINDINGS & FURTHER RECOMMENDATIONS

There is a large mass effect within the urinary bladder. This is within the area of trigone, but there is no evidence of either a ureteral or urethral obstruction at this time. Sampling of the mass effect will be necessary to obtain a diagnosis and to make a treatment plan/determine prognosis.

- Options for diagnostics include either a traumatic catheterization (can be difficult in a cat), surgical biopsies, or lastly, a fine needle aspirate can be considered, but there is risk of tracking tumor cells through the abdomen.
- Recommend urinalysis and culture.
- Recommend 3-view thoracic radiographs.

Occasionally, you can submit free catch urine for cytology if there are enough atypical cells present.





The information and recommendations provided are based on the images presented by the referring veterinarian/sonographer. No evaluation can be communicated regarding pathology that was not visible in the image/video clips provided.

Thank you for this referral. If the clinical or image interpretation does not parallel your findings or if I can be of any further assistance please contact me.

Kathleen Sennello DVM,MS, Diplomate ACVIM (Small animal Internal Medicine)
kathleen.sennello@sonopath.com