

**PATIENT**

Lilly Bezanson

SPECIES

Feline

BREED

Siamese

SEX

Spayed Female

AGE

10 Years

WEIGHT

8.8 lbs

INTERPRETED BYKathleen Sennello DVM,
MS, Diplomate ACVIM
(Small Animal Internal
Medicine)**IMAGING
PERFORMED BY**

Nikki Kollman, RVT

HOSPITAL NAMEAirpark Animal
Hospital**REFERRING VET**

Dr. Jonathan Gibson

INVOICE

73419

DATE

3/5/26

PRESENTING CLINICAL SIGNS

P referred to us by ophthalmology for pre surgical work up before eye surgery for a uveal mass with secondary glaucoma. Senior lab work pending. 2 view whole body radiographs wnl

Abnormal PE/Chem/CBC/UA Results: BW pending.

ULTRASONOGRAPHIC EXAMINATION OF THE ABDOMEN**Urinary System**

The urinary bladder is moderately distended with mild/moderate primarily suspended echogenic debris present. The Bladder wall, trigone, ureteral papillae and visible urethra (to a depth of 2cm) appear normal with no evidence of wall thickening, mucosal irregularities, masses or calculi. Echogenic debris of this type can be associated with small crystals, cellular debris and proteinaceous debris.

The left kidney has a normal shape and size (3.57 cm). Overall echogenicity is slightly hyperechoic with mildly reduced corticomedullary distinction and a typical 1:3 cortex:medulla ratio. There is no evidence of focal perinephric inflammation or effusion. There is no evidence of pyelectasia, nephroliths, infarcts or hydroureter. Renal vasculature is normal.

The right kidney has a normal shape and size (3.38 cm). Overall echogenicity is slightly hyperechoic with mildly reduced corticomedullary distinction and a typical 1:3 cortex:medulla ratio. There is no evidence of focal perinephric inflammation or effusion. There is no evidence of pyelectasia, nephroliths, infarcts or hydroureter. Renal vasculature is normal.

Adrenal Glands

The left adrenal gland is normal in size measuring 0.36 cm at the caudal pole. It is observed in its normal position cranial to the left renal artery. It is normal in appearance (uniformly hypoechoic) and shape with no evidence of a mass effect.

The right adrenal gland is normal in size measuring 0.50 cm at the caudal pole. It is observed in its normal position between the cranial aspect of the right kidney and the caudal vena cava. It is normal in appearance (uniformly hypoechoic) and shape with no evidence of a mass effect.

Spleen

The spleen is subjectively normal in size (0.81 cm), echotexture is homogenous, and the splenic capsule is smooth with no irregularities. The blood flow through the hilus and splenic parenchyma appears normal. There is a subtle slightly irregular hypoechoic nodule visualized within the parenchyma.

Liver

The liver is subjectively normal in size, and echogenicity with smooth peripheral margins. The parenchyma is homogenous echotexture. The visible portions of the vasculature and biliary tract appear normal. No focal nodules or cystic lesions are observed.

The gall bladder lumen is moderately distended. The wall of the gall bladder is not thickened and has a smooth mucosal surface. Luminal contents are mild and likely incidental at this time. The cystic and common bile ducts are normal/not visible.



PATIENT

Lilly Bezanson

SPECIES

Feline

BREED

Siamese

SEX

Spayed Female

AGE

10 Years

WEIGHT

8.8 lbs

INTERPRETED BY

Kathleen Sennello DVM,
MS, Diplomate ACVIM
(Small Animal Internal
Medicine)

IMAGING PERFORMED BY

Nikki Kollman, RVT

HOSPITAL NAME

Airpark Animal
Hospital

REFERRING VET

Dr. Jonathan Gibson

INVOICE

73419

DATE

3/5/26

Gastrointestinal

The stomach contains minimal luminal contents. It measures at a normal thickness of <0.36cm with some variability due to the presence of rugal folds. The distinction of the gastric wall layers is adequate and there is no impression of reduced peristaltic activity. No masses or focal lesions were observed.

The visualized areas of duodenum, jejunum and ileum have a relatively uniform diameter with minimal fluid distension. Wall thickness is normal. Bowel loops follow a curvilinear path with distinct wall layering maintaining the typical 1:3 muscularis:mucosa layer ratio. Jejunum wall measures 0.20 cm. Visualized peristalsis appears appropriate. There were no focal lesions consistent with obstruction or a mass effect observed.

Sections of colon are visualized with formed fecal material and gas shadowing distally. There is no observed focal or generalized colon wall thickening or loss of layering.

Pancreas

The area of the pancreas is normal and isoechoic to surrounding mesentery. There is no evidence of nodules or cystic lesions. There is no evidence of regional mesenteric inflammation or fluid.

Free Abdomen

Evaluation of the peritoneal cavity did not reveal any evidence of effusion. There is no significant diffuse lymphadenopathy present. Occasional prominent lymph nodes are visualized, examples measure 0.20 cm and 0.26cm. The omentum is of normal echogenicity.

ULTRASONOGRAPHIC FINDINGS

- Mild/moderate suspended echogenic debris in the urinary bladder – The echogenic debris in the bladder lumen could be consistent with cells, crystals, and/or mucus.
- Age related changes visualized associated with both kidneys.
- Poorly defined irregular hypoechoic nodule in the spleen – There is a non-cavitated, hypoechoic splenic nodule visualized. Differentials include lymphoid hyperplasia, extramedullary hematopoiesis, infiltrative neoplasia, inflammation, other. Cytology or histopathology would be necessary to get a definitive diagnosis.
- Occasional prominent mesenteric lymph nodes – Findings could be consistent with reactive lymph nodes or less likely early neoplastic lymph nodes.
- Prominent right adrenal gland – Recommend continued monitoring. Findings could be consistent with mild hyperplasia, less likely an early mass effect.

INTERPRETATION OF THE FINDINGS & FURTHER RECOMMENDATIONS

The changes observed on today's scan are relatively mild. There is a small, poorly defined hypoechoic nodule in the spleen. This has somewhat of a benign appearance, but an early neoplastic lesion cannot be ruled out. Options moving forward would include a fine needle aspirate or continued monitoring with ultrasound. No significant large primary mass lesions were observed. The left adrenal gland is somewhat prominent and should be monitored but has minimal characteristics consistent with a true mass lesion at this time.



PATIENT

Lilly Bezanson

SPECIES

Feline

BREED

Siamese

SEX

Spayed Female

AGE

10 Years

WEIGHT

8.8 lbs

INTERPRETED BY

Kathleen Sennello DVM,
MS, Diplomate ACVIM
(Small Animal Internal
Medicine)

**IMAGING
PERFORMED BY**

Nikki Kollman, RVT

HOSPITAL NAME

Airpark Animal
Hospital

REFERRING VET

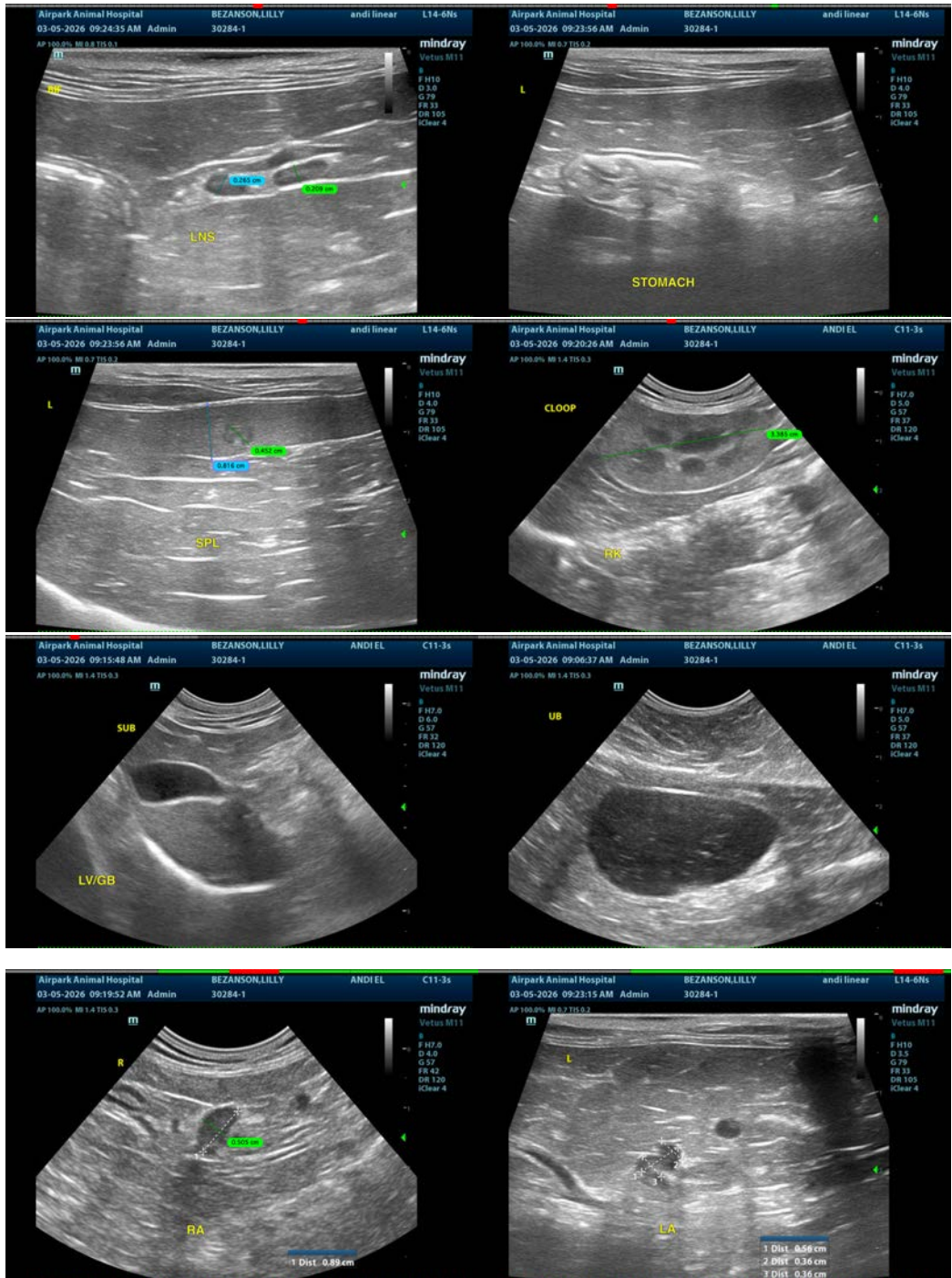
Dr. Jonathan Gibson

INVOICE

73419

DATE

3/5/26





PATIENT

Lilly Bezanson

SPECIES

Feline

BREED

Siamese

SEX

Spayed Female

AGE

10 Years

WEIGHT

8.8 lbs

INTERPRETED BY

Kathleen Sennello DVM,
MS, Diplomate ACVIM
(Small Animal Internal
Medicine)

IMAGING PERFORMED BY

Nikki Kollman, RVT

HOSPITAL NAME

Airpark Animal
Hospital

REFERRING VET

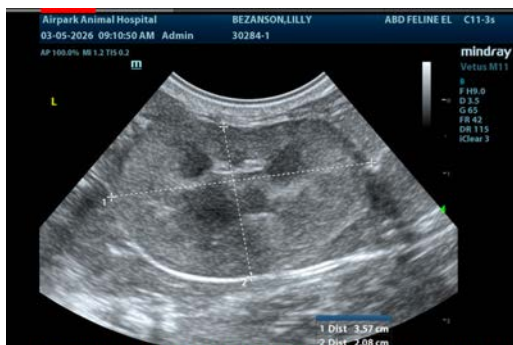Dr. Jonathan Gibson

INVOICE

73419

DATE

3/5/26



The information and recommendations provided are based on the images presented by the referring veterinarian/sonographer. No evaluation can be communicated regarding pathology that was not visible in the image/video clips provided.

Thank you for this referral. If the clinical or image interpretation does not parallel your findings or if I can be of any further assistance please contact me.

Kathleen Sennello DVM,MS, Diplomate ACVIM (Small animal Internal Medicine)

info@sonopath.com