



PATIENT

Nova Opitz-Garrabrandt

SPECIES

Canine

BREED

Miniature Schnauzer

SEX

Spayed Female

AGE

7 Years

WEIGHT

13.2

INTERPRETED BY

Kathleen Sennello DVM,
MS, Diplomate ACVIM
(Small Animal Internal
Medicine)

IMAGING PERFORMED BY

Dr. Casper

HOSPITAL NAME

Hometown Animal
Hospital (Florida)

REFERRING VET

Dr. Sarah Hopkins

INVOICE

73411

DATE

3/4/26

PRESENTING CLINICAL SIGNS

P had sx to remove MCT in 2023- high grade w/ narrow margins. P presented for new R tarsal SQ nodule that was revealed as MCT on FNA. Presented for preops for removal.

ULTRASONOGRAPHIC EXAMINATION OF THE ABDOMEN

Urinary System

The urinary bladder is mildly distended with anechoic urine. The Bladder wall appears mildly diffusely thickened, measuring at 0.27 cm. No focal irregularities noted. The region of the trigone, ureteral papillae and proximal urethra appear free of any mass lesions or calculi. Lack of urine distention interferes with full evaluation of the urinary bladder.

The left kidney has a normal shape and size (3.91 cm) with occasional cortical mineralizations. Overall echogenicity is normal with adequate corticomedullary distinction and a typical 1:3 cortex:medulla ratio. There is no evidence of focal perinephric inflammation or effusion. There is no evidence of pyelectasia, nephroliths, infarcts or hydroureter. Renal vasculature is normal.

The right kidney has a normal shape and size (4.29 cm). Overall echogenicity is normal with adequate corticomedullary distinction and a typical 1:3 cortex:medulla ratio. There is no evidence of focal perinephric inflammation or effusion. There is no evidence of pyelectasia, nephroliths, infarcts or hydroureter. Renal vasculature is normal.

Adrenal Glands

The region of left adrenal (Cranial to left renal artery) is unremarkable but the adrenal is not distinctly visualized. No evidence of a mass effect is visualized.

The region of the right adrenal (between right cranial kidney and vena cava) is unremarkable, but the adrenal is not distinctly visualized. No evidence of a mass effect is visualized.

Spleen

The spleen is subjectively normal in size (1.14 cm), echotexture is homogenous, and the splenic capsule is smooth with no irregularities. The blood flow through the hilus and splenic parenchyma appears normal. No focal parenchymal abnormalities are visualized.

Liver

The liver is subjectively large in size, and normal in echogenicity with smooth peripheral margins. The parenchyma is mildly heterogenous in echotexture with subtle, indistinct focal mottling. The visible portions of the vasculature and biliary tract appear normal. No focal nodules or cystic lesions are observed.

The gall bladder lumen is moderately distended. The wall of the gall bladder is not thickened and has a smooth mucosal surface. Luminal contents are mild and likely incidental at this time. The cystic and common bile ducts are normal/not visible.



PATIENT

Nova Opitz-Garrabrandt

SPECIES

Canine

BREED

Miniature Schnauzer

SEX

Spayed Female

AGE

7 Years

WEIGHT

13.2

INTERPRETED BY

Kathleen Sennello DVM,
MS, Diplomate ACVIM
(Small Animal Internal
Medicine)

IMAGING PERFORMED BY

Dr. Casper

HOSPITAL NAME

Hometown Animal
Hospital (Florida)

REFERRING VET

Dr. Sarah Hopkins

INVOICE

73411

DATE

3/4/26

Gastrointestinal

The stomach contains minimal luminal contents. It measures at a normal thickness of <0.7cm with some variability due to the presence of rugal folds. The distinction of the gastric wall layers is adequate and there is no impression of reduced peristaltic activity. No masses or focal lesions were observed.

The visualized areas of duodenum, jejunum and ileum have a relatively uniform diameter with minimal fluid distension. Wall thickness is normal. Bowel loops follow a curvilinear path with distinct wall layering maintaining the typical 1:3 muscularis:mucosa layer ratio. Jejunum wall measures 0.25 cm. Visualized peristalsis appears appropriate. There were no focal lesions consistent with obstruction or a mass effect observed.

Sections of colon are visualized with formed fecal material and gas shadowing distally. There is no observed focal or generalized colon wall thickening or loss of layering.

Pancreas

The area of the pancreas is normal and isoechoic to surrounding mesentery. There is no evidence of nodules or cystic lesions. There is no evidence of regional mesenteric inflammation or fluid.

Free Abdomen

Evaluation of the peritoneal cavity did not reveal any evidence of effusion, or subjective lymphadenomegaly. The Medial iliac nodes appear normal and there was no evidence of a caudal aortic thrombus at the bifurcation. The omentum is of normal uniform echogenicity.

ULTRASONOGRAPHIC FINDINGS

- Mildly thickened urinary bladder wall – The bladder mucosal changes could be consistent with cystitis or artifactual due to lack of adequate luminal distension. Bladder neoplasia cannot be ruled out but is considered unlikely in this patient.
- Subjectively mildly enlarged/heterogeneous liver – The diffuse hepatic changes are non-specific and could be consistent with vacuolar hepatopathy, nodular hyperplasia, inflammatory/immune-mediated disease, fibrosis, extramedullary hematopoiesis, toxic hepatopathy (e.g., copper), infiltrative neoplasia (less likely) or other hepatopathy.

INTERPRETATION OF THE FINDINGS & FURTHER RECOMMENDATIONS

No definitive metastatic lesions are visualized. The liver subjectively appears somewhat heterogeneous. Correlate with current lab work, looking for liver enzyme elevations. In this breed, a vacuolar hepatopathy would be a common finding, although this can mimic mast cell disease. If this is a significant concern, consider a fine needle aspirate of the liver (provided coagulation parameters are normal).

The urinary bladder wall appears mildly thickened. This is likely due to lack of urine distention. Correlate with urinalysis and reevaluation with a more full bladder.



PATIENT

Nova Opitz-Garrabrandt

SPECIES

Canine

BREED

Miniature Schnauzer

SEX

Spayed Female

AGE

7 Years

WEIGHT

13.2

INTERPRETED BY

Kathleen Sennello DVM,
MS, Diplomate ACVIM
(Small Animal Internal
Medicine)

IMAGING PERFORMED BY

Dr. Casper

HOSPITAL NAME

Hometown Animal
Hospital (Florida)

REFERRING VET

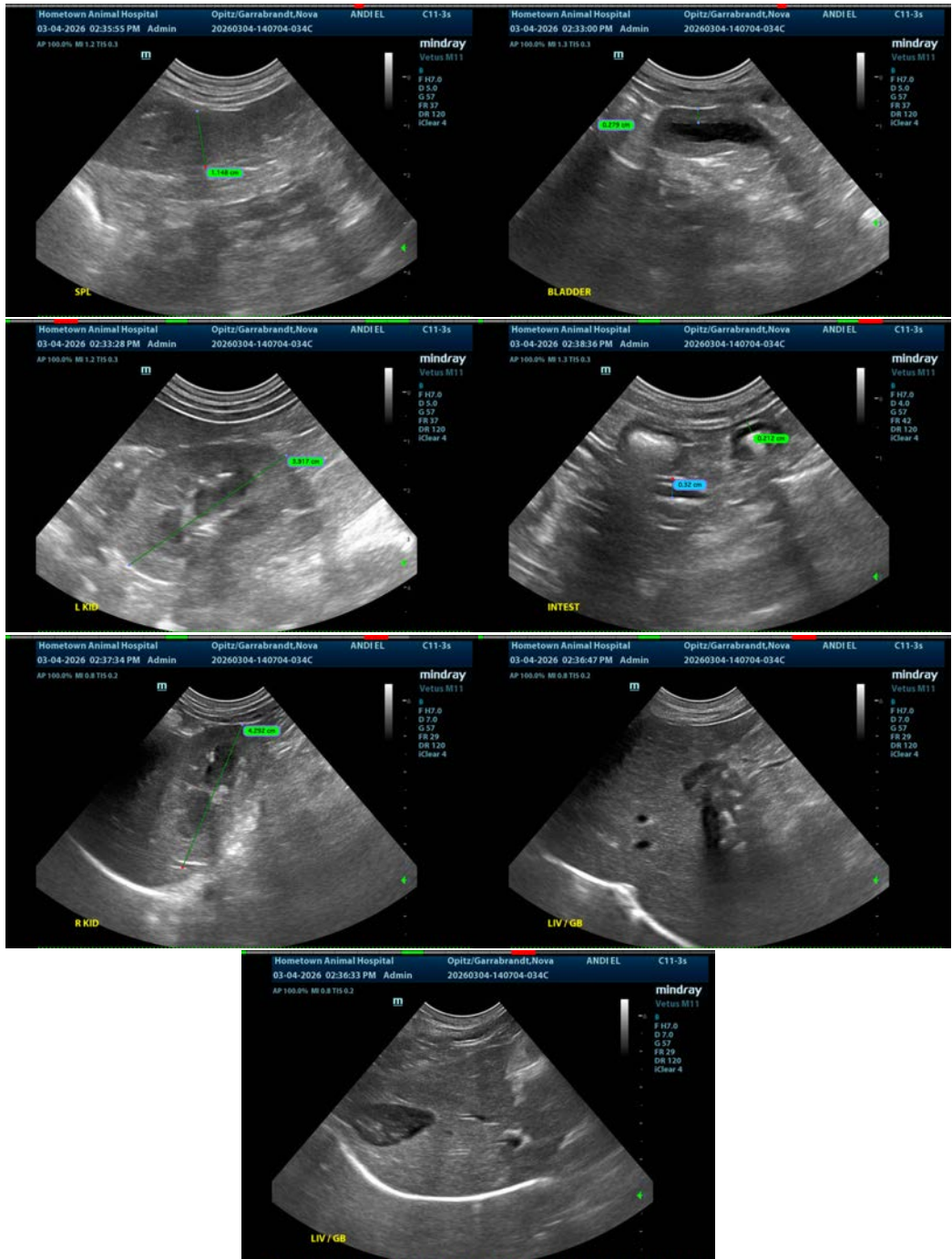
Dr. Sarah Hopkins

INVOICE

73411

DATE

3/4/26





PATIENT

Nova Opitz-Garrabrandt

SPECIES

Canine

BREED

Miniature Schnauzer

SEX

Spayed Female

AGE

7 Years

WEIGHT

13.2

INTERPRETED BY

Kathleen Sennello DVM,
MS, Diplomate ACVIM
(Small Animal Internal
Medicine)

IMAGING PERFORMED BY

Dr. Casper

HOSPITAL NAME

Hometown Animal
Hospital (Florida)

REFERRING VET

Dr. Sarah Hopkins

INVOICE

73411

DATE

3/4/26

The information and recommendations provided are based on the images presented by the referring veterinarian/sonographer. No evaluation can be communicated regarding pathology that was not visible in the image/video clips provided.

Thank you for this referral. If the clinical or image interpretation does not parallel your findings or if I can be of any further assistance please contact me.

Kathleen Sennello DVM,MS, Diplomate ACVIM (Small animal Internal Medicine)

info@sonopath.com