



PATIENT

Ellie Nicholson

SPECIES

Feline

BREED

Snowshoe X

SEX

Spayed Female

AGE

13 Years

WEIGHT

10.9 Pounds

INTERPRETED BY

Kathleen Sennello DVM,
MS, Diplomate ACVIM
(Small Animal Internal
Medicine)

**IMAGING
PERFORMED BY**

Jessica Bailes

HOSPITAL NAME

All Creatures Great &
Small Corvallis

REFERRING VET

Dr. Chantal Litalien

INVOICE

36617

DATE

3/31/22

PRESENTING CLINICAL SIGNS

Initially examined 3/29/22 for evaluation of acute onset diarrhea w/ blood in it. Has been vomiting up food (undigested) intermittently for months. Vomit noted day before exam may have had blood in it. Overgrooming of abdomen noted.

Abnormal PE/Chem/CBC/UA Results: Moderate MCS atrophy, 5-7% dehydrated, otherwise NSF on PE. BW/UA: CHEM: Increased PSL (27), otherwise WNL CBC: thrombocytopenia (124) w/ adequate estimate UA: USG = 1.070; 2+ proteinuria (UPC WNL @ 0.1); IS

ULTRASONOGRAPHIC EXAMINATION OF THE ABDOMEN

Urinary System

The urinary bladder is moderately distended with anechoic urine. The Bladder wall, trigone, ureteral papillae and visible urethra (to a depth of 2cm) appear normal with no evidence of wall thickening, mucosal irregularities, masses or cystic calculi.

The left kidney is normal in size at 3.65 cm. Echogenicity is normal with reduced corticomedullary distinction, but it is irregular in shape, with a 2.5 cm x 2.5 cm, rounded, irregular caudal pole that is isoechoic to the rest of the kidney. Findings are most consistent with a caudal renal mass or focal irregularity.

The right kidney is normal in size (4.41 cm), but irregular in shape. On the cross sectional view, near the caudal pole, is an irregular, ill-defined, hypoechoic projection, approximately 1.2 cm x 1.4 cm. Findings could be consistent with a renal mass lesion or a focal irregularity. Overall echogenicity is normal with mildly decreased corticomedullary distinction and a typical 1:3 cortex:medulla ratio. There is no evidence of perinephric inflammation or effusion. There is no evidence of pyelectasia, nephroliths, infarcts or hydronephrosis. Renal vasculature is normal.

Adrenal Glands

The left adrenal gland is normal in size measuring 0.33 cm at the caudal pole. It is observed in its normal position cranial to the left renal artery. It is normal in appearance (uniformly hypoechoic) and shape with no evidence of a mass effect.

The right adrenal gland is normal in size measuring 0.22 cm at the caudal pole. It is observed in its normal position between the cranial aspect of the right kidney and the caudal vena cava. It is normal in appearance (uniformly hypoechoic) and shape with no evidence of a mass effect.

Spleen

The spleen is borderline large in size (1.1 cm in width at the level of the hilus), echotexture is homogenous, and the splenic capsule is smooth with no irregularities. The blood flow through the hilus and splenic parenchyma appears normal. No focal parenchymal abnormalities are visualized.

Liver

The liver is subjectively normal in size, and echogenicity with smooth peripheral margins. The parenchyma is homogenous echotexture. The visible portions of the vasculature and biliary tract appear normal. No focal nodules or cystic lesions are observed.

The gallbladder lumen is moderately distended. The wall of the gall bladder is not thickened and has a smooth mucosal surface. Luminal contents are primarily anechoic. The cystic and common bile ducts are normal/not visible.



PATIENT

Ellie Nicholson

SPECIES

Feline

BREED

Snowshoe X

SEX

Spayed Female

AGE

13 Years

WEIGHT

10.9 Pounds

INTERPRETED BY

Kathleen Sennello DVM,
MS, Diplomate ACVIM
(Small Animal Internal
Medicine)

**IMAGING
PERFORMED BY**

Jessica Bailes

HOSPITAL NAME

All Creatures Great &
Small Corvallis

REFERRING VET

Dr. Chantal Litalien

INVOICE

36617

DATE

3/31/22

Gastrointestinal

The stomach is moderately fluid distended. It measures at a normal thickness of <0.36cm with some variability due to the presence of rugal folds. The distinction of the gastric wall layers is adequate and there is no impression of reduced peristaltic activity. No masses or focal lesions were observed.

Some of the visualized areas of duodenum, jejunum and ileum have a uniform diameter with minimal fluid distension. Other areas have moderate fluid distention. In most areas there is distinct wall layering, but particularly in the cranial abdomen in the area of the duodenum, the bowel appears somewhat thickened with decreased distinction of layering. Duodenum wall measured 0.29 cm. Jejunum wall measured 0.27 cm. Visualized peristalsis appears appropriate. There were no focal lesions consistent with obstruction or a mass effect observed.

The ileocecal junction was visualized and exhibited normal intact wall layering and is subjectively of normal thickness. Sections of colon are visualized with formed fecal material and gas shadowing distally. There is no observed focal or generalized colon wall thickening or loss of layering.

Pancreas

The pancreas is prominent and mottled compared to the surrounding isoechoic mesentery. Adjacent to the duodenum, the right limb of the pancreas appears irregular with several ill-defined structures, most consistent with prominent regional lymph nodes, although pancreatic nodules cannot be excluded. Lesions in this area measure 0.75 cm and 0.42 cm.

Free Abdomen

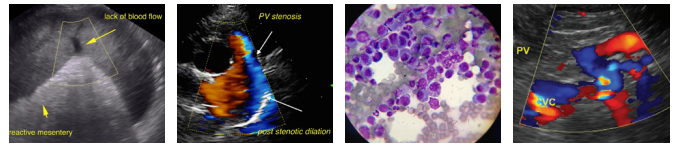
Evaluation of the peritoneal cavity did not reveal any evidence of effusion. Mesenteric lymph nodes appear prominent with ill-defined lymph nodes visualized measuring 0.31 cm and 0.29 cm. The omentum appears of increased echogenicity in the area around the duodenum and the pancreas.

PRIMARY FINDINGS

- Large, irregular mass effect involving the caudal pole of the left kidney – This could be a benign or cancerous lesion. Consider fine needle aspirate.
- Irregular right kidney – On cross sectional views, the right kidney is irregular with a slight hypoechoic projection. This could be consistent with a mass effect or a structural irregularity.
- Mottled, prominent pancreas with focal enlarged lymph nodes or nodules – The pancreatic changes are most consistent with mild pancreatitis or a recent episode of pancreatic inflammation. The focal structures in the region of the pancreas are most consistent with a regional lymphadenopathy, although pancreatic nodules cannot be excluded as a possibility.
- Thickened bowel wall with mildly reduced detail of layering – Findings could be consistent with inflammation, infection or infiltrative neoplasia.
- Mild mesenteric lymphadenopathy – The prominent abdominal lymph nodes are most consistent with reactive lymphadenitis or lymphoid hyperplasia. Neoplastic infiltration is considered less likely.

ULTRASONOGRAPHIC FINDINGS

- Borderline enlarged spleen – No focal abnormalities are noted. This is likely within normal limits for this larger cat.



PATIENT

Ellie Nicholson

SPECIES

Feline

BREED

Snowshoe X

SEX

Spayed Female

AGE

13 Years

WEIGHT

10.9 Pounds

INTERPRETED BY

Kathleen Sennello DVM,
MS, Diplomate ACVIM
(Small Animal Internal
Medicine)

**IMAGING
PERFORMED BY**

Jessica Bailes

HOSPITAL NAME

All Creatures Great &
Small Corvallis

REFERRING VET

Dr. Chantal Litalien

INVOICE

36617

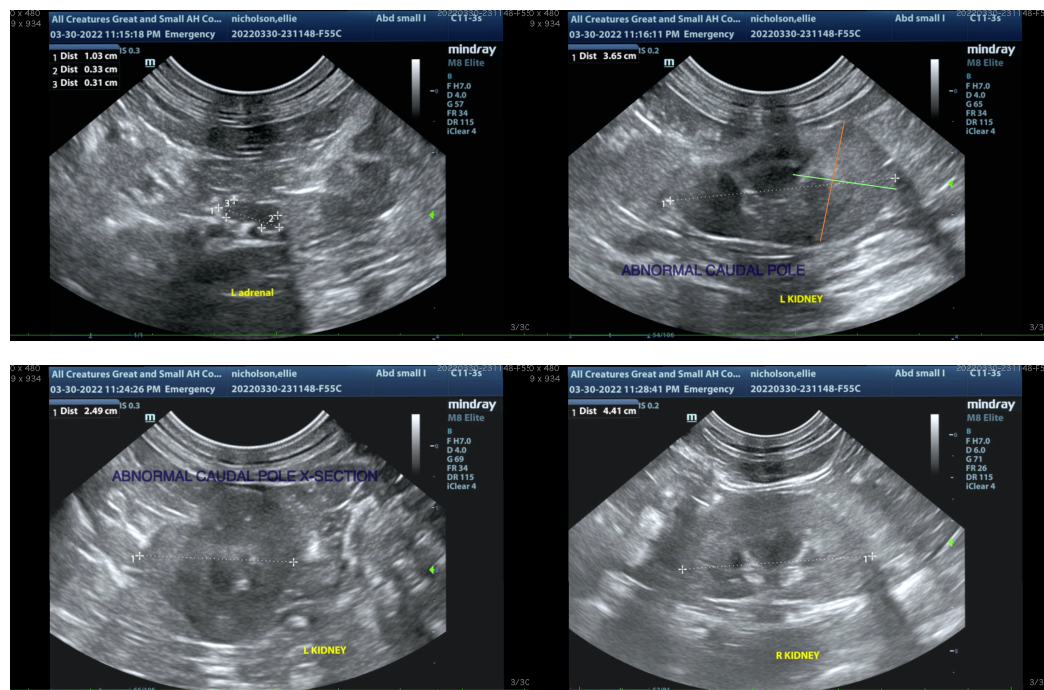
DATE

3/31/22

INTERPRETATION OF THE FINDINGS & FURTHER RECOMMENDATIONS

The general impression in the cranial abdomen is of thickened, inflamed, mildly fluid filled bowel, fluid filled stomach, and irregularity/inflamed tissue in the region of the duodenum and pancreas. Additionally, both kidneys are irregular with a more distinct mass effect in the caudal pole of the left kidney, and an irregularly shaped right kidney. These changes are concerning for a possible mass effect, although other differentials exist.

- Consider a fine needle aspirate of the caudal pole of the left kidney.
- Consider three view thoracic radiographs to rule out concurrent thoracic disease/involvement.
- Consider a GI panel to Texas A&M for a qualitative fPLI, TLI, cobalamin and folate to further evaluate for pancreatic and small intestinal disease.
- Compare ultrasonographic findings with radiographic findings and consider serial imaging if there is any concern for ingested foreign material.
- Consider hydrolyzed protein/novel protein diet.
- If symptoms persist, consider surgery to biopsy the small intestine, stomach, pancreas, mesenteric lymph nodes, and possibly kidney.





PATIENT

Ellie Nicholson

SPECIES

Feline

BREED

Snowshoe X

SEX

Spayed Female

AGE

13 Years

WEIGHT

10.9 Pounds

INTERPRETED BY

Kathleen Sennello DVM,
MS, Diplomate ACVIM
(Small Animal Internal
Medicine)

**IMAGING
PERFORMED BY**

Jessica Bailes

HOSPITAL NAME

All Creatures Great &
Small Corvallis

REFERRING VET

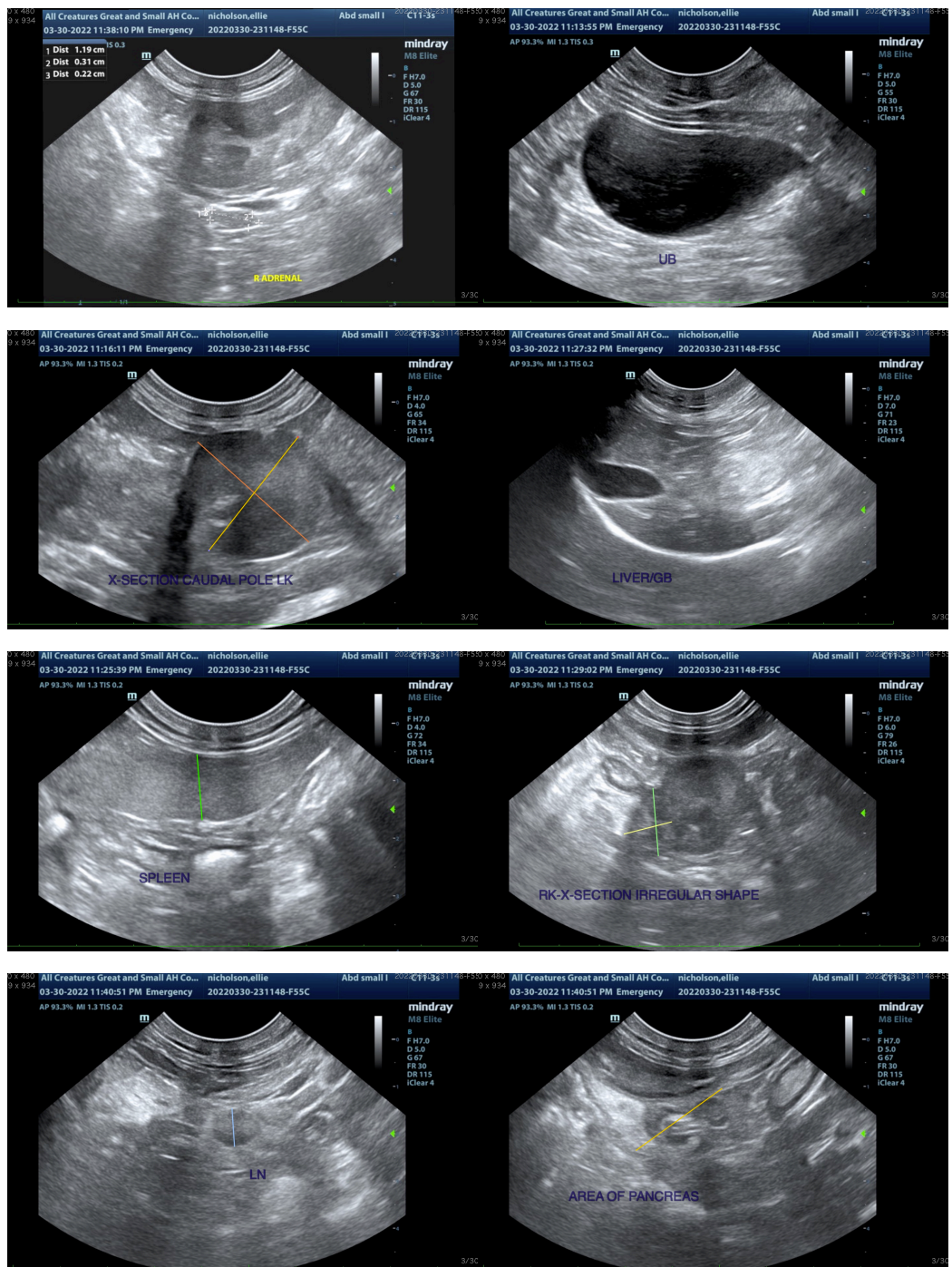
Dr. Chantal Litalien

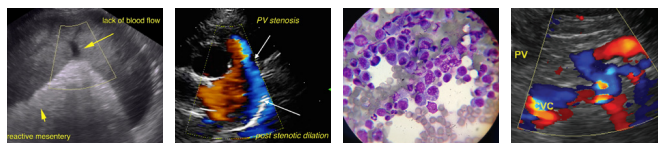
INVOICE

36617

DATE

3/31/22





PATIENT

Ellie Nicholson

The information and recommendations provided are based on the images presented by the referring veterinarian/sonographer. No evaluation can be communicated regarding pathology that was not visible in the image/video clips provided.

SPECIES

Feline

Thank you for this referral. If the clinical or image interpretation does not parallel your findings or if I can be of any further assistance please contact me.

Kathleen Sennello DVM,MS, Diplomate ACVIM (Small animal Internal Medicine)

BREED

Snowshoe X

kathleen.sennello@sonopath.com

SEX

Spayed Female

AGE

13 Years

WEIGHT

10.9 Pounds

INTERPRETED BY

Kathleen Sennello DVM,
MS, Diplomate ACVIM
(Small Animal Internal
Medicine)

**IMAGING
PERFORMED BY**

Jessica Bailes

HOSPITAL NAME

All Creatures Great &
Small Corvallis

REFERRING VET

Dr. Chantal Litalien

INVOICE

36617

DATE

3/31/22