# SonoPath
*Clinical Sonography & Telecytology*

EDUCATIONAL TELECONSULTATION SERVICES™

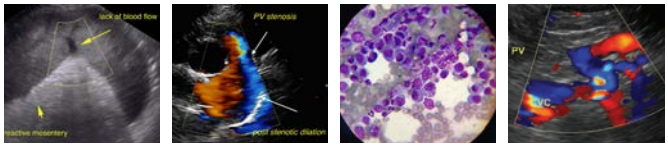

SonoPath.com™
1-800-838-4268 info@sonopath.com

**PATIENT**
Nash Novack

**SPECIES**
Canine

**BREED**
Mixed

**SEX**
Neutered Male

**AGE**
9 Months

**WEIGHT**
47.2 Pounds

**INTERPRETED BY**
Kathleen Sennello DVM, MS, Diplomate ACVIM (Small Animal Internal Medicine)

**IMAGING PERFORMED BY**
Diane McFadden

**HOSPITAL NAME**
AH of Roxbury

**REFERRING VET**
Dr. Elia

**INVOICE**
46300

**DATE**
3/30/23

## PRESENTING CLINICAL SIGNS

on/off vomiting since 3/3/23. 11/22-12/22 was giardia positive, treated with panacur and fortiflora. 1/27/23 fecal giardia positive again, with diarrhea. 3/27/23 vomiting and not eating. rad report wnl.

## ULTRASONOGRAPHIC EXAMINATION OF THE ABDOMEN

### *Urinary System*

The urinary bladder is moderately distended with mildly echogenic urine. The Bladder wall is diffusely mildly thickened (0.63 cm), and the mucosa is mildly irregular. The trigone, ureteral papillae, and visible urethra (to a depth of 2cm) appear normal with no evidence of severe mucosal irregularities, masses or cystic calculi. Findings are most consistent with bacterial cystitis or lack of urine distension. Recommend urinalysis and culture.

The prostate is normal in size (0.79 cm) and shape for this neutered male dog. The parenchyma is homogenous and the external margins are smooth. The prostatic urethra appears normal with no evidence of irregularity, invasion, mass effect or calculi.

The left kidney has a normal shape and size (5.51 cm). Overall echogenicity is normal with adequate corticomedullary distinction and a typical 1:3 cortex:medulla ratio. There is no evidence of focal perinephric inflammation or effusion. There is no evidence of pyelectasia, nephroliths, infarcts or hydroureter. Renal vasculature is normal.

The right kidney has a normal shape and size (5.6 cm). Overall echogenicity is normal with adequate corticomedullary distinction and a typical 1:3 cortex:medulla ratio. There is no evidence of focal perinephric inflammation or effusion. There is no evidence of pyelectasia, nephroliths, infarcts or hydroureter. Renal vasculature is normal.

### *Adrenal Glands*

The left adrenal gland is normal in size measuring 0.33 cm at the caudal pole. It is observed in its normal position cranial to the left renal artery. It is normal in appearance (uniformly hypoechoic) and shape with no evidence of a mass effect.

The right adrenal gland is normal in size measuring 0.34 cm at the caudal pole. It is observed in its normal position between the cranial aspect of the right kidney and the caudal vena cava. It is normal in appearance (uniformly hypoechoic) and shape with no evidence of a mass effect.

### *Spleen*

The spleen is subjectively normal in size, echotexture is homogenous, and the splenic capsule is smooth with no irregularities. The blood flow through the hilus and splenic parenchyma appears normal. No focal parenchymal abnormalities are visualized.

### *Liver*

The liver is subjectively normal in size, and echogenicity with smooth peripheral margins. The parenchyma is homogenous echotexture. The visible portions of the vasculature and biliary tract appear normal. No focal nodules or cystic lesions are observed.

The gallbladder lumen is moderately distended. The wall of the gall bladder is not thickened and has a smooth mucosal surface. Luminal contents are mild and primarily anechoic. The cystic and common bile ducts are normal/not visible.

### *Gastrointestinal*

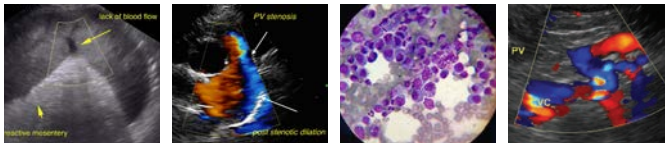

SonoPath.com™
1-800-838-4268 info@sonopath.com

**PATIENT**
Nash Novack

**SPECIES**
Canine

**BREED**
Mixed

**SEX**
Neutered Male

**AGE**
9 Months

**WEIGHT**
47.2 Pounds

**INTERPRETED BY**
Kathleen Sennello DVM, MS, Diplomate ACVIM (Small Animal Internal Medicine)

**IMAGING PERFORMED BY**
Diane McFadden

**HOSPITAL NAME**
AH of Roxbury

**REFERRING VET**
Dr. Elia

**INVOICE**
46300

**DATE**
3/30/23

The stomach contains minimal luminal contents. It measures at a normal thickness of <0.7cm with some variability due to the presence of rugal folds. The distinction of the gastric wall layers is adequate and there is no impression of reduced peristaltic activity. No masses or focal lesions were observed.

Most of the visualized areas of jejunum and ileum have a relatively uniform diameter with minimal fluid distension. Wall thickness is normal. Bowel loops follow a curvilinear path with distinct wall layering maintaining the typical 1:3 muscularis:mucosa layer ratio. Jejunum wall measures 0.36 cm. The duodenum appears somewhat prominent, with a thickened wall, measuring 0.53 cm. Wall layering is intact. There is a small amount of intraluminal fluid. Proximally, there is some mildly echogenic debris amongst the fluid, most consistent with ingesta, etc., but ingested foreign material cannot be ruled out. No evidence of obstruction is visualized.

The ileocecal junction was visualized and exhibited normal intact wall layering and is subjectively of normal thickness. Sections of colon are visualized with non-formed fecal material and gas shadowing distally. There is no observed focal or generalized colon wall thickening or loss of layering.

### *Pancreas*

The area of the pancreas is normal and isoechoic to surrounding mesentery. There is no evidence of nodules or cystic lesions. There is no evidence of regional mesenteric inflammation or fluid.

### *Free Abdomen*

Evaluation of the peritoneal cavity did not reveal any evidence of effusion. There are prominent mesenteric lymph nodes visualized measuring 0.86 cm and 1.1 cm. The omentum is of normal echogenicity.

## ULTRASONOGRAPHIC FINDINGS

- Thickened, mildly irregular urinary bladder with mildly echogenic urine – The bladder mucosal changes could be consistent with cystitis or artifactual due to lack of adequate luminal distension. Bladder neoplasia cannot be ruled out but is considered unlikely in this patient.

- Prominent, thickened duodenum with intraluminal fluid/debris – Findings could be consistent with inflammation (duodenitis), edema, less likely infiltration, as wall layering is intact.

## INTERPRETATION OF THE FINDINGS & FURTHER RECOMMENDATIONS

The duodenum appears prominent and mildly fluid distended on today's exam. These changes can be seen with inflammation of the duodenum, less likely edema, or infiltrative disease, as the bowel wall layering is intact and normal. Possible causes for duodenitis are similar to those in other areas of the small intestine, including GI parasitism, food allergy/dietary intolerance, pancreatitis, dysbiosis, ingested foreign material, and much less likely IBD or intestinal neoplasia in a patient this young. Consider:

- Consider a novel protein/hydrolyzed protein diet (exclusively at least 4-6 weeks)
- Consider a GI panel to Texas A&M for evaluation of B12 levels, folate, PLI/TLI etc.. to further evaluate for pancreatic/small intestinal disease.
- Recommend chronic probiotic therapy (if there has been no response to fortiflora, consider Proviable, etc.

If multiple courses of Metronidazole have bene administered, consider the possibility of dysbiosis and possibly fecal transplant.

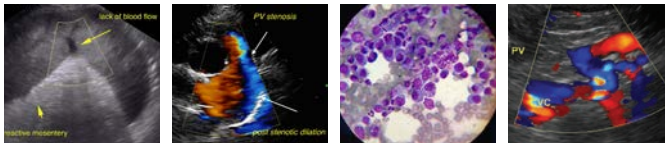

SonoPath.com™
1-800-838-4268 info@sonopath.com

**PATIENT**

Nash Novack

**SPECIES**

Canine

**BREED**

Mixed

**SEX**

Neutered Male

**AGE**

9 Months

**WEIGHT**

47.2 Pounds

**INTERPRETED BY**

Kathleen Sennello DVM, MS, Diplomate ACVIM (Small Animal Internal Medicine)

**IMAGING PERFORMED BY**

Diane McFadden

**HOSPITAL NAME**

AH of Roxbury

**REFERRING VET**

Dr. Elia

**INVOICE**

46300

**DATE**

3/30/23

In some of the images, there appears to be some mottled, slightly echogenic material mixed with the fluid. There is no evidence of an obstruction but could there possibly be non-shadowing foreign material(?). You could consider an upper GI endoscopy to further evaluate the esophagus, gastric lining, and duodenum, and obtain biopsies from these areas. Prior to this, you could consider an abbreviated barium swallow with serial radiographs to evaluate gastric emptying time and look for any luminal defects in the duodenum suggestive of foreign material, etc. Additionally, if symptoms persist, you could consider repeat imaging to see if there have been significant changes.

If not already done, this patient should have lab work performed to look for any metabolic causes of vomiting as well as a baseline cortisol to screen for Addison's.

The urinary bladder wall appears slightly irregular and thickened, and there is some mild echogenic debris visualized in the urinary bladder. Recommend a urinalysis and culture to screen for evidence of an infection.

Mesenteric lymph nodes are prominent. This is a common finding in young dogs and is likely incidental at this time. If lymph node enlargement progresses, consider a fine needle aspirate.

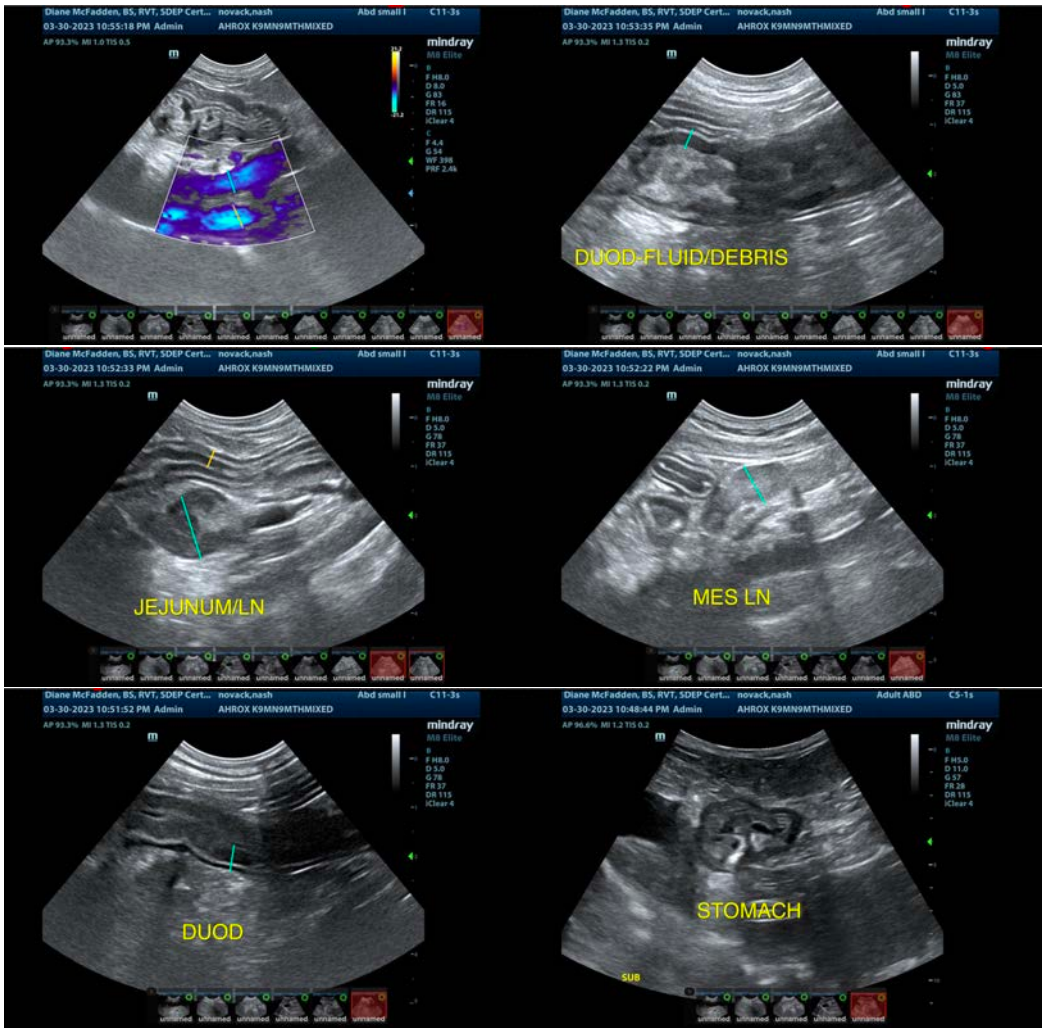

# SonoPath

*Clinical Sonography & Telecytology*

EDUCATIONAL TELECONSULTATION SERVICES™

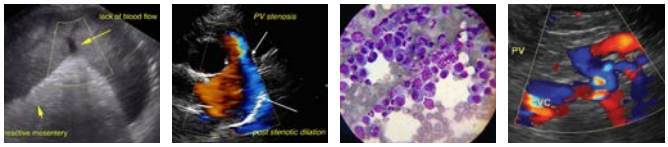

SonoPath.com™

1-800-838-4268 info@sonopath.com

**PATIENT**

Nash Novack

**SPECIES**

Canine

**BREED**

Mixed

**SEX**

Neutered Male

**AGE**

9 Months

**WEIGHT**

47.2 Pounds

**INTERPRETED BY**

Kathleen Sennello DVM, MS, Diplomate ACVIM (Small Animal Internal Medicine)

**IMAGING PERFORMED BY**

Diane McFadden

**HOSPITAL NAME**

AH of Roxbury

**REFERRING VET**

Dr. Elia

**INVOICE**

46300

**DATE**

3/30/23

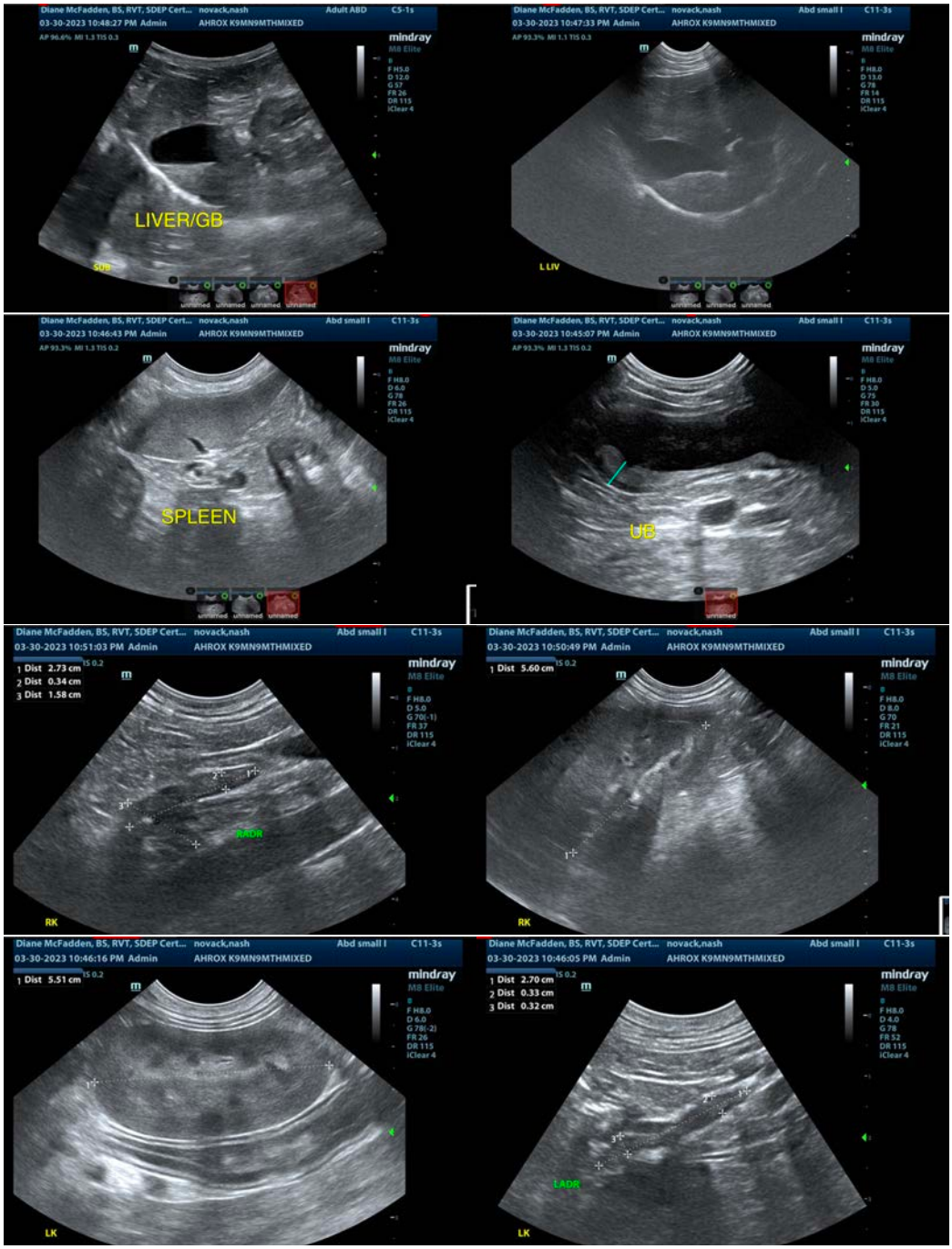


**The information and recommendations provided are based on the images presented by the referring veterinarian/sonographer. No evaluation can be communicated regarding pathology that was not visible in the image/video clips provided.**

Thank you for this referral. If the clinical or image interpretation does not parallel your findings or if I can be of any further assistance please contact me.

Kathleen Sennello DVM,MS, Diplomate ACVIM (Small animal Internal Medicine)

kathleen.sennello@sonopath.com