



PATIENT

Riley Freeland

SPECIES

Canine

BREED

Golden Retriever X

SEX

Spayed Female

AGE

8 Years

WEIGHT

31.7 Pounds

INTERPRETED BY

Kathleen Sennello DVM,
MS, Diplomate ACVIM
(Small Animal Internal
Medicine)

**IMAGING
PERFORMED BY**

Jessica Miller

HOSPITAL NAME

Millburn VH

REFERRING VET

Dr. Turowsky

INVOICE

36587

DATE

3/30/22

PRESENTING CLINICAL SIGNS

1-2 week hx of urinary accidents and straining, possible stones on rads (hard to tell c/ feces in colon)
Current meds: Clavamox and carprofen
Abnormal PE/Chem/CBC/UA Results: UA: 3+ protein, 50-75 WBCs, 50-74 RBCs, mod. cocci, 1+ struvite SG: 1.026

ULTRASONOGRAPHIC EXAMINATION OF THE ABDOMEN

Urinary System

The urinary bladder is moderately distended with slightly echogenic urine. The Bladder wall appears mildly irregular diffusely, and there is an accumulation of hyperechoic shadowing stones in the dependent portion of the urinary bladder (I would estimate 5-6 stones). An example of these stones measures approximately 1.0 cm in diameter. The area of the trigone, ureteral papillae and proximal urethra appear normal with no evidence of any mass effects or calculi.

The left kidney has a normal shape and size (5.49 cm). Overall echogenicity is normal with adequate corticomedullary distinction and a typical 1:3 cortex:medulla ratio. There is no evidence of perinephric inflammation or effusion. There is no evidence of pyelectasia, nephroliths, infarcts or hydroureter. Renal vasculature is normal.

The right kidney has a normal shape and size (5.8 cm). Overall echogenicity is normal with adequate corticomedullary distinction and a typical 1:3 cortex:medulla ratio. There is no evidence of perinephric inflammation or effusion. There is no evidence of pyelectasia, nephroliths, infarcts or hydroureter. Renal vasculature is normal.

Adrenal Glands

The left adrenal gland is normal in size measuring 0.58 cm at the caudal pole. It is observed in its normal position cranial to the left renal artery. It is normal in appearance (uniformly hypoechoic) and shape with no evidence of a mass effect.

The right adrenal gland is normal in size measuring 0.40 cm at the caudal pole. It is observed in its normal position between the cranial aspect of the right kidney and the caudal vena cava. It is normal in appearance (uniformly hypoechoic) and shape with no evidence of a mass effect.

Spleen

The spleen is subjectively normal in size, echotexture is homogenous, and the splenic capsule is smooth with no irregularities. The blood flow through the hilus and splenic parenchyma appears normal. No focal parenchymal abnormalities are visualized.

Liver

The liver is subjectively normal in size, and echogenicity with smooth peripheral margins. The parenchyma is homogenous echotexture. The visible portions of the vasculature and biliary tract appear normal. No focal nodules or cystic lesions are observed.

The gallbladder lumen is moderately distended. The wall of the gall bladder is not thickened and has a smooth mucosal surface. Luminal contents are primarily anechoic. The cystic and common bile ducts are normal/not visible.



PATIENT

Gastrointestinal

Riley Freeland

The stomach contains minimal luminal contents. It measures at a normal thickness of <0.7cm with some variability due to the presence of rugal folds. The distinction of the gastric wall layers is adequate and there is no impression of reduced peristaltic activity. No masses or focal lesions were observed.

SPECIES

Canine

The visualized areas of duodenum, jejunum and ileum have a relatively uniform diameter with minimal fluid distension. Wall thickness is normal. Bowel loops follow a curvilinear path with distinct wall layering maintaining the typical 1:3 muscularis:mucosa layer ratio. The duodenum measured as normal (between 0.3-0.5cm in wall thickness) and the jejunum measured as normal (between 0.2-0.47cm.)

BREED

Golden Retriever X

Visualized peristalsis appears appropriate. There were no focal lesions consistent with obstruction or a mass effect observed.

SEX

Spayed Female

The ileocecal junction was visualized and exhibited normal intact wall layering and is subjectively of normal thickness. Sections of colon are visualized with formed fecal material and gas shadowing distally. There is no observed focal or generalized colon wall thickening or loss of layering.

Pancreas

AGE

8 Years

The pancreas is normal and isoechoic to surrounding mesentery. There is no evidence of nodules or cystic lesions. There is no evidence of regional mesenteric inflammation or fluid.

Free Abdomen

WEIGHT

31.7 Pounds

Evaluation of the peritoneal cavity did not reveal any evidence of effusion, or subjective lymphadenomegaly. The Medial iliac nodes appear normal and there was no evidence of a caudal aortic thrombus at the bifurcation. The omentum is of normal uniform echogenicity.

ULTRASONOGRAPHIC FINDINGS

- Echogenic shadowing mineralizations within the dependent portion of the urinary bladder – most consistent with bladder stones and mild cystitis.

INTERPRETATION OF THE FINDINGS & FURTHER RECOMMENDATIONS

The most significant lesion on today's scan is the bladder stones evident within the urinary bladder. Recommend urinalysis and culture, and radiographs to confirm the size and number of stones present. I suspect cystotomy would be necessary, but depending on if there is an infection present and the size of the stones, other management techniques may be possible (medical dissolution, endoscopic retrieval, etc.).

INTERPRETED BY

Kathleen Sennello DVM,
MS, Diplomate ACVIM
(Small Animal Internal
Medicine)

IMAGING PERFORMED BY

Jessica Miller

HOSPITAL NAME

Millburn VH

REFERRING VET

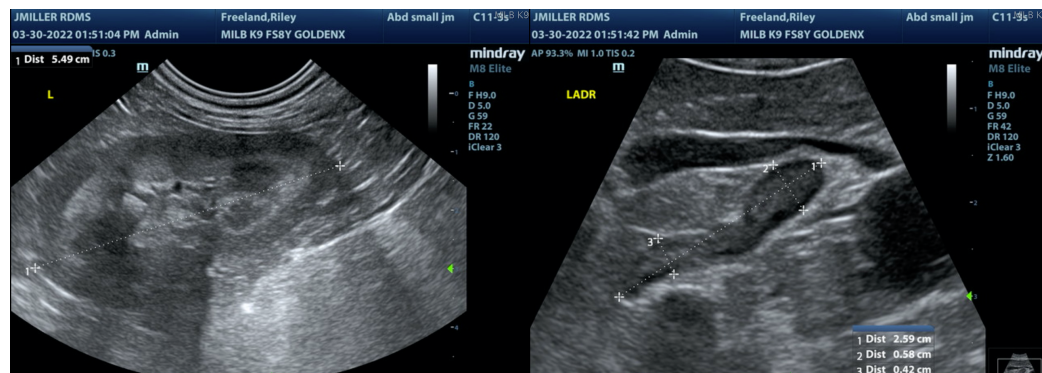
Dr. Turowsky

INVOICE

36587

DATE

3/30/22





PATIENT

Riley Freeland

SPECIES

Canine

BREED

Golden Retriever X

SEX

Spayed Female

AGE

8 Years

WEIGHT

31.7 Pounds

INTERPRETED BY

Kathleen Sennello DVM,
MS, Diplomate ACVIM
(Small Animal Internal
Medicine)

**IMAGING
PERFORMED BY**

Jessica Miller

HOSPITAL NAME

Millburn VH

REFERRING VET

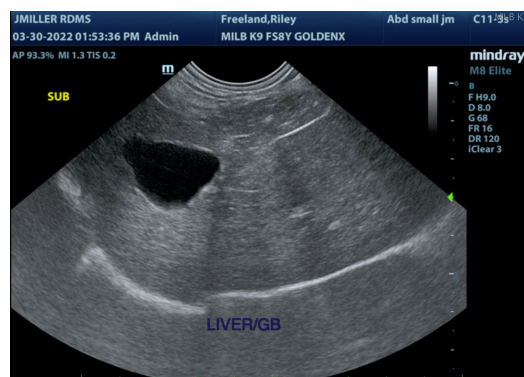
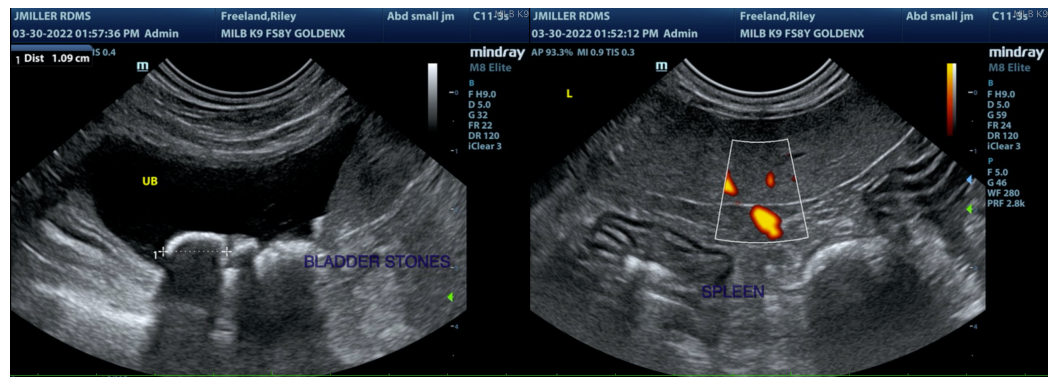
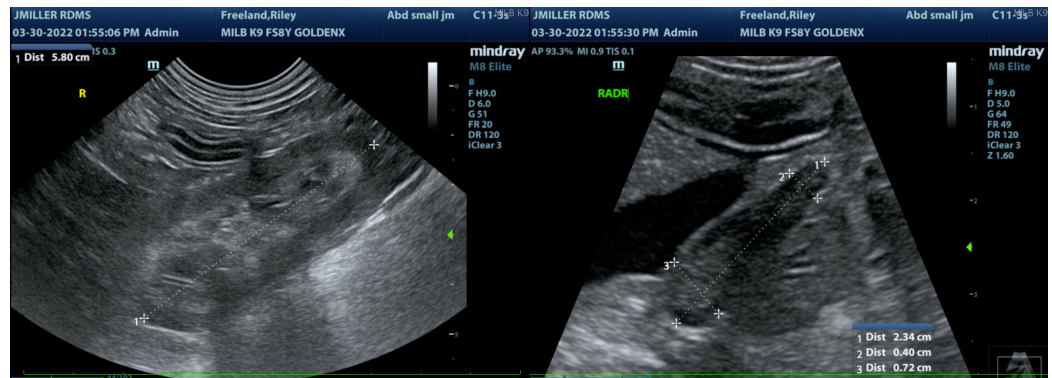
Dr. Turowsky

INVOICE

36587

DATE

3/30/22



The information and recommendations provided are based on the images presented by the referring veterinarian/sonographer. No evaluation can be communicated regarding pathology that was not visible in the image/video clips provided.

Thank you for this referral. If the clinical or image interpretation does not parallel your findings or if I can be of any further assistance please contact me.

Kathleen Sennello DVM,MS, Diplomate ACVIM (Small animal Internal Medicine)

kathleen.sennello@sonopath.com