

IMAGING PERFORMED BY

IntraPet.com



SonoPath

Clinical Sonography & Telecytology

EDUCATIONAL TELECONSULTATION SERVICES™

1-800-838-4268 info@sonopath.com SonoPath.com

DATE PRESENTING CLINICAL SIGNS

3/30/22

Presented 3/3 and again on 3/15 for vomiting. On carprofen chronically 4 mg/kg SID. On 3/3 workup was declined and treated with cerenia, and discontinuation of carprofen. Famotidine was instructed but never started OTC. O resumed carprofen. On 3/15: O reports cerenia improved vomiting but recurred. Concern for gastric/pyloric mass (alternately chronic gastric FB or ulcer?). Dystrophic mineralization and round structure at level of pylorus on rads. Bloodwork normal (chloride normal) except mild/stable elevation liver enzymes

PATIENT

Noel Mitchell

SPECIES

Canine

BREED

Boston Terrier

SEX

Spayed Female

AGE

10/24/08

WEIGHT

22.9 Pounds

INTERPRETED BY

Kathleen Sennello DVM,
MS, Diplomate ACVIM
(Small Animal Internal
Medicine)

IMAGING PERFORMED BY

Andi Parkinson RDMS

HOSPITAL NAME

Paradise AH

REFERRING VET

Dr. Riehl

INVOICE

36590

Current Medications: Famotidine 10mg SID, Sucralfate 0.5g BID, Cerenia 24mg SID.
Lab Results: ALT 149, ALP 397.
Date of Previous IntraPet Ultrasound: No previous.
Sedation: Not required to complete full diagnostic ultrasound.
Stat Report: Not requested.

ULTRASONOGRAPHIC EXAMINATION OF THE ABDOMEN

Urinary System

The urinary bladder is moderately distended with anechoic urine. The Bladder wall, trigone, ureteral papillae and visible urethra (to a depth of 2cm) appear normal with no evidence of wall thickening, mucosal irregularities, masses or cystic calculi.

The left kidney has a normal shape and size (4.81 cm) with pinpoint non-obstructive nephroliths. Overall echogenicity is normal with adequate corticomedullary distinction and a typical 1:3 cortex:medulla ratio. There is no evidence of perinephric inflammation or effusion. There is no evidence of pyelectasia, infarcts or hydroureter. Renal vasculature is normal.

The right kidney has a normal shape and size (4.38 cm) with pinpoint non-obstructive nephroliths. Overall echogenicity is normal with adequate corticomedullary distinction and a typical 1:3 cortex:medulla ratio. There is no evidence of perinephric inflammation or effusion. There is no evidence of pyelectasia, infarcts or hydroureter. Renal vasculature is normal.

Adrenal Glands

The left adrenal gland is normal in size measuring 0.57 cm at the caudal pole. It is observed in its normal position cranial to the left renal artery. It is normal in appearance (uniformly hypoechoic) and shape with no evidence of a mass effect.

The right adrenal gland is normal in size measuring 0.60 cm at the caudal pole. It is observed in its normal position between the cranial aspect of the right kidney and the caudal vena cava. It is normal in appearance (uniformly hypoechoic) and shape with no evidence of a mass effect.

Spleen

The spleen is subjectively normal in size, echotexture is homogenous, and the splenic capsule is smooth with no irregularities. The blood flow through the hilus and splenic parenchyma appears normal. No focal parenchymal abnormalities are visualized.

Liver

The liver is subjectively normal in size, and echogenicity with smooth peripheral margins. The parenchyma is homogenous echotexture. The visible portions of the vasculature and biliary tract appear normal. No focal nodules or cystic lesions are observed.

The gallbladder lumen is moderately distended. The wall of the gall bladder is not thickened and has a smooth mucosal surface. Luminal contents are primarily anechoic. The cystic and common bile ducts are normal/not visible.

Gastrointestinal

The stomach contains minimal luminal contents. It measures at a normal thickness of <0.7cm with some variability due to the presence of rugal folds. The distinction of the gastric wall layers is adequate and there is no impression of reduced peristaltic activity. No masses or focal lesions were observed.

The visualized areas of duodenum, jejunum and ileum have a uniform diameter with minimal fluid distension. Wall appears subjectively, mildly increased. Bowel loops follow a typical curvilinear path with distinct wall layering. Jejunum wall measured 0.37 cm. Duodenum wall measured 0.59 cm. There is rare mucosal speckling visualized. Visualized peristalsis appears appropriate. There were no focal lesions consistent with obstruction or a mass effect observed.

The ileocecal junction was visualized and exhibited normal intact wall layering and is subjectively of normal thickness. Sections of colon are visualized with formed fecal material and gas shadowing distally. There is no observed focal or generalized colon wall thickening or loss of layering.

Pancreas

The pancreas is prominent and mottled compared to the surrounding isoechoic mesentery. There is no evidence of nodules or cystic lesions. There is no evidence of regional mesenteric inflammation or fluid.

Free Abdomen

Evaluation of the peritoneal cavity did not reveal any evidence of effusion, or subjective lymphadenomegaly. The Medial iliac nodes appear normal and there was no evidence of a caudal aortic thrombus at the bifurcation. The omentum is of normal uniform echogenicity.

ULTRASONOGRAPHIC FINDINGS

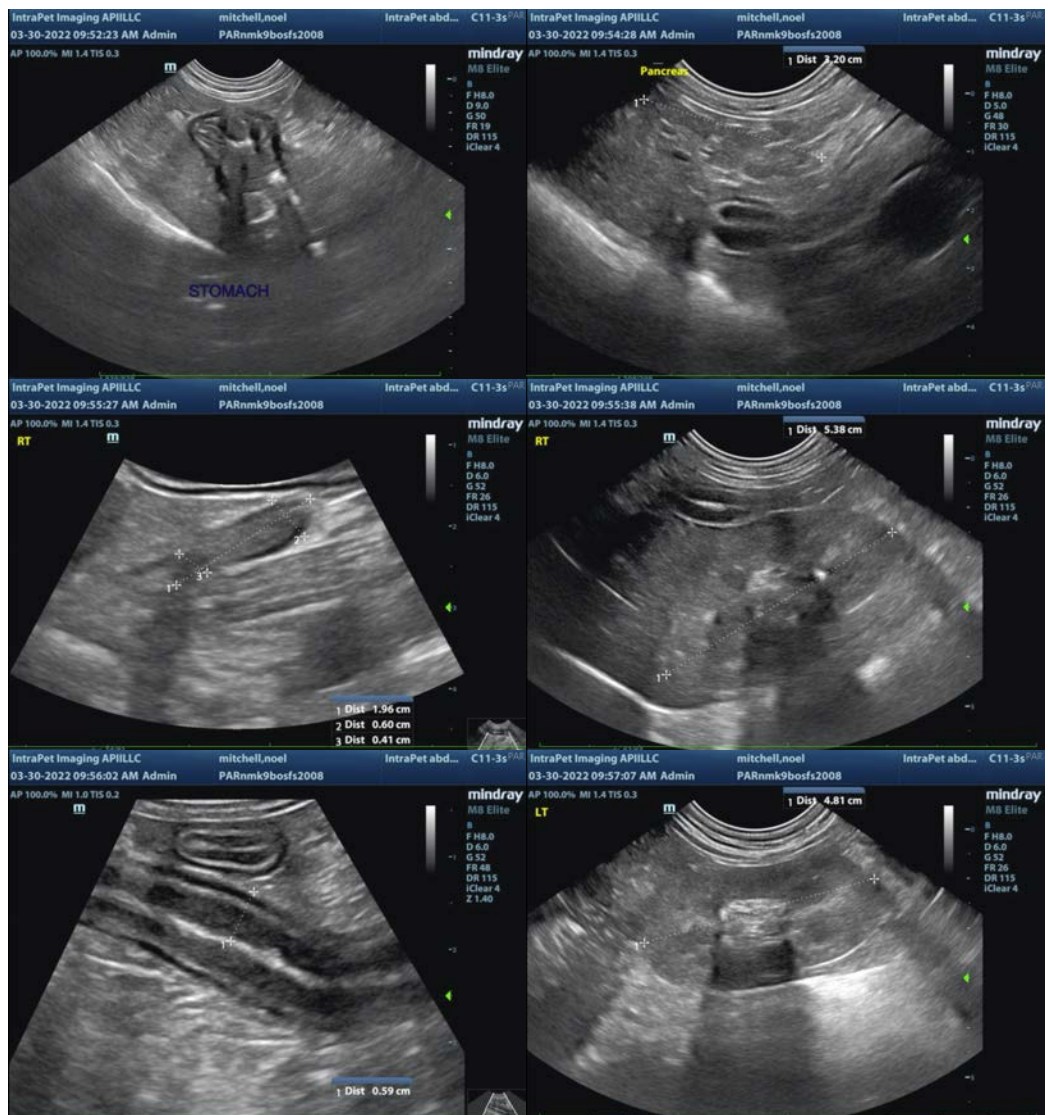
- Prominent, mottled pancreas – The pancreatic changes are most consistent with age-related parenchymal remodeling, potentially secondary to a prior inflammatory episode, early fibrosis or chronic pancreatitis.
- Occasional non-obstructive nephroliths visualized in the kidneys – The hyperechoic mineralized foci observed at the corticomedullary junction of the left/right kidney are consistent with small, non-obstructive nephroliths.
- Mild small intestinal thickening with occasional mucosal speckling – The mild small intestinal wall changes may be a normal variant in this patient or could be consistent with an inflammatory process (e.g., inflammatory bowel disease). Bright mucosal speckling has been proposed to represent dilated lacteals or focal accumulation of mucus, cellular debris etc.. in the mucosal crypts of the small intestine.

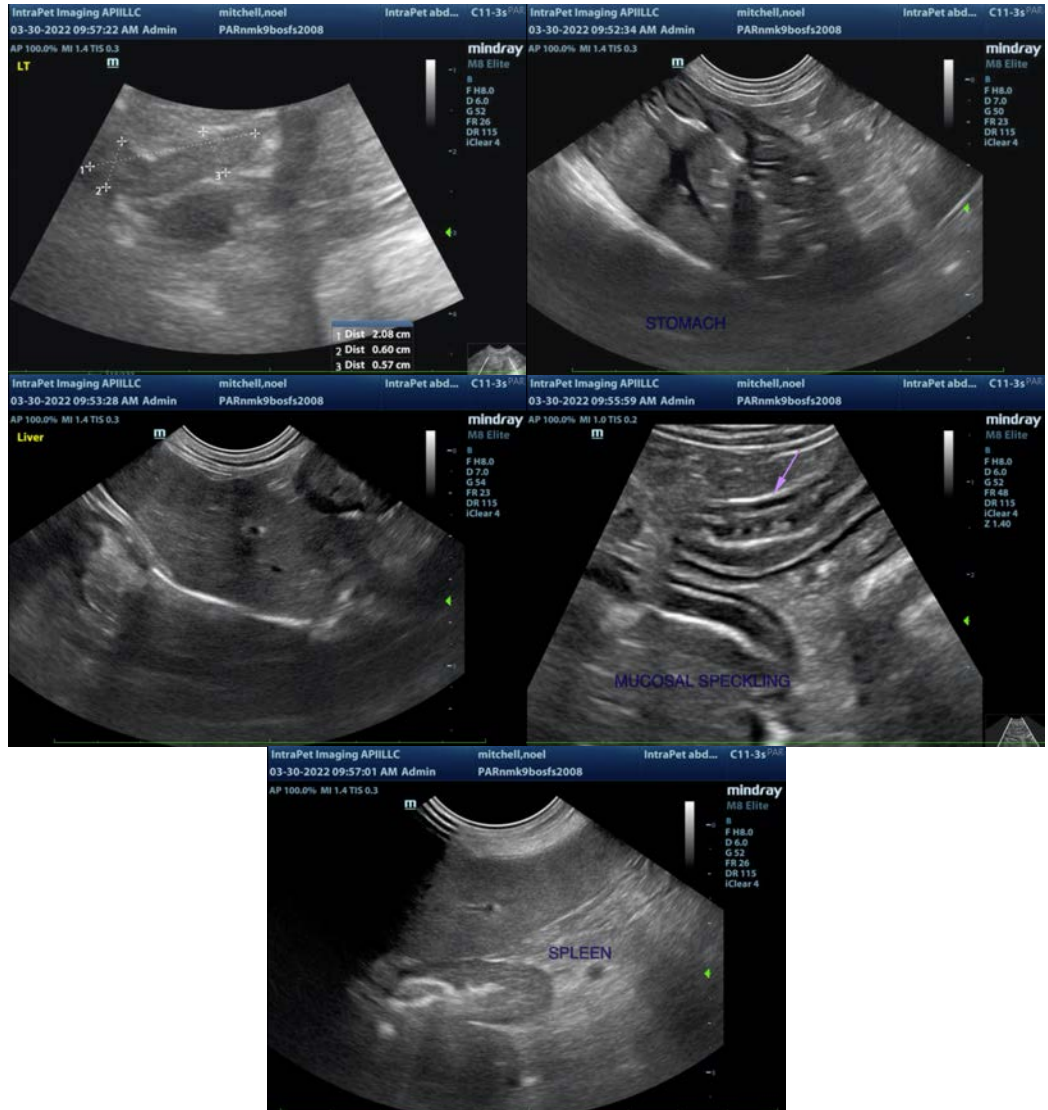
INTERPRETATION OF THE FINDINGS & FURTHER RECOMMENDATIONS

The lesions observed on today's scan were very mild and could be within normal limits for some older pets. Given the history of vomiting, the bowel changes could be significant. Consider possible metabolic causes for vomiting. A liver function test could be evaluated to ensure that the liver enzyme elevation is not significant. Additionally, a GI panel to Texas A&M for a qualitative PLI, TLI, cobalamin and folate could help to evaluate for pancreatitis, etc.

If metabolic causes of vomiting are thought unlikely, then consider primary GI causes such as dietary intolerance/food allergy, dietary indiscretion, pancreatitis, IBD, and less likely intestinal neoplasia.

- Consider a novel protein/hydrolyzed protein prescription diet.
- Consider chronic probiotic therapy.
- Recommend a GI panel to further evaluate the small intestine and pancreas (as recommended above).
- If vomiting persists, consider obtaining GI biopsies.
- Consider three view thoracic radiographs to rule out concurrent thoracic disease/involvement.





The information and recommendations provided are based on the images presented by the referring veterinarian/sonographer. No evaluation can be communicated regarding pathology that was not visible in the image/video clips provided.

Thank you for this referral. If the clinical or image interpretation does not parallel your findings or if I can be of any further assistance please contact me.

Kathleen Sennello DVM,MS, Diplomate ACVIM (Small animal Internal Medicine)
 kathleen.sennello@sonopath.com