



**PATIENT**

Tigger Randolph

**SPECIES**

Feline

**BREED**

DSH

**SEX**

Neutered Male

**AGE**

7 Years

**WEIGHT**

6.48 kg

**INTERPRETED BY**

Kathleen Sennello DVM,  
MS, Diplomate ACVIM  
(Small Animal Internal  
Medicine)

**IMAGING PERFORMED BY**

Dr. Tiffany Moore

**HOSPITAL NAME**

Lone Mountain AH

**REFERRING VET**

Dr. Tiffany Moore

**INVOICE**

46271

**DATE**

3/29/23

**PRESENTING CLINICAL SIGNS**

Presented for anorexia and vomiting. has a history of eating towels and plastic.

Abnormal PE/Chem/CBC/UA Results: CBC/Chem - elevated amylase, remaining BW WNL. UA blood +++ and protein +++, spg 1.056 Radiologic assessment: Considerations for the cardiac size include phase of cardiac cycle, and hypovolemia. Dilation of small intestinal loops, and plication can be seen with a linear foreign body obstruction. A linear foreign body obstruction is possible but not confirmed on this exam. Consider repeat abdominal radiographs to reevaluate the appearance of the small intestines. If findings are equivocal, abdominal ultrasound is recommended.

**ULTRASONOGRAPHIC EXAMINATION OF THE ABDOMEN**

**Urinary System**

The urinary bladder is moderately distended with mild primarily suspended echogenic debris present. The Bladder wall, trigone, ureteral papillae and visible urethra (to a depth of 2cm) appear normal with no evidence of wall thickening, mucosal irregularities, masses or calculi. Echogenic debris of this type can be associated with small crystals, cellular debris and proteinaceous debris.

The left kidney has a normal shape and size (3.69 cm). Overall echogenicity is normal with adequate corticomedullary distinction and a typical 1:3 cortex:medulla ratio. There is no evidence of focal perinephric inflammation or effusion. There is no evidence of pyelectasia, nephroliths, infarcts or hydroureter. Renal vasculature is normal.

The right kidney has a normal shape and size (4.39 cm). Overall echogenicity is normal with adequate corticomedullary distinction and a typical 1:3 cortex:medulla ratio. There is no evidence of focal perinephric inflammation or effusion. There is no evidence of pyelectasia, nephroliths, infarcts or hydroureter. Renal vasculature is normal.

**Adrenal Glands**

The region of left adrenal (Cranial to left renal artery) is unremarkable but the adrenal is not distinctly visualized. No evidence of a mass effect is visualized.

The region of the right adrenal (between right cranial kidney and vena cava) is unremarkable, but the adrenal is not distinctly visualized. No evidence of a mass effect is visualized.

**Spleen**

The spleen is subjectively normal in size (0.81 cm in width at the level of the hilus), echotexture is homogenous, and the splenic capsule is smooth with no irregularities. The blood flow through the hilus and splenic parenchyma appears normal. There are occasional very ill-defined hyperechoic nodules, one such nodule measures 0.36 cm.

**Liver**

The liver is subjectively normal in size, and echogenicity with smooth peripheral margins. The parenchyma is homogenous echotexture. The visible portions of the vasculature and biliary tract appear normal. No focal nodules or cystic lesions are observed.

The gallbladder lumen is moderately distended. The wall of the gall bladder is not thickened and has a smooth mucosal surface. Luminal contents are mild and primarily anechoic. The cystic and common bile ducts are normal/not visible.



**PATIENT**

Tigger Randolph

**SPECIES**

Feline

**BREED**

DSH

**SEX**

Neutered Male

**AGE**

7 Years

**WEIGHT**

6.48 kg

**INTERPRETED BY**

Kathleen Sennello DVM,  
MS, Diplomate ACVIM  
(Small Animal Internal  
Medicine)

**IMAGING PERFORMED BY**

Dr. Tiffany Moore

**HOSPITAL NAME**

Lone Mountain AH

**REFERRING VET**

Dr. Tiffany Moore

**INVOICE**

46271

**DATE**

3/29/23

**Gastrointestinal**

The stomach contains a moderate to large amount of fluid and gas. It measures at a normal thickness of <0.36cm with some variability due to the presence of rugal folds. The distinction of the gastric wall layers is adequate and there is no impression of reduced peristaltic activity. No masses or focal lesions were observed.

Some of the visualized areas of duodenum, jejunum and ileum have a relatively uniform diameter with minimal fluid distension, but many other areas have significant fluid distention with evidence of non-progressive motility. Some focal areas have severe wall thickening and some loss of wall layering with wall thickness measurements up to 0.82 cm. The more normal fluid dilated sections of bowel measure at 0.22 cm. The focal areas of thickening are concerning for infiltrative disease and are surrounded by hyperechoic mesentery.

The ileocecal junction was visualized and exhibited normal intact wall layering and is subjectively of normal thickness. Sections of colon are visualized with formed fecal material and gas shadowing distally. There is no observed focal or generalized colon wall thickening or loss of layering.

**Pancreas**

The pancreas is normal and isoechoic to surrounding mesentery. There is no evidence of nodules or cystic lesions. There is no evidence of regional mesenteric inflammation or fluid.

**Free Abdomen**

Scant free fluid is present. There is a significant lymphadenopathy with large hypoechoic lymph nodes and clusters around abnormal bowel loops. Examples of these lymph nodes measure 1.02 cm and 0.92 cm. The omentum is hyperechoic around the lymph nodes and abnormal bowel.

**ULTRASONOGRAPHIC FINDINGS**

- Fluid distention of the stomach and small bowel with increased non-progressive motility – findings are concerning for a partial obstructive process, ileus, and/or delayed gastric emptying.
- Focal areas of small bowel with severe wall thickening and reduced detail of wall layering – findings are concerning for possible infiltrative disease. The most likely differential would be round cell neoplasia, less likely IBD or other.
- Moderate mesenteric lymphadenopathy – The moderate mesenteric lymphadenopathy could be concerning for a neoplastic process, although you can see significant lymphadenopathy in some cases of autoimmune/inflammatory disease, infectious disease (tick born disease-such as bartonella, fungal infections, FIP (cats)) etc. A fine needle aspirate with cytology is recommended for further evaluation.

**INTERPRETATION OF THE FINDINGS & FURTHER RECOMMENDATIONS**

There is the general appearance of fluid distended hypermotile bowel with a lack of progressive motility. No focal point of obstruction is visualized, but there are several areas of small bowel that have significant thickening of the wall and decreased wall layering, concerning for possible infiltrative disease. Additionally, there are large hypoechoic lymph nodes in this region and a significant amount of inflammation. Options moving forward include a fine needle aspirate of a mesenteric lymph node for cytology +/- aspiration of a thickened area of bowel wall. If a cytologic diagnosis is not possible, then consider surgical biopsies. A foreign body obstruction cannot be definitively ruled out with severe enteritis, but my primary concern is underlying neoplasia.



**PATIENT**

Tigger Randolph

Recommend three view thoracic radiographs to evaluate for possible concurrent thoracic disease/involvement.

**SPECIES**

Feline

**BREED**

DSH

**SEX**

Neutered Male

**AGE**

7 Years

**WEIGHT**

6.48 kg

**INTERPRETED BY**

Kathleen Sennello DVM,  
MS, Diplomate ACVIM  
(Small Animal Internal  
Medicine)

**IMAGING PERFORMED BY**

Dr. Tiffany Moore

**HOSPITAL NAME**

Lone Mountain AH

**REFERRING VET**

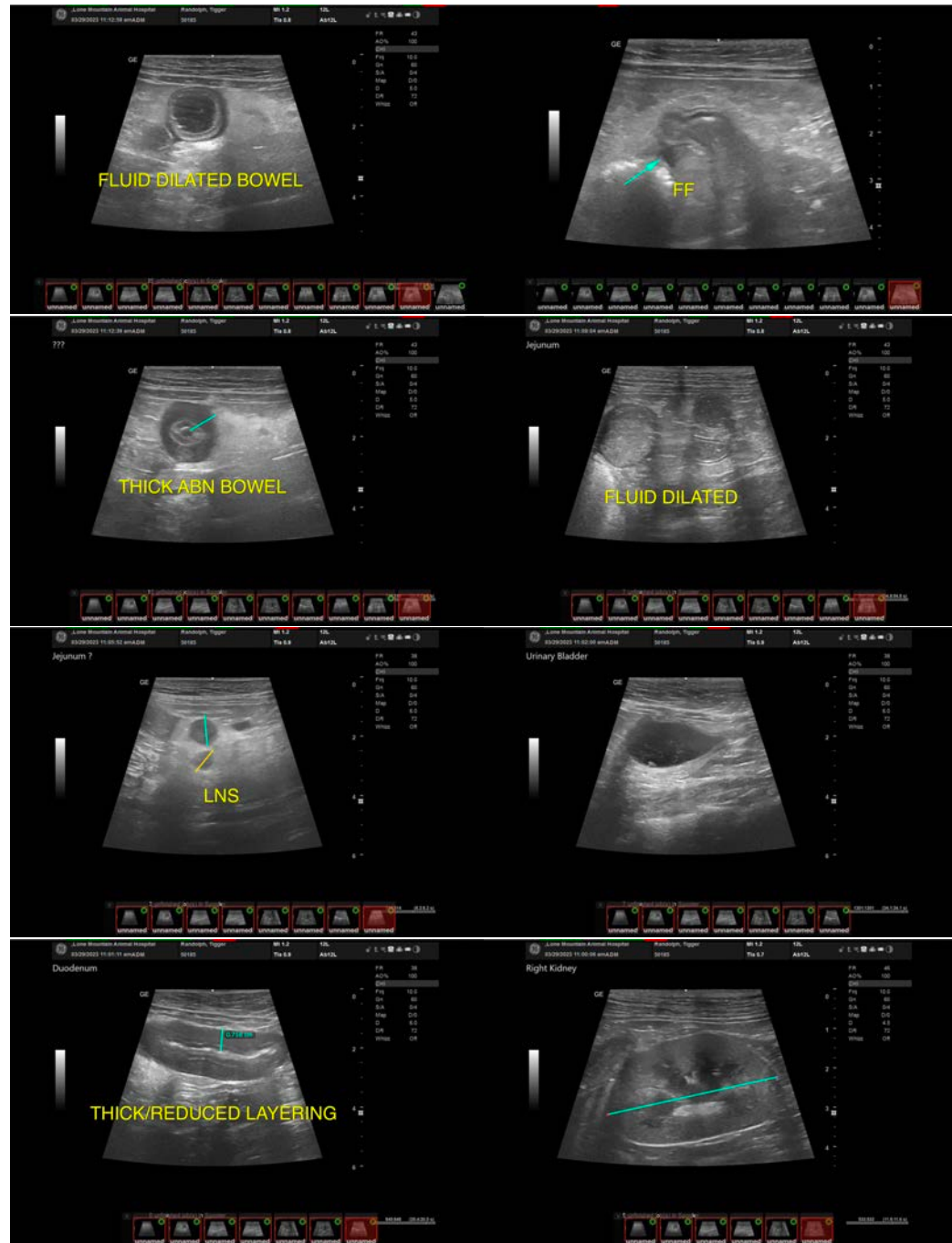
Dr. Tiffany Moore

**INVOICE**

46271

**DATE**

3/29/23





**PATIENT**

Tigger Randolph

**SPECIES**

Feline

**BREED**

DSH

**SEX**

Neutered Male

**AGE**

7 Years

**WEIGHT**

6.48 kg

**INTERPRETED BY**

Kathleen Sennello DVM,  
MS, Diplomate ACVIM  
(Small Animal Internal  
Medicine)

**IMAGING PERFORMED BY**

Dr. Tiffany Moore

**HOSPITAL NAME**

Lone Mountain AH

**REFERRING VET**

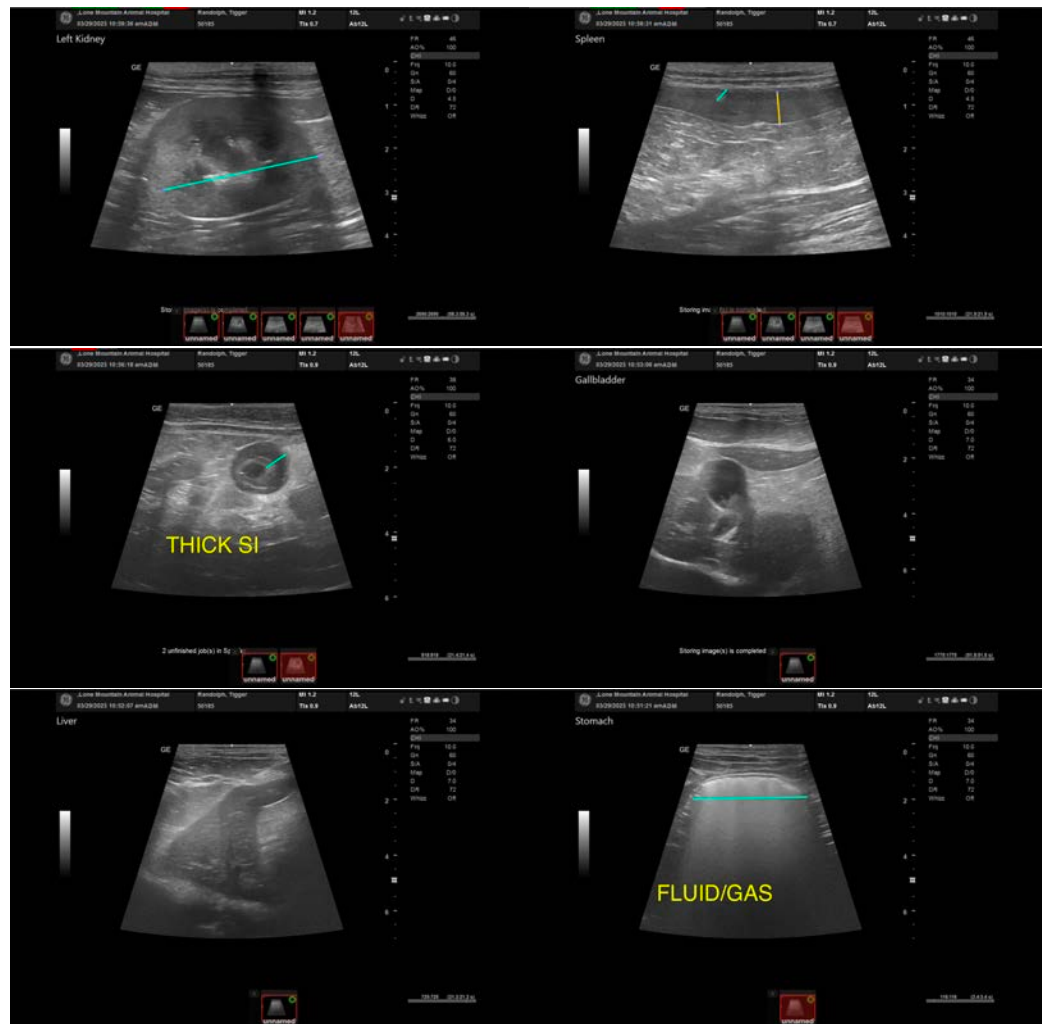
Dr. Tiffany Moore

**INVOICE**

46271

**DATE**

3/29/23



The information and recommendations provided are based on the images presented by the referring veterinarian/sonographer. No evaluation can be communicated regarding pathology that was not visible in the image/video clips provided.

Thank you for this referral. If the clinical or image interpretation does not parallel your findings or if I can be of any further assistance please contact me.

Kathleen Sennello DVM,MS, Diplomate ACVIM (Small animal Internal Medicine)

kathleen.sennello@sonopath.com