



PATIENT

Sugar Sleaze

SPECIES

Canine

BREED

Shih Tzu

SEX

Spayed Female

AGE

6 Years

WEIGHT

4.75 kg

INTERPRETED BY

Kathleen Sennello DVM,
MS, Diplomate ACVIM
(Small Animal Internal
Medicine)

IMAGING PERFORMED BY

Dr. Schwanebeck

HOSPITAL NAME

Animal Emergency
Hospital Deland

REFERRING VET

Dr. Schwanebeck

INVOICE

46211

DATE

3/29/23

PRESENTING CLINICAL SIGNS

Patient presented as transfer for inability to urinate, congestion, and anemia. Owner also concerned about patient not eating. Hc heart murmur

Abnormal PE/Chem/CBC/UA Results: BW performed at rDVM Chem: Phosphorous 7.6, ALT not read, ALP 809 CBC: 20.4% HCT, 59 WBC T4: <0.5 Radiographs: Slightly enlarged cardiac silhouette.

ULTRASONOGRAPHIC EXAMINATION OF THE ABDOMEN

Urinary System

The urinary bladder is moderately distended with anechoic urine. The Bladder wall, trigone, ureteral papillae and visible urethra (to a depth of 2cm) appear normal with no evidence of wall thickening, mucosal irregularities, or masses. There are rare small hyperechoic foci visualized in the dependent portion of the urinary bladder, consistent with very small (approximately 1-2 mm) mineralizations.

The left kidney has a normal shape and size (4.35 cm). Overall echogenicity is normal with adequate corticomedullary distinction and a typical 1:3 cortex:medulla ratio. There is no evidence of focal perinephric inflammation or effusion. There is no evidence of pyelectasia, nephroliths, infarcts or hydroureter. Renal vasculature is normal.

The right kidney has a normal shape and size (4.76 cm). Overall echogenicity is normal with adequate corticomedullary distinction and a typical 1:3 cortex:medulla ratio. There is no evidence of focal perinephric inflammation or effusion. There is no evidence of pyelectasia, nephroliths, infarcts or hydroureter. Renal vasculature is normal.

Adrenal Glands

The left adrenal gland is normal in size measuring 0.52 cm at the caudal pole. It is observed in its normal position cranial to the left renal artery. It is normal in appearance (uniformly hypoechoic) and shape with no evidence of a mass effect.

The right adrenal gland is normal in size measuring 0.49 cm at the caudal pole. It is observed in its normal position between the cranial aspect of the right kidney and the caudal vena cava. It is normal in appearance (uniformly hypoechoic) and shape with no evidence of a mass effect.

Spleen

The spleen is subjectively normal in size but slightly irregular in shape. The spleen echotexture is heterogenous and mildly mottled. The blood flow through the hilus and splenic parenchyma appears normal. A region of the spleen near the head close to the stomach appears slightly irregular with isoechoic parenchyma. I suspect this is anatomic variation but a mass effect cannot be definitively ruled out.

Liver

The liver is subjectively normal in size with smooth peripheral margins. The parenchyma is hyperechoic and homogenous in echotexture. The visible portions of the vasculature and biliary tract appear normal. No focal nodules or cystic lesions are observed.

The gallbladder lumen is moderately distended. The wall of the gall bladder is not thickened and has a smooth mucosal surface. Luminal contents are mild and primarily anechoic. The cystic and common bile ducts are normal/not visible.



PATIENT

Gastrointestinal

Sugar Slease

The stomach contains a large amount of fluid. It measures at a normal thickness of <0.7cm with some variability due to the presence of rugal folds. The distinction of the gastric wall layers is adequate and there is no impression of reduced peristaltic activity. No masses or focal lesions were observed.

SPECIES

Canine

The visualized areas of duodenum, jejunum and ileum have a relatively uniform diameter with minimal fluid distension. Wall thickness is normal. Bowel loops follow a curvilinear path with distinct wall layering maintaining the typical 1:3 muscularis:mucosa layer ratio. Duodenum wall measures 0.54 cm. Jejunum wall measures 0.37 cm. Visualized peristalsis appears appropriate. There were no focal lesions consistent with obstruction or a mass effect observed.

BREED

Shih Tzu

SEX

Spayed Female

The ileocecal junction was visualized and exhibited normal intact wall layering and is subjectively of normal thickness. Sections of colon are visualized with formed fecal material and gas shadowing distally. There is no observed focal or generalized colon wall thickening or loss of layering.

AGE

6 Years

Pancreas

The pancreas is normal and isoechoic to surrounding mesentery. There is no evidence of nodules or cystic lesions. There is no evidence of regional mesenteric inflammation or fluid.

WEIGHT

4.75 kg

Free Abdomen

Evaluation of the peritoneal cavity did not reveal any evidence of effusion, or subjective lymphadenomegaly. The Medial iliac nodes appear normal and there was no evidence of a caudal aortic thrombus at the bifurcation. The omentum is of normal uniform echogenicity.

INTERPRETED BY

Kathleen Sennello DVM,
MS, Diplomate ACVIM
(Small Animal Internal
Medicine)

ULTRASONOGRAPHIC FINDINGS

- Pinpoint mineralizations in the urinary bladder – This sandy debris is small enough to pass. Recommend urinalysis and culture.
- Mildly mottled, slightly irregular head of the spleen – The diffuse splenic changes are non-specific and could be consistent with lymphoid hyperplasia, extramedullary hematopoiesis, infiltrative neoplasia, inflammation, other. Cytology or histopathology would be necessary to get a definitive diagnosis. The mottling described is very subtle and could be within normal limits for this individual. Additionally, the irregularity at the head of the spleen is likely normal anatomic variation, but continued monitoring is warranted.
- Hyperechoic liver – The diffuse hepatic changes are non-specific and can be seen with vacuolar hepatopathy, reactive change, nodular hyperplasia or, less likely, inflammatory/immune-mediated disease, infiltrative neoplasia, or other hepatopathy.
- Large fluid distention of the stomach – Correlate with feeding/drinking history and abdominal radiographs. If the patient was adequately fasted, then consider the possibility of delayed gastric emptying. No evidence of an obstruction was visualized at the outflow tract.

IMAGING PERFORMED BY

Dr. Schwanebeck

HOSPITAL NAME

Animal Emergency
Hospital Deland

REFERRING VET

Dr. Schwanebeck

INVOICE

46211

DATE

3/29/23

INTERPRETATION OF THE FINDINGS & FURTHER RECOMMENDATIONS

No obvious lesions are visualized on today's exam to explain the anemia and inability to urinate described.

The urinary bladder has very small mineralizations, and the outflow tract to the first 2+ cm of urethra was visualized, and no mass effects or significant calculi are observed. If this patient truly cannot urinate, consider a possible neurologic cause.



PATIENT

Sugar Slease

There is no evidence of free fluid or hemorrhage to explain the anemia reported. The spleen appears slightly irregular and mildly mottled. Given the anemia reported, consider a fine needle aspirate, although I suspect this could be within normal limits for this individual,

SPECIES

Canine

The significance of the hyperechoic liver is uncertain. This could be consistent with a vacuolar hepatopathy, lymphoma, etc. If primary hepatic disease is suspected, you could consider a fine needle aspirate of the liver (provided coagulation parameters are normal) in addition to pre- and post-prandial bile acids to evaluate liver function.

BREED

Shih Tzu

There is a significance amount of fluid visualized within the stomach. Correlate with feeding and drinking history. I suspect this could some mild delayed gastric emptying. Recommend continued monitoring.

SEX

Spayed Female

Consider a pathologist review of a blood smear, looking for evidence of regeneration, atypical cells and spherocytes, etc., is the albumin normal(?), looking for evidence of hemorrhage. Recommend a rectal exam, looking for possible melena. If there is no evidence of regeneration, consider the possibility of underlying bone marrow disease or an anemia of chronic disease. Additionally, there is a possibility of autoimmune disease, which hopefully your pathologist review will help to better determine.

AGE

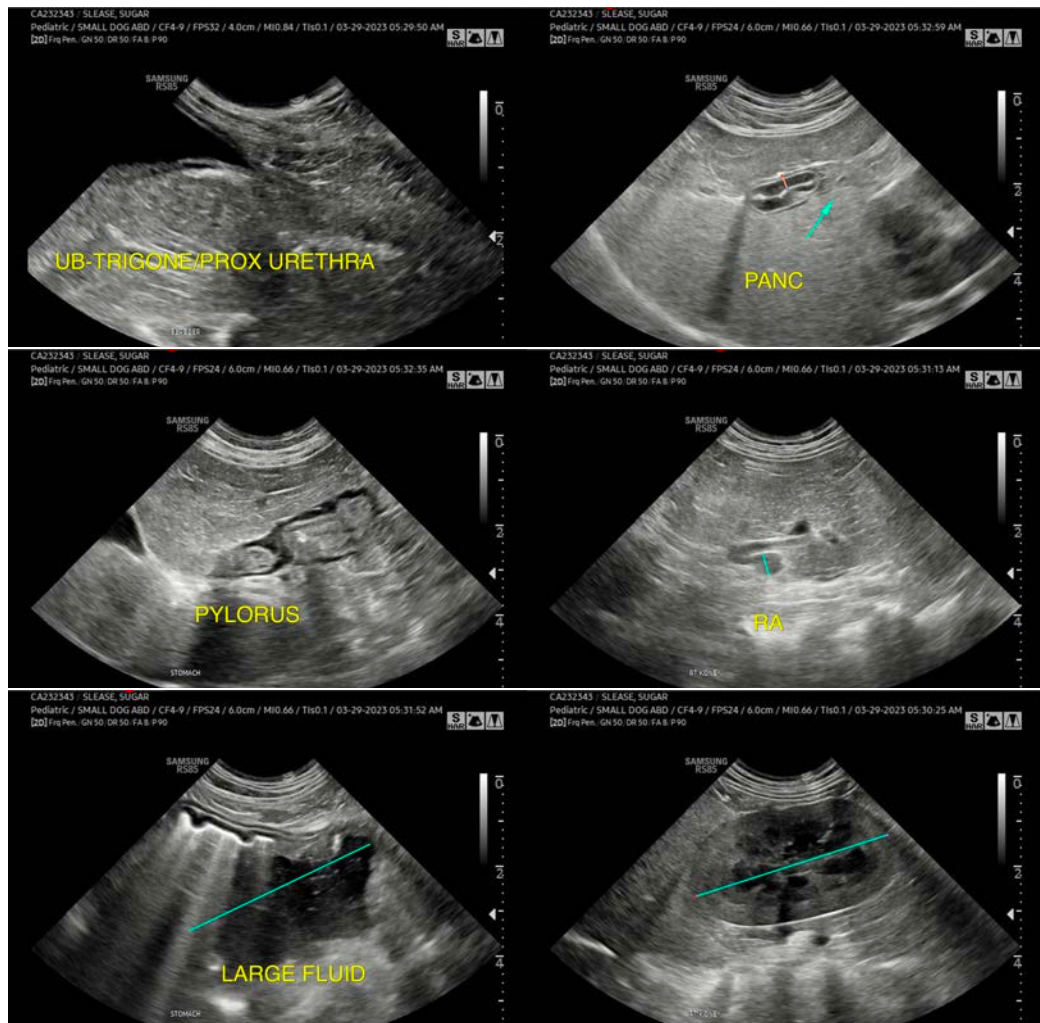
6 Years

WEIGHT

4.75 kg

INTERPRETED BY

Kathleen Sennello DVM, MS, Diplomate ACVIM (Small Animal Internal Medicine)



IMAGING PERFORMED BY

Dr. Schwanebeck

HOSPITAL NAME

Animal Emergency Hospital Deland

REFERRING VET

Dr. Schwanebeck

INVOICE

46211

DATE

3/29/23



PATIENT

Sugar Slease

SPECIES

Canine

BREED

Shih Tzu

SEX

Spayed Female

AGE

6 Years

WEIGHT

4.75 kg

INTERPRETED BY

Kathleen Sennello DVM,
MS, Diplomate ACVIM
(Small Animal Internal
Medicine)

**IMAGING
PERFORMED BY**

Dr. Schwanebeck

HOSPITAL NAME

Animal Emergency
Hospital Deland

REFERRING VET

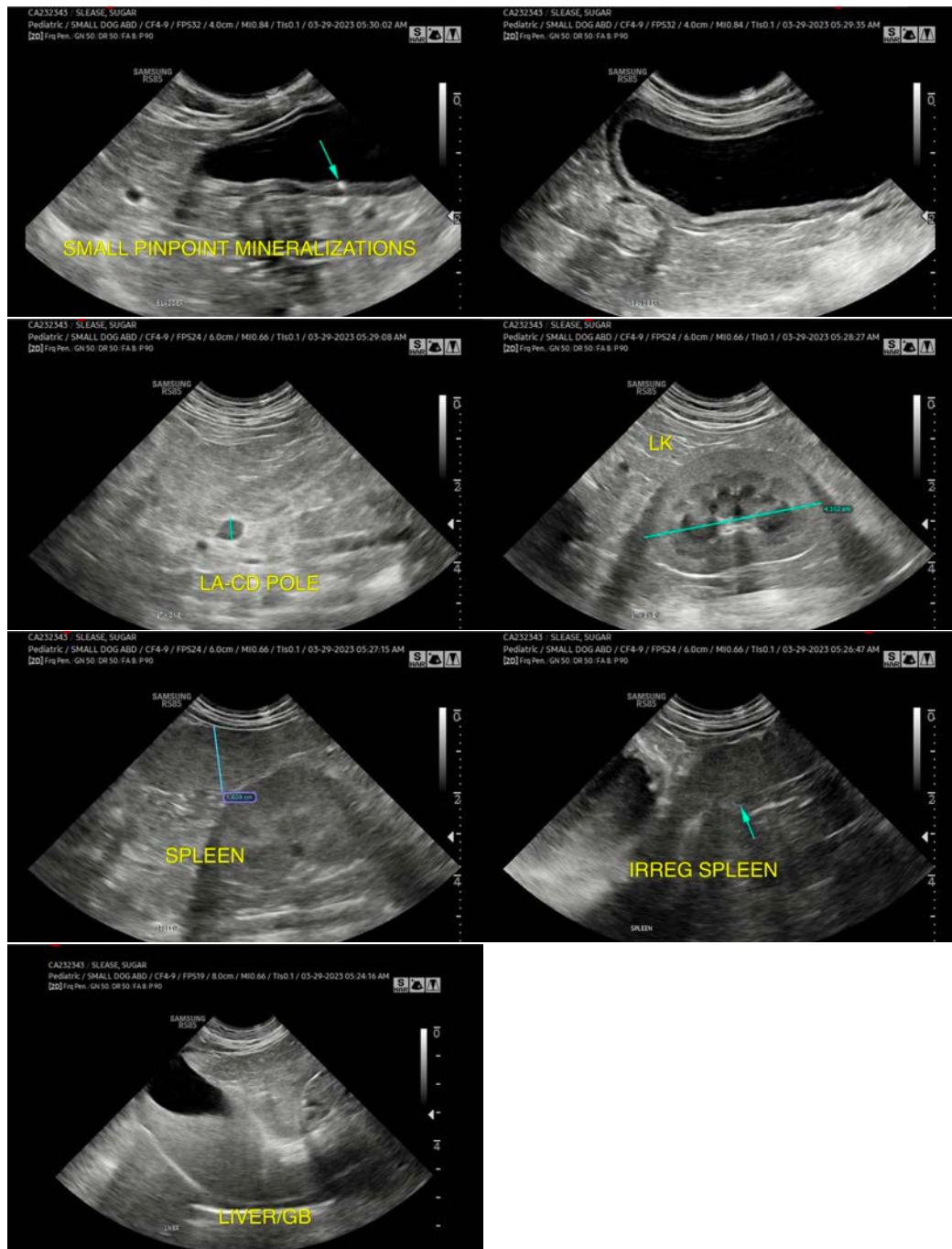
Dr. Schwanebeck

INVOICE

46211

DATE

3/29/23



The information and recommendations provided are based on the images presented by the referring veterinarian/sonographer. No evaluation can be communicated regarding pathology that was not visible in the image/video clips provided.

Thank you for this referral. If the clinical or image interpretation does not parallel your findings or if I can be of any further assistance please contact me.

Kathleen Sennello DVM,MS, Diplomate ACVIM (Small animal Internal Medicine)

kathleen.sennello@sonopath.com