

**PATIENT PRESENTING CLINICAL SIGNS**

Saffron Bleier

**SPECIES**

Canine

**BREED**

Fox Wire Terrier

**SEX**

Spayed Female

**AGE**

12y10m

**WEIGHT**

10kg

**INTERPRETED BY**

Kathleen Sennello DVM,  
MS, Diplomate ACVIM  
(Small Animal Internal  
Medicine)

**IMAGING PERFORMED BY**

Loetitia Saint-Jacques,  
LVT

**HOSPITAL NAME**

Pine Creek Veterinary  
Clinic

**REFERRING VET**

Catherine Rebholtz,  
DVM

**INVOICE**

10155

**DATE**

3/29/2023

History \* Not eating much since Thursday and has to be coaxed. P urinated in her sleep on Thursday night. No pu/pd. Drinking water normal but seen less energetic but not lethargic. No medications. But on prevention and probiotics to increase appetite without success. Tiny success with cerenia. Appetite is declining daily. Only will eat hotdog and deli meat when being coaxed, but no other food. 1/2 cup bid with 1/5 can BID on her normal eating. Lost control of bladder once. Owners do note head tilt at home is new, patient does seem lost sometimes and patient shakes more than she used to. Working diagnosis R/o cancer, pancreatitis. Also has neurologic signs. Waiting on rad report for chest and abdomen- attached abdominal rads as supplemental use.

Abnormal PE/Chem/CBC/UA Results: elevated alkaline phosphatase and a slightly low urine concentration. Medication - Cerenia 24mg q24hr. Fortiflora q24hr. Starting Entyce 30mg q24hr today.

**ULTRASONOGRAPHIC EXAMINATION OF THE ABDOMEN**

**Urinary System**

The urinary bladder is moderately distended with anechoic urine. The Bladder wall, trigone, ureteral papillae, and visible urethra (to a depth of 2cm) appear normal with no evidence of wall thickening, mucosal irregularities, masses, or cystic calculi.

The left kidney has a normal shape and size (4.06 cm). Overall echogenicity is normal with adequate corticomedullary distinction and a typical 1:3 cortex: medulla ratio. There is no evidence of focal perinephric inflammation or effusion. There is no evidence of pyelectasia, nephroliths, infarcts or hydroureter. Renal vasculature is normal.

The right kidney has a normal shape and size (5.48 cm). Overall echogenicity is normal with adequate corticomedullary distinction and a typical 1:3 cortex: medulla ratio. There is no evidence of focal perinephric inflammation or effusion. There is no evidence of pyelectasia, nephroliths, infarcts or hydroureter. Renal vasculature is normal.

**Adrenal Glands**

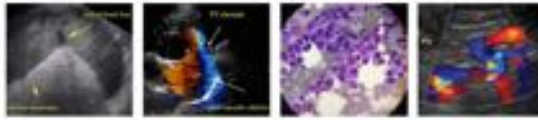
The left adrenal gland is normal in size measuring 0.61 cm at the caudal pole. It is observed in its normal position cranial to the left renal artery. It is normal in appearance (uniformly hypoechoic) and shape with no evidence of a mass effect.

The right adrenal gland is normal in size measuring 0.50 cm at the caudal pole. It is observed in its normal position between the cranial aspect of the right kidney and the caudal vena cava. It is normal in appearance (uniformly hypoechoic) and shape with no evidence of a mass effect.

**Spleen**

The spleen is subjectively normal in size, echotexture is homogenous, and the splenic capsule is smooth with no irregularities. The blood flow through the hilus and splenic parenchyma appears normal. No focal parenchymal abnormalities are visualized.

**Liver**



**PATIENT**

Saffron Bleier

**SPECIES**

Canine

**BREED**

Fox Wire Terrier

**SEX**

Spayed Female

**AGE**

12y10m

**WEIGHT**

10kg

**INTERPRETED BY**

Kathleen Sennello DVM,  
MS, Diplomate ACVIM  
(Small Animal Internal  
Medicine)

**IMAGING  
PERFORMED BY**

Loetitia Saint-Jacques,  
LVT

**HOSPITAL NAME**

Pine Creek Veterinary  
Clinic

**REFERRING VET**

Catherine Rebholtz,  
DVM

**INVOICE**

10155

**DATE**

3/29/2023

The liver is subjectively normal in size, and echogenicity with smooth peripheral margins. The parenchyma is mildly heterogenous in echotexture with subtle, indistinct focal mottling. The visible portions of the vasculature and biliary tract appear normal. There is a small hyperechoic nodule visualized within the hepatic parenchyma measuring 0.62 cm. Additionally, there is a somewhat irregular hyperechoic lesion measuring 2.0 cm x 1.63 cm visualized on the right side near the diaphragmatic surface of the liver. Additionally, there is larger iso to hyperechoic mass effect visualized near the gallbladder measuring approximately 3.42 cm x 5.01 cm.

The gall bladder lumen is moderately distended. The wall of the gall bladder is not thickened and has a smooth mucosal surface. There is a moderate amount of non-organized echogenic debris. The cystic and common bile ducts are normal/not visible.

**Gastrointestinal**

The stomach contains minimal luminal contents. It measures at a normal thickness of <0.7cm with some variability due to the presence of rugal folds. The distinction of the gastric wall layers is adequate and there is no impression of reduced peristaltic activity. No masses or focal lesions were observed.

The visualized areas of duodenum, jejunum and ileum have a relatively uniform diameter with mild fluid dilation. Wall thickness is normal. Bowel loops follow a curvilinear path with distinct wall layering maintaining the typical 1:3 muscularis: mucosa layer ratio. The duodenum measured as normal (0.47 cm), and the jejunum measured as normal (0.40 cm.) Visualized peristalsis appears appropriate. There were no focal lesions consistent with obstruction or a mass effect observed.

The ileocecal junction was visualized and exhibited normal intact wall layering and is subjectively of normal thickness. Sections of colon are visualized with formed fecal material and gas shadowing distally. There is no observed focal or generalized colon wall thickening or loss of layering.

**Pancreas**

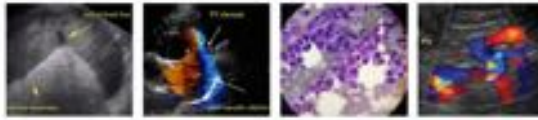
The pancreas is prominent and mottled compared to the surrounding isoechoic mesentery. There is no evidence of nodules or cystic lesions. There is no evidence of regional mesenteric inflammation or fluid.

**Free Abdomen**

Evaluation of the peritoneal cavity did not reveal any evidence of effusion, or subjective lymphadenomegaly. The Medial iliac nodes appear normal and there was no evidence of a caudal aortic thrombus at the bifurcation. The omentum is of normal uniform echogenicity.

**PRIMARY FINDINGS**

- Prominent mottled pancreas. The pancreatic changes are most consistent with age-related parenchymal remodeling, potentially secondary to a prior inflammatory episode, early fibrosis, or chronic pancreatitis.
- Mildly heterogenous liver with two hyperechoic nodules and an iso to hyperechoic mass effect. The appearance of the hyperechoic nodules trends towards a more benign etiology, although continued monitoring is warranted. The larger mass effect is most consistent with a primary hepatic lesion. Primary differential being adenoma, large regenerative nodule, or a carcinoma.
- Moderate gallbladder debris. The significance of the aggregated gallbladder debris is



**PATIENT**

Saffron Bleier

unclear. This could represent an early mucocele, cholestasis, or may be secondary to fasting but seems unlikely to be causing a current issue. Recommend continued monitoring.

**SPECIES**

Canine

- Occasional mild fluid distention of the small intestine, I suspect this is incidental but continued monitoring is warranted.

**BREED**

Fox Wire Terrier

**INTERPRETATION OF THE FINDINGS & FURTHER RECOMMENDATIONS**

**SEX**

Spayed Female

An obvious cause for the decrease in appetite and head tilt is not observed. There are some hepatic nodules and a larger mass lesion visualized. The appearance of these lesions trends towards more benign type lesions, but an underlying neoplastic process or metastatic lesions cannot be definitively ruled out. Consider a fine needle aspirate of the hepatic mass lesion. You could consider conservative management with continued monitoring with ultrasound or even a contrast CT scan to further delineate the nodules/mass lesions and evaluate for possible surgical removal. I would be surprised at this time if these are causing significant symptoms.

**AGE**

12y10m

**WEIGHT**

10kg

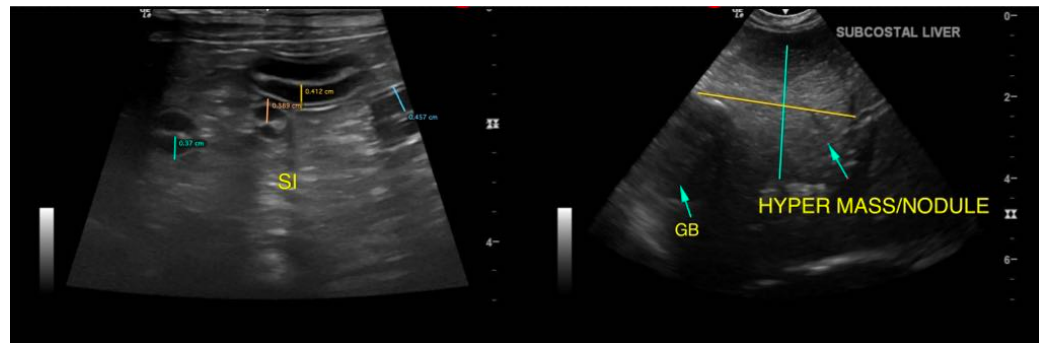
The pancreas is visible but does not appear overtly inflamed. Additionally, there are occasional loops of bowel which appear mildly fluid dilated but no overt evidence of enteritis or foreign material etc. Consider symptomatic therapy. Additionally, consider intracranial and extracranial causes for a head tilt, as this could be contributing as well.

**INTERPRETED BY**

Kathleen Sennello DVM,  
 MS, Diplomate ACVIM  
 (Small Animal Internal  
 Medicine)

**IMAGING PERFORMED BY**

Loetitia Saint-Jacques,  
 LVT

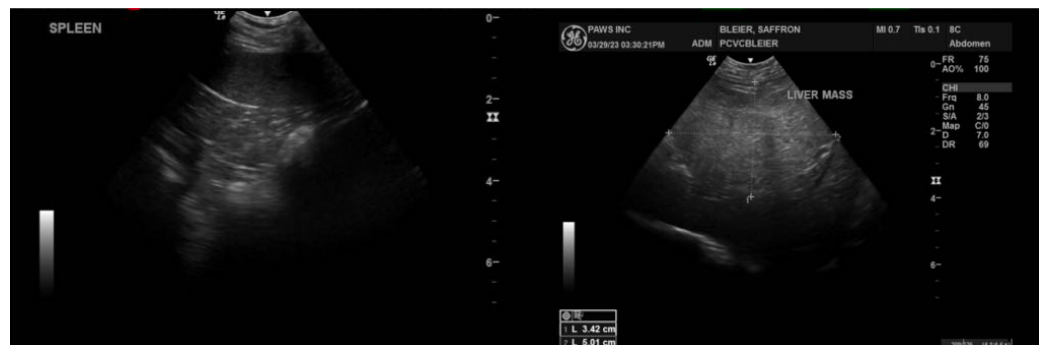


**HOSPITAL NAME**

Pine Creek Veterinary  
 Clinic

**REFERRING VET**

Catherine Rebholtz,  
 DVM



**INVOICE**

10155

**DATE**

3/29/2023



**PATIENT**

Saffron Bleier

**SPECIES**

Canine

**BREED**

Fox Wire Terrier

**SEX**

Spayed Female

**AGE**

12y10m

**WEIGHT**

10kg

**INTERPRETED BY**

Kathleen Sennello DVM,  
MS, Diplomate ACVIM  
(Small Animal Internal  
Medicine)

**IMAGING PERFORMED BY**

Loetitia Saint-Jacques,  
LVT

**HOSPITAL NAME**

Pine Creek Veterinary  
Clinic

**REFERRING VET**

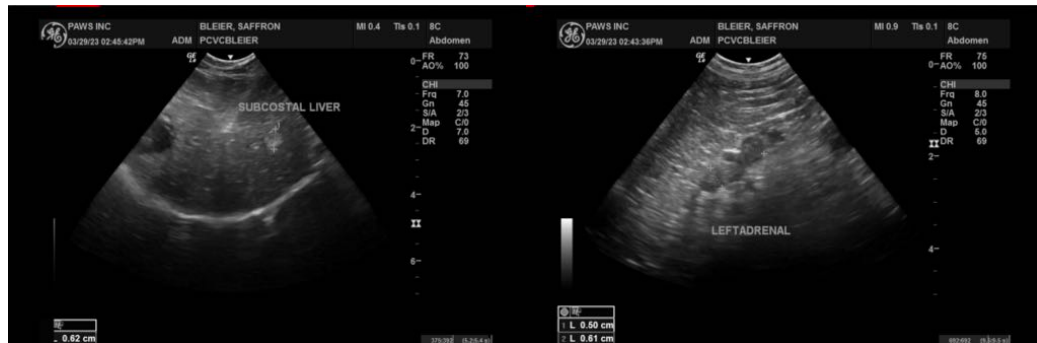
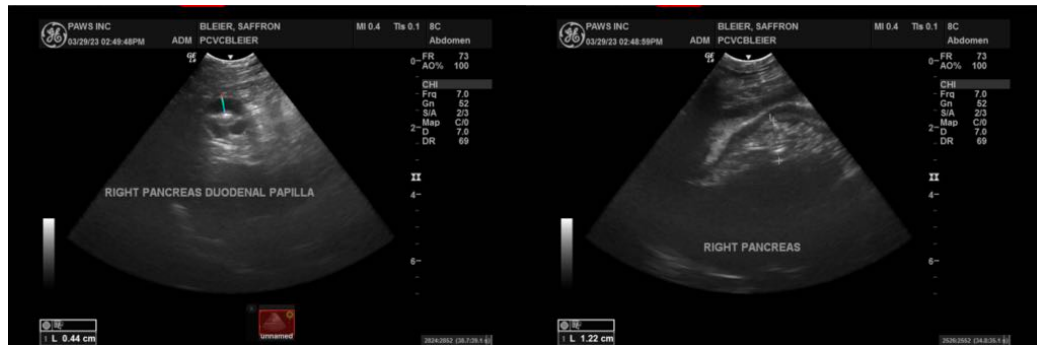
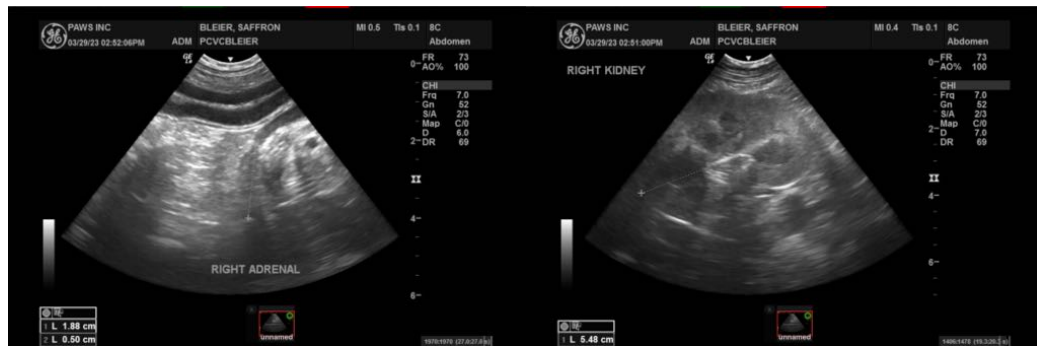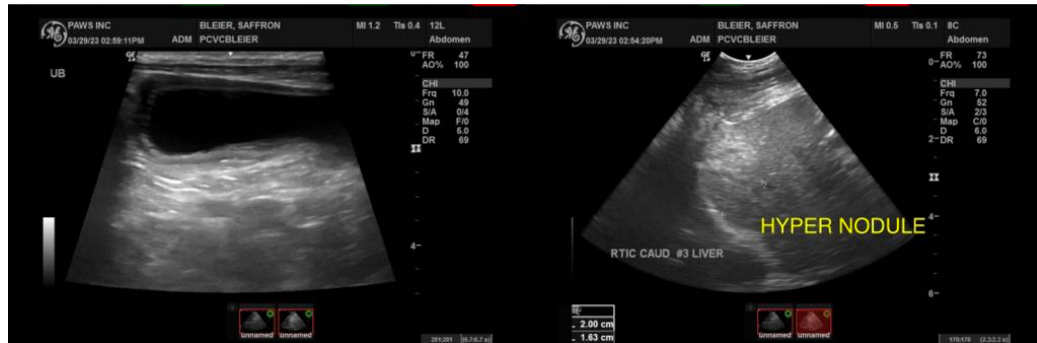
Catherine Rebholtz,  
DVM

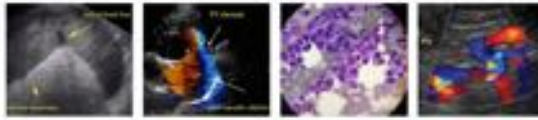
**INVOICE**

10155

**DATE**

3/29/2023





**PATIENT**

Saffron Bleier

**SPECIES**

Canine

**BREED**

Fox Wire Terrier

**SEX**

Spayed Female

**AGE**

12y10m

**WEIGHT**

10kg

**INTERPRETED BY**

Kathleen Sennello DVM,  
MS, Diplomate ACVIM  
(Small Animal Internal  
Medicine)

**IMAGING  
PERFORMED BY**

Loetitia Saint-Jacques,  
LVT

**HOSPITAL NAME**

Pine Creek Veterinary  
Clinic

**REFERRING VET**

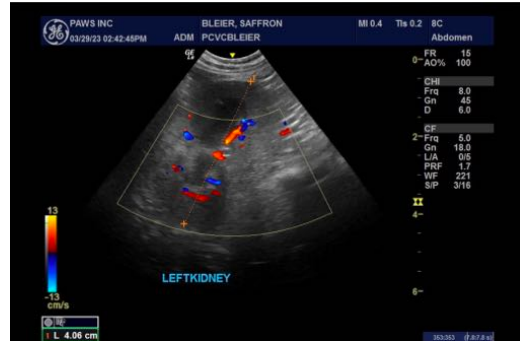
Catherine Rebholtz,  
DVM

**INVOICE**

10155

**DATE**

3/29/2023



The information and recommendations provided are based on the images presented by the referring veterinarian/sonographer. No evaluation can be communicated regarding pathology that was not visible in the image/video clips provided.

Thank you for this referral. If the clinical or image interpretation does not parallel your findings or if I can be of any further assistance, please contact me.

Kathleen Sennello DVM, MS, Diplomate ACVIM (Small animal Internal Medicine)

kathleen.sennello@sonopath.com