

PATIENT PRESENTING CLINICAL SIGNS

Meisha McWilliams

SPECIES

Canine

BREED

Bichon X Shih Tzu

SEX

Spayed Female

AGE

16 Years 7 Months

WEIGHT

4.7 kg

INTERPRETED BY

Kathleen Sennello DVM,
MS, Diplomate ACVIM
(Small Animal Internal
Medicine)

IMAGING PERFORMED BY

Loetitia Saint-Jacques,
LVT

HOSPITAL NAME

Pine Creek Vet Clinic

REFERRING VET

Dr. Dayna Mills

INVOICE

46286

DATE

3/29/23

• Dehydration • Hyporexia • Collapse • Vomiting Freeze dried raw diet- MEDS: Amlodipine 2.5mg 0.5t q24h (in AM) Thyroid-tab 0.1mg 0.5t q12h Proin 25mg 0.5t q24h (in PM); Murmur - Grade IV/VI left apical systolic murmur BP at ER was about 230, but today BP was about 130.
Abnormal PE/Chem/CBC/UA Results: Heska CPP: • BUN 45.9 (H) • Crea 1.2 • P 5.3 (H) • Glob 3.7 (H) • Glu 117 • Chol > 450 (H) • ALT 104 • GGT 15 (H) Heska CBC: • WBC 10.77K • HCT 41.8% • Plt 621K (H) PCV: 48% TS: 9.0 USG: 1.018 Radiographs- NSF

ULTRASONOGRAPHIC EXAMINATION OF THE ABDOMEN

Urinary System

The urinary bladder is mildly distended with anechoic urine. The Bladder wall is diffusely mildly thickened (0.41 cm), and the mucosa is mildly irregular. The trigone, ureteral papillae, and visible urethra (to a depth of 2cm) appear normal with no evidence of severe mucosal irregularities, masses or cystic calculi. Findings are most consistent with bacterial cystitis or lack of urine distension. Recommend urinalysis and culture.

The left kidney has a normal shape and size (3.16 cm) with a nephrolith measuring 0.20 cm and numerous other small mineralizations, and mild pyelectasia at 0.19 cm. Overall echogenicity is slightly hyperechoic with mildly reduced corticomedullary distinction and a typical 1:3 cortex:medulla ratio. There is no evidence of focal perinephric inflammation or effusion. There is no evidence of infarcts or hydroureter. Renal vasculature is normal.

The right kidney has a normal shape and size (3.28 cm) with mild pyelectasia at 0.22 cm. Overall echogenicity is slightly hyperechoic with mildly reduced corticomedullary distinction and a typical 1:3 cortex:medulla ratio. There is no evidence of focal perinephric inflammation or effusion. There is no evidence of nephroliths, infarcts or hydroureter. Renal vasculature is normal.

Adrenal Glands

The left adrenal gland is normal in size measuring 0.48 cm at the caudal pole. It is observed in its normal position cranial to the left renal artery. It is normal in appearance (uniformly hypoechoic) and shape with no evidence of a mass effect.

The right adrenal gland is normal in size measuring 0.54 cm at the caudal pole. It is observed in its normal position between the cranial aspect of the right kidney and the caudal vena cava. It is normal in appearance (uniformly hypoechoic) and shape with no evidence of a mass effect.

Spleen

The spleen is subjectively normal in size, echotexture is homogenous, and the splenic capsule is smooth with no irregularities. The blood flow through the hilus and splenic parenchyma appears normal. No focal parenchymal abnormalities are visualized.

Liver

The liver is subjectively normal in size, and echogenicity with smooth peripheral margins. The parenchyma is homogenous echotexture. The visible portions of the vasculature and biliary tract appear normal. No focal nodules or cystic lesions are observed.



PATIENT
Meisha McWilliams

The gallbladder lumen is moderately distended. The wall of the gall bladder is not thickened and has a smooth mucosal surface. Luminal contents are mild and primarily anechoic. The cystic and common bile ducts are normal/not visible.

SPECIES *Gastrointestinal*

Canine

The stomach contains minimal luminal contents. It measures at a normal thickness of <0.7cm with some variability due to the presence of rugal folds. The distinction of the gastric wall layers is adequate and there is no impression of reduced peristaltic activity. No masses or focal lesions were observed.

BREED

Bichon X Shih Tzu

The visualized areas of duodenum, jejunum and ileum have a relatively uniform diameter with minimal fluid distension. Wall thickness is normal. Bowel loops follow a curvilinear path with distinct wall layering maintaining the typical 1:3 muscularis:mucosa layer ratio. Duodenum wall measures 0.36 cm. Jejunum wall measures 0.28 cm. Visualized peristalsis appears appropriate. There were no focal lesions consistent with obstruction or a mass effect observed.

SEX

Spayed Female

AGE

16 Years 7 Months

The ileocecal junction was visualized and exhibited normal intact wall layering and is subjectively of normal thickness. Sections of colon are visualized with formed fecal material and gas shadowing distally. There is no observed focal or generalized colon wall thickening or loss of layering.

WEIGHT

4.7 kg

Pancreas

The pancreas is prominent and mottled compared to the surrounding isoechoic mesentery. There is no evidence of nodules or cystic lesions. There is no evidence of regional mesenteric inflammation or fluid.

INTERPRETED BY

Kathleen Sennello DVM,
MS, Diplomate ACVIM
(Small Animal Internal
Medicine)

Free Abdomen

Evaluation of the peritoneal cavity did not reveal any evidence of effusion, or subjective lymphadenomegaly. The Medial iliac nodes appear normal and there was no evidence of a caudal aortic thrombus at the bifurcation. The omentum is of normal uniform echogenicity.

IMAGING PERFORMED BY

Loetitia Saint-Jacques,
LVT

ULTRASONOGRAPHIC FINDINGS

- Mildly thickened/irregular urinary bladder wall – The bladder mucosal changes could be consistent with cystitis or artifactual due to lack of adequate luminal distension. Bladder neoplasia cannot be ruled out but is considered unlikely in this patient.
- Mildly reduced corticomedullary distinction in both kidneys with small nephroliths and mild bilateral pyelectasia – Mild loss of corticomedullary distinction in both kidneys could be consistent with chronic degenerative disease or interstitial nephrosis. Pyelectasia of the kidney(s) could be consistent with pyelonephritis, chronic renal disease, secondary to PU/PD or fluid therapy (if applicable), other.
- Prominent, mottled pancreas – The pancreatic changes are most consistent with age-related parenchymal remodeling, potentially secondary to a prior inflammatory episode, early fibrosis or chronic pancreatitis.

HOSPITAL NAME

Pine Creek Vet Clinic

REFERRING VET

Dr. Dayna Mills

INVOICE

46286

DATE

3/29/23

INTERPRETATION OF THE FINDINGS & FURTHER RECOMMENDATIONS

There is a mildly irregular urinary bladder wall and mild pyelectasia and calculi visualized in the kidneys. There is no evidence of an obstructive process, but a urinalysis and culture should be performed to screen for possible infection/pyelonephritis, etc. The pancreas is slightly prominent and mottled, but this is likely most consistent with pancreatic remodeling and previous episodes of pancreatitis.



PATIENT

Meisha McWilliams

SPECIES

Canine

BREED

Bichon X Shih Tzu

SEX

Spayed Female

AGE

16 Years 7 Months

WEIGHT

4.7 kg

INTERPRETED BY

Kathleen Sennello DVM,
MS, Diplomate ACVIM
(Small Animal Internal
Medicine)

IMAGING PERFORMED BY

Loetitia Saint-Jacques,
LVT

HOSPITAL NAME

Pine Creek Vet Clinic

REFERRING VET

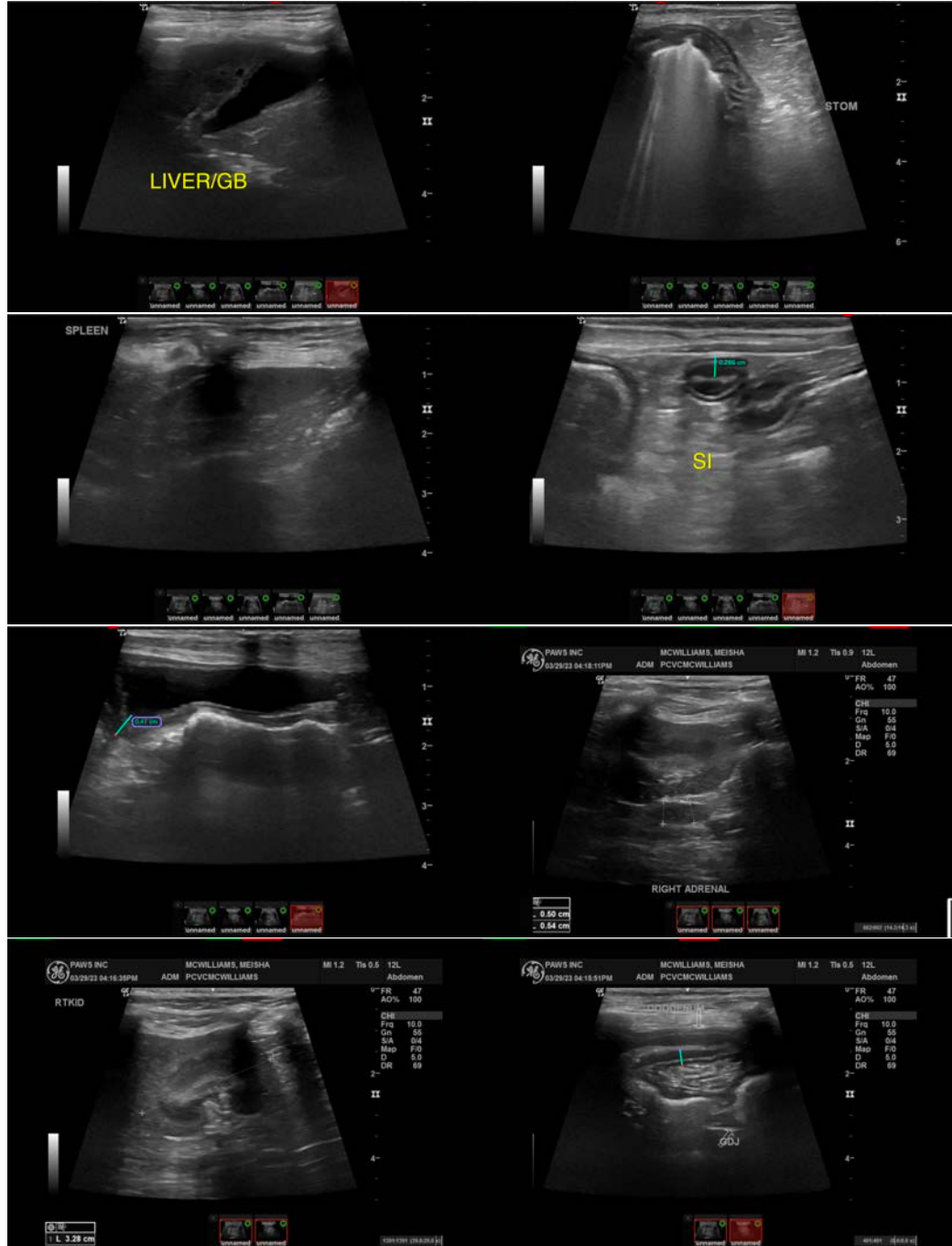
Dr. Dayna Mills

INVOICE

46286

DATE

3/29/23





PATIENT

Meisha McWilliams

SPECIES

Canine

BREED

Bichon X Shih Tzu

SEX

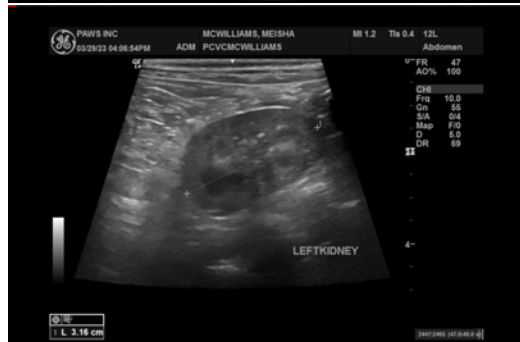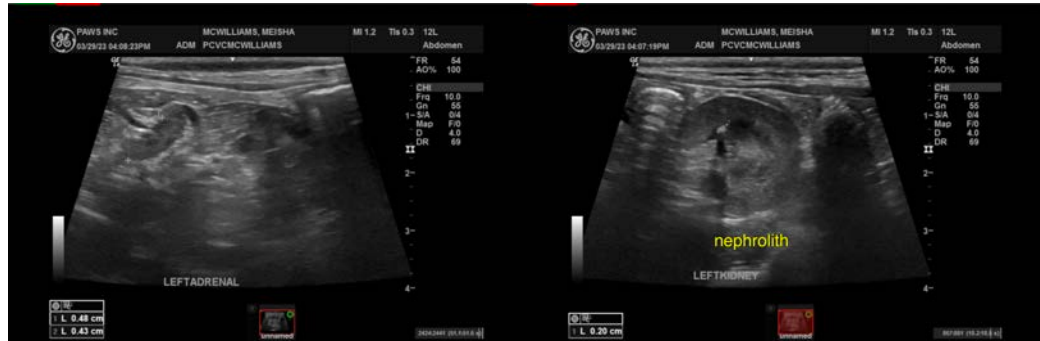
Spayed Female

AGE

16 Years 7 Months

WEIGHT

4.7 kg



INTERPRETED BY

Kathleen Sennello DVM,
MS, Diplomate ACVIM
(Small Animal Internal
Medicine)

IMAGING PERFORMED BY

Loetitia Saint-Jacques,
LVT

HOSPITAL NAME

Pine Creek Vet Clinic

REFERRING VET

Dr. Dayna Mills

INVOICE

46286

DATE

3/29/23

The information and recommendations provided are based on the images presented by the referring veterinarian/sonographer. No evaluation can be communicated regarding pathology that was not visible in the image/video clips provided.

Thank you for this referral. If the clinical or image interpretation does not parallel your findings or if I can be of any further assistance please contact me.

Kathleen Sennello DVM,MS, Diplomate ACVIM (Small animal Internal Medicine)

kathleen.sennello@sonopath.com