

**PATIENT PRESENTING CLINICAL SIGNS**

Kai Marshall History Severe GI issues throughout weekend, vomiting and diarrhea. Major elevation in liver enzymes, Lepto PCR negative. Suspicion of mushroom toxicity. IV Fluids, with KCl added, given the last two days. (3/28 and 3/29). Maropitant IV; Enrofloxacin IV; SQ Penicillin G. Physical Exam Findings On presentation 3/27/20223: Depressed, dehydrated, icteric, febrile. 3/28/2023: IV fluid therapy. Good urine output. 3/29/2023: Ate cooked chicken overnight with no vomiting.

**SPECIES**

Canine

**BREED**

Chihuahua

**SEX**

Neutered Male

**AGE**

12y

**WEIGHT**

14lbs

**INTERPRETED BY**

Kathleen Sennello DVM,  
MS, Diplomate ACVIM  
(Small Animal Internal  
Medicine)

**IMAGING PERFORMED BY**

Loetitia Saint-Jacques,  
LVT

**HOSPITAL NAME**

FourPaws Animal  
Clinic

**REFERRING VET**

Dr. Susan Lester

**INVOICE**

10152

**DATE**

3/29/2023

**ULTRASONOGRAPHIC EXAMINATION OF THE ABDOMEN**

**Urinary System**

The urinary bladder is moderately distended with anechoic urine. The Bladder wall, trigone, ureteral papillae, and visible urethra (to a depth of 2cm) appear normal with no evidence of wall thickening, mucosal irregularities, masses, or cystic calculi.

The prostate is normal in size (0.7 cm) and shape for this neutered male dog. The parenchyma is homogenous, and the external margins are smooth. The prostatic urethra appears normal with no evidence of irregularity, invasion, mass effect or calculi.

The left kidney has a normal shape and size (5.01 cm). Overall echogenicity is normal with adequate corticomedullary distinction and a typical 1:3 cortex: medulla ratio. There is no evidence of focal perinephric inflammation or effusion. There is no evidence of pyelectasia, nephroliths, infarcts or hydroureter. Renal vasculature is normal.

The right kidney has a normal shape and size (5.51 cm). Overall echogenicity is normal with adequate corticomedullary distinction and a typical 1:3 cortex: medulla ratio. There is no evidence of focal perinephric inflammation or effusion. There is no evidence of pyelectasia, nephroliths, infarcts or hydroureter. Renal vasculature is normal.

**Adrenal Glands**

The left adrenal gland is normal in size measuring 0.67 cm at the caudal pole. It is observed in its normal position cranial to the left renal artery. It is normal in appearance (uniformly hypoechoic) and shape with no evidence of a mass effect.

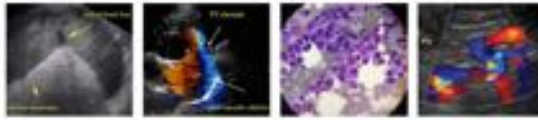
The right adrenal gland is normal in size measuring 0.59 cm at the caudal pole. It is observed in its normal position between the cranial aspect of the right kidney and the caudal vena cava. It is normal in appearance (uniformly hypoechoic) and shape with no evidence of a mass effect.

**Spleen**

The spleen is subjectively normal in size, echotexture is homogenous, and the splenic capsule is smooth with no irregularities. The blood flow through the hilus and splenic parenchyma appears normal. No focal parenchymal abnormalities are visualized.

**Liver**

The liver is subjectively normal in size, and echogenicity with smooth peripheral margins. The parenchyma is heterogenous in echotexture with subtle, indistinct focal mottling. There are two hypoechoic nodules visualized within the liver, one is smaller measuring 1.14 cm in diameter and less



**PATIENT**

Kai Marshall

defined. There is a larger slightly more complex lesion visualized in the subcostal view deep adjacent to the duodenum measuring 1.38 cm x 2.28 cm. Additionally, there is a small anechoic structure visualized in the right side, most consistent with a cyst measuring 0.9 cm. The intrahepatic bile ducts appear diffusely dilated with too numerous to count intrahepatic biliary stones, some of which can be visualized as motile within the intrahepatic bile ducts.

**SPECIES**

Canine

The gallbladder lumen is significantly distended. There is a large amount of suspended and dependent mineralized sediment, some of this appears adhered to the gallbladder wall. There is an appearance of a shadowing cholelith measuring 1.36 cm (or could be a pile of smaller stones/sandy debris.) The gallbladder has a small amount of free fluid adjacent to it with minimal surrounding inflammation. The bile duct distally is severely dilated and torturous with thickened walls and numerous intraluminal calculi, some of which appear motile. Examples of these stones measure 0.74 cm and 1.0 cm x 0.74 cm. Intrahepatic biliary stones measuring 0.46 cm and 0.32 cm, etc. Bile duct dilation extends to the level of the duodenal papillae but there is no obvious mass effect or stone at this point.

**BREED**

Chihuahua

**SEX**

Neutered Male

**AGE**

12y

**Gastrointestinal**

The stomach contains minimal luminal contents. It measures at a normal thickness of <0.7cm with some variability due to the presence of rugal folds. The distinction of the gastric wall layers is adequate and there is no impression of reduced peristaltic activity. No masses or focal lesions were observed.

**WEIGHT**

14lbs

The visualized areas of duodenum, jejunum and ileum have a relatively uniform diameter with minimal fluid distension. Wall thickness is normal. Bowel loops follow a curvilinear path with distinct wall layering maintaining the typical 1:3 muscularis: mucosa layer ratio. The duodenum measured as normal (0.45 cm), and the jejunum measured as normal (0.35 cm.) Visualized peristalsis appears appropriate. There were no focal lesions consistent with obstruction or a mass effect observed.

**INTERPRETED BY**

Kathleen Sennello DVM,  
MS, Diplomate ACVIM  
(Small Animal Internal  
Medicine)

The ileocecal junction was visualized and exhibited normal intact wall layering and is subjectively of normal thickness. Sections of colon are visualized with formed fecal material and gas shadowing distally. There is no observed focal or generalized colon wall thickening or loss of layering.

**IMAGING PERFORMED BY**

Loetitia Saint-Jacques,  
LVT

**Pancreas**

The pancreas is large and hypoechoic to surrounding mesentery. There is no evidence of nodules or cystic lesions. There is evidence of regional mesenteric inflammation. Consistent with mild pancreatitis.

**HOSPITAL NAME**

FourPaws Animal  
Clinic

**Free Abdomen**

Evaluation of the peritoneal cavity did reveal a small amount of free abdominal fluid, and mild lymphadenopathy is noted with pancreaticoduodenal lymph node measuring 0.43 cm in diameter. Additionally, near the right limb of the pancreas there is a rounded mottled hypoechoic structure which appears similar to the pancreatic tissue but appears rounded, similar to a lymph node. This lesion measures 1.34 cm x 2.88 cm. The omentum is hyperechoic in the cranial abdomen around the pancreas and the bile duct.

**REFERRING VET**

Dr. Susan Lester

**INVOICE**

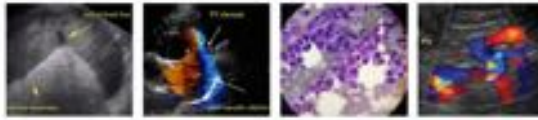
10152

**PRIMARY FINDINGS**

**DATE**

3/29/2023

- Hypoechoic prominent pancreas surrounded by hyperechoic mesentery. The pancreatic changes are most consistent with mild pancreatitis/pancreatic infiltration. Recommend fPLI



**PATIENT**

Kai Marshall

**SPECIES**

Canine

**BREED**

Chihuahua

**SEX**

Neutered Male

**AGE**

12y

**WEIGHT**

14lbs

testing and continued monitoring for improvement or possible development of a pancreatic abscess. Consider fine needle aspirate if not improving.

- Heterogenous liver with two hypoechoic nodules. The diffuse hepatic changes are non-specific and could be consistent with vacuolar hepatopathy, nodular hyperplasia, inflammatory/immune-mediated disease, fibrosis, extramedullary hematopoiesis, toxic hepatopathy (e.g., copper), infiltrative neoplasia (less likely) or other hepatopathy. The larger hypoechoic nodule described in the subcostal view is slightly more concerning as it appears more expansile. The appearance of the smaller nodule trends towards a more benign lesion, both of these lesions are likely to deep to easily sample, recommend continued monitoring with ultrasound.
- Distended hepatic and post hepatic bile ducts with wall thickening and too numerous to count biliary stones, some of which appear model, and others are concerning for possible obstruction/partial obstructions. Findings are consistent with biliary tract obstructions (partial vs. complete.)
- Small volume free abdominal fluid. Recommend fluid analysis and cytology.
- Questionable large lymph node in the region of the pancreas vs. rounded irregular pancreatic tissue. Consider a fine needle aspirate of this region.

**INTERPRETED BY**

Kathleen Sennello DVM,  
MS, Diplomate ACVIM  
(Small Animal Internal  
Medicine)

**IMAGING  
PERFORMED BY**

Loetitia Saint-Jacques,  
LVT

**HOSPITAL NAME**

FourPaws Animal  
Clinic

**REFERRING VET**

Dr. Susan Lester

**INVOICE**

10152

**DATE**

3/29/2023

**INTERPRETATION OF THE FINDINGS & FURTHER RECOMMENDATIONS**

There are too numerous to count hepatic and post hepatic biliary stones, with dilated bile ducts and significant wall thickening, consistent with cholecystitis. The gallbladder itself is thickened with mineralizations and likely stones. There is some free fluid adjacent to the gallbladder, but my suspicion is that a gallbladder obstruction is not present although this is not definitive, and an impending rupture is also a possibility. Recommend sampling of the free fluid for fluid analysis, cytology, and +/- culture.

Based on the number of stones present this is likely to be a long-term issue for this individual. Medical treatment of cholecystitis with antibiotics, ursodiol, fluids, etc. may be helpful but in the event of a complete obstruction surgery would be the only option. Options moving forward at this point include surgical evaluation for possible cholecystoduodenostomy with the hopes that this will by-pass the bile duct and allow the passage of larger stones and facilitate normal bile flow.

Alternately, if surgery is not an option consider medical management of cholecystitis. I cannot definitively determine if the gallbladder is intact, I suspect it is, but it is likely that surgical evaluation would be necessary to confirm this. Additionally, cytologic evaluation of the abdominal fluid would be very helpful.

The pancreas appears hypoechoic and prominent with surrounding inflammation, much of this inflammation could be secondary to the biliary obstructions and cholecystitis but concurrent pancreatitis is also likely. Recommend treatment for pancreatitis and either sampling of the area of rounded tissue that could be lymph node or pancreas or continued monitoring of this region. As a underlying neoplastic process cannot be ruled out but seems less likely.

Recommend three view thoracic radiographs to evaluate for possible concurrent thoracic disease/involvement.



**PATIENT**

Kai Marshall

**SPECIES**

Canine

**BREED**

Chihuahua

**SEX**

Neutered Male

**AGE**

12y

**WEIGHT**

14lbs

**INTERPRETED BY**

Kathleen Sennello DVM,  
MS, Diplomate ACVIM  
(Small Animal Internal  
Medicine)

**IMAGING  
PERFORMED BY**

Loetitia Saint-Jacques,  
LVT

**HOSPITAL NAME**

FourPaws Animal  
Clinic

**REFERRING VET**

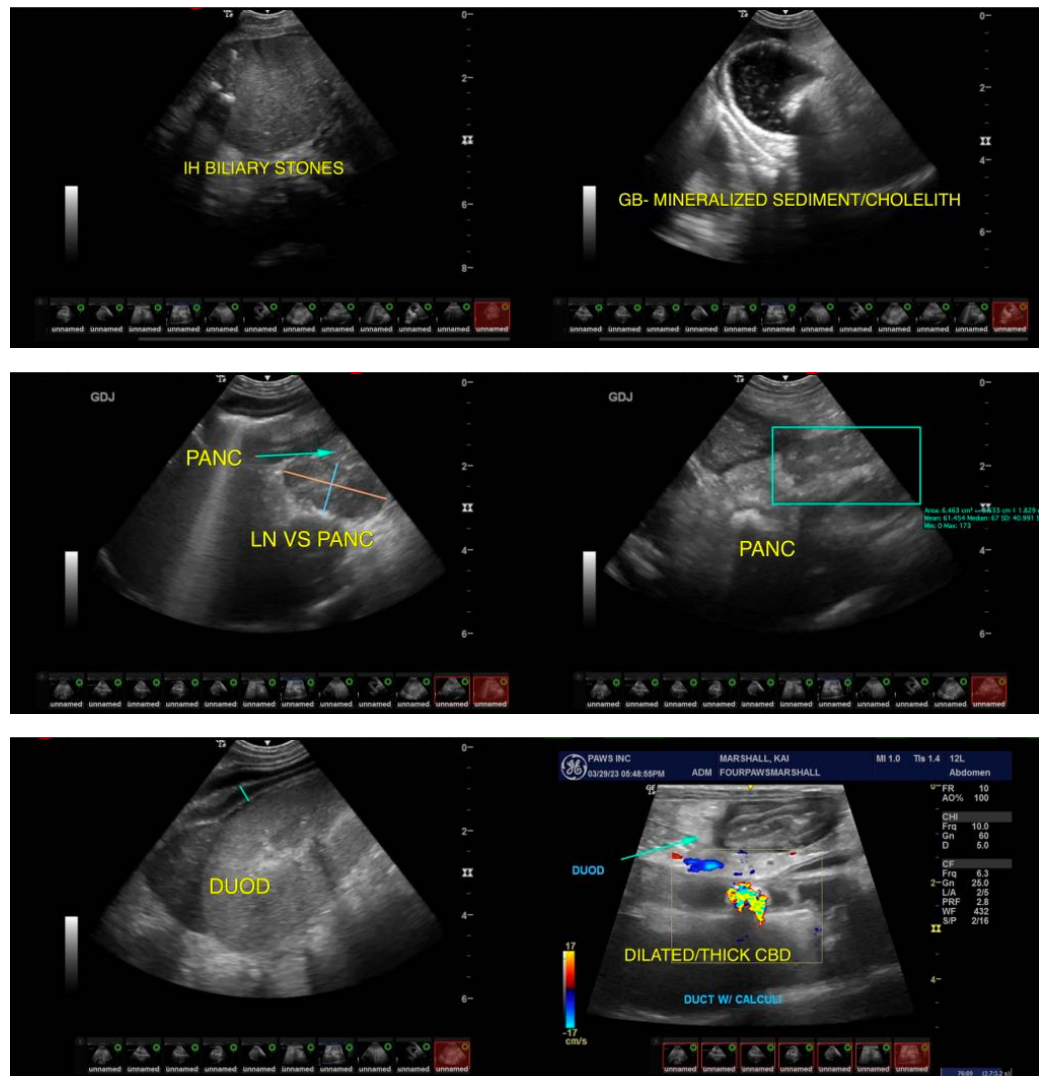
Dr. Susan Lester

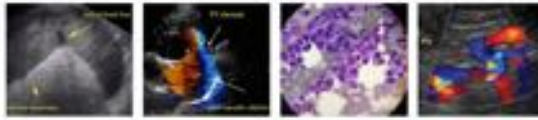
**INVOICE**

10152

**DATE**

3/29/2023





**PATIENT**

Kai Marshall

**SPECIES**

Canine

**BREED**

Chihuahua

**SEX**

Neutered Male

**AGE**

12y

**WEIGHT**

14lbs

**INTERPRETED BY**

Kathleen Sennello DVM,  
MS, Diplomate ACVIM  
(Small Animal Internal  
Medicine)

**IMAGING  
PERFORMED BY**

Loetitia Saint-Jacques,  
LVT

**HOSPITAL NAME**

FourPaws Animal  
Clinic

**REFERRING VET**

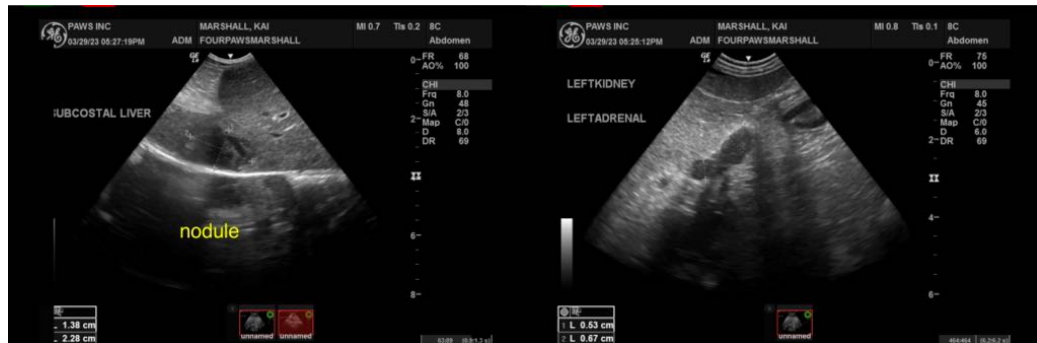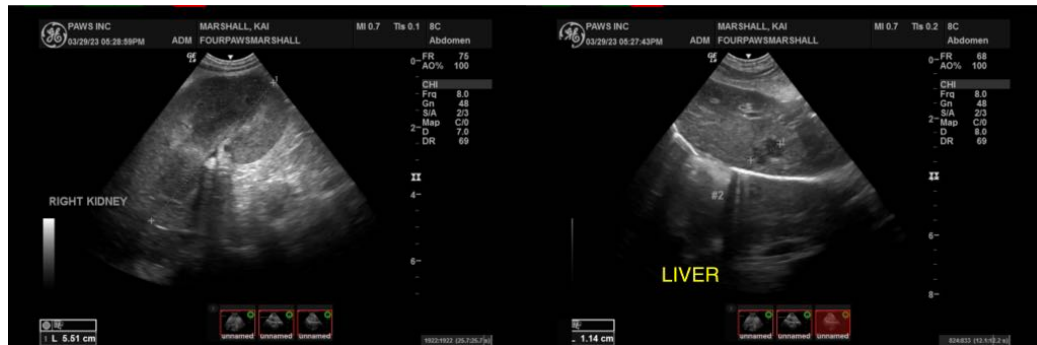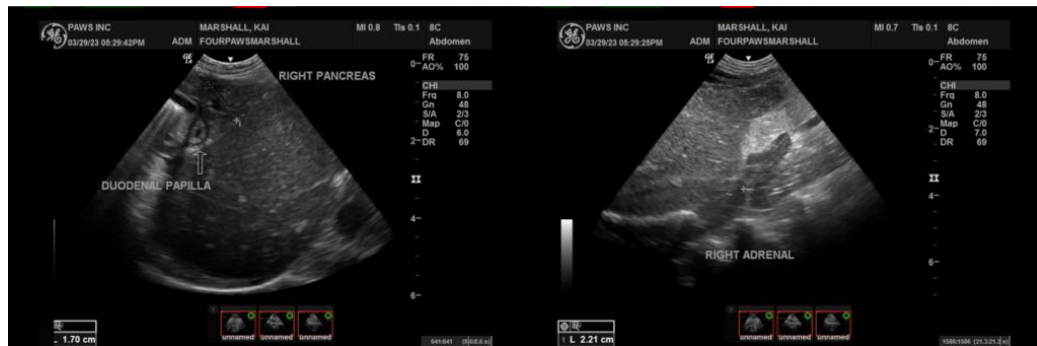
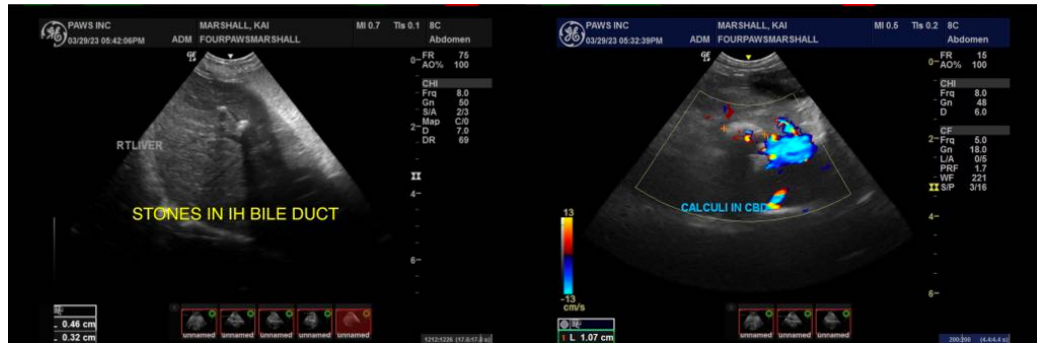
Dr. Susan Lester

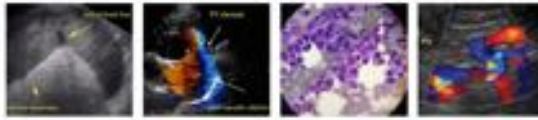
**INVOICE**

10152

**DATE**

3/29/2023





**PATIENT**

Kai Marshall

**SPECIES**

Canine

**BREED**

Chihuahua

**SEX**

Neutered Male

**AGE**

12y

**WEIGHT**

14lbs

**INTERPRETED BY**

Kathleen Sennello DVM,  
MS, Diplomate ACVIM  
(Small Animal Internal  
Medicine)

**IMAGING  
PERFORMED BY**

Loetitia Saint-Jacques,  
LVT

**HOSPITAL NAME**

FourPaws Animal  
Clinic

**REFERRING VET**

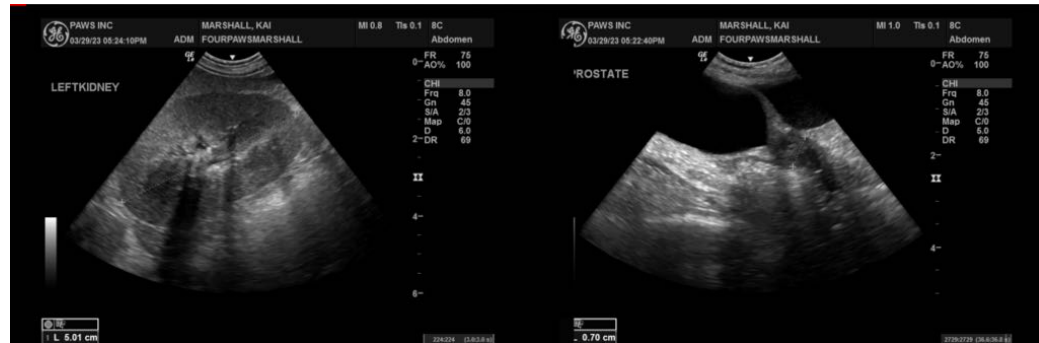
Dr. Susan Lester

**INVOICE**

10152

**DATE**

3/29/2023



The information and recommendations provided are based on the images presented by the referring veterinarian/sonographer. No evaluation can be communicated regarding pathology that was not visible in the image/video clips provided.

Thank you for this referral. If the clinical or image interpretation does not parallel your findings or if I can be of any further assistance, please contact me.

Kathleen Sennello DVM, MS, Diplomate ACVIM (Small animal Internal Medicine)

kathleen.sennello@sonopath.com