

**DATE PRESENTING CLINICAL SIGNS**

3/29/23 5 week history of intermittent hyporexia/anorexia, vomiting, lethargy, weight loss. Elevated PLI noted 3/7, hypoalbuminemia and unclassified cells noted on lab work in Feb. Suspect pancreatitis +/- GI disease +/- neoplasia.

**PATIENT**

Hope Jackson

Current Medications: None currently.

**SPECIES**

Feline

Lab Results: 3/7: PLI 7.0, normal TLI, B12, folate. 2/16: CBC--neuts 16K, 748 unclassified cells (no path review by pathologist but technologist noted neuts appeared severely toxic). Chem--albumin 2.4 UA--trace glucosuria. 1/11: Unremarkable CBC, phos 2.1, Na 145, Cl 105, 2+ glucosuria on UA.

Date of Previous IntraPet Ultrasound: No previous.

Sedation: Not required to complete full diagnostic ultrasound.

Stat Report: Not requested.

**BREED**

DSH

Imaging Performed By: Andi Parkinson, BS, RDMS.

**ULTRASONOGRAPHIC EXAMINATION OF THE ABDOMEN****SEX**

Spayed Female

**Urinary System**

The urinary bladder is moderately distended with anechoic urine. The Bladder wall, trigone, ureteral papillae and visible urethra (to a depth of 2cm) appear normal with no evidence of wall thickening, mucosal irregularities, masses or cystic calculi.

**AGE**

2/27/12

The left kidney has a normal shape and size (3.17 cm). Overall echogenicity is normal with adequate corticomedullary distinction and a typical 1:3 cortex:medulla ratio. There is no evidence of focal perinephric inflammation or effusion. There is no evidence of pyelectasia, nephroliths, infarcts or hydroureter. Renal vasculature is normal.

**WEIGHT**

3.05 kg

The right kidney has a normal shape and size (3.53 cm). Overall echogenicity is normal with adequate corticomedullary distinction and a typical 1:3 cortex:medulla ratio. There is no evidence of focal perinephric inflammation or effusion. There is no evidence of pyelectasia, nephroliths, infarcts or hydroureter. Renal vasculature is normal.

**INTERPRETED BY**

Kathleen Sennello DVM,  
MS, Diplomate ACVIM  
(Small Animal Internal  
Medicine)

**Adrenal Glands**

The region of left adrenal (Cranial to left renal artery) is unremarkable but the adrenal is not distinctly visualized. No evidence of a mass effect is visualized.

**HOSPITAL NAME**

Nexus Vet Specialists

The right adrenal gland is normal in size measuring 0.41 cm at the caudal pole. It is observed in its normal position between the cranial aspect of the right kidney and the caudal vena cava. It is normal in appearance (uniformly hypoechoic) and shape with no evidence of a mass effect.

**REFERRING VET**

Dr. Steele

**Spleen**

The spleen is borderline large (1.3 cm) with scalloped edges. The blood flow through the hilus and splenic parenchyma appears normal. No focal parenchymal abnormalities are visualized.

**INVOICE**

46261

**Liver**

The liver is subjectively normal in size, and echogenicity with smooth peripheral margins. The parenchyma is homogenous echotexture. The visible portions of the vasculature and biliary tract appear normal. No focal nodules or cystic lesions are observed.

The gallbladder lumen is moderately distended. The wall of the gall bladder is not thickened and has a smooth mucosal surface. Luminal contents are mild and primarily anechoic. The cystic and common bile ducts are normal/not visible.

### ***Gastrointestinal***

The stomach contains minimal luminal contents. It measures at a normal thickness of <0.36cm with some variability due to the presence of rugal folds. The distinction of the gastric wall layers is adequate and there is no impression of reduced peristaltic activity. No masses or focal lesions were observed.

The visualized areas of duodenum, jejunum and ileum have a relatively uniform diameter with minimal fluid distension. Wall thickness is normal. Bowel loops follow a curvilinear path with distinct wall layering maintaining the typical 1:3 muscularis:mucosa layer ratio. Jejunum wall measures 0.23 cm. Visualized peristalsis appears appropriate. There were no focal lesions consistent with obstruction or a mass effect observed.

The ileocecal junction was visualized and exhibited normal intact wall layering and is subjectively of normal thickness. Sections of colon are visualized with formed fecal material and gas shadowing distally. There is no observed focal or generalized colon wall thickening or loss of layering.

### ***Pancreas***

The pancreas is large and hypoechoic to surrounding mesentery. There is a hypoechoic cystic structure visualized within the pancreatic tissue measuring 0.43 cm x 0.38 cm, most consistent with a pancreatic cyst. There is evidence of regional mesenteric inflammation. Consistent with moderate pancreatitis.

### ***Free Abdomen***

Evaluation of the peritoneal cavity did not reveal any evidence of effusion, or subjective lymphadenomegaly. The Medial iliac nodes appear normal and there was no evidence of a caudal aortic thrombus at the bifurcation. The omentum is of normal uniform echogenicity.

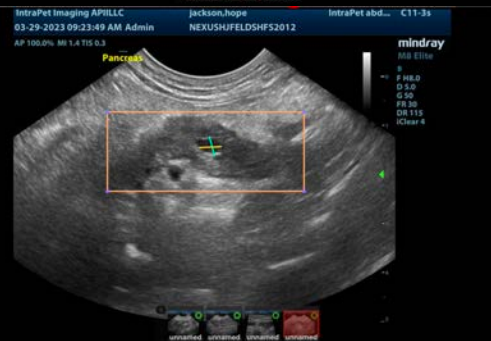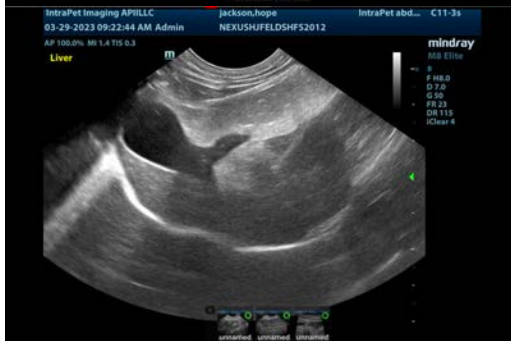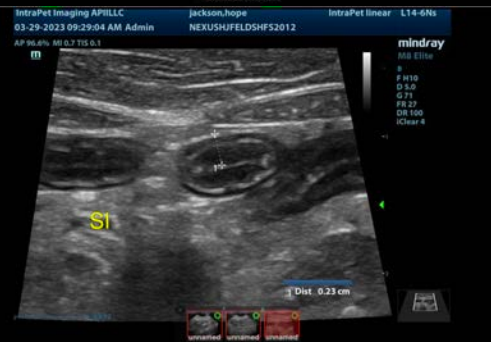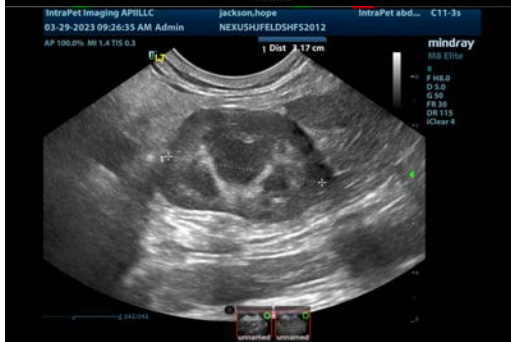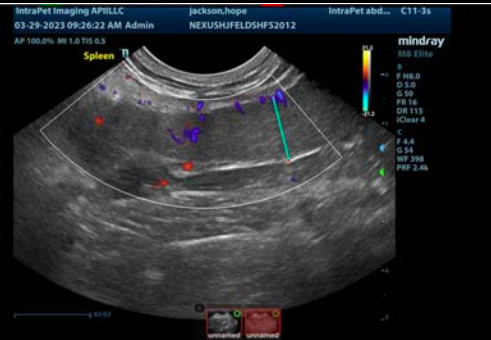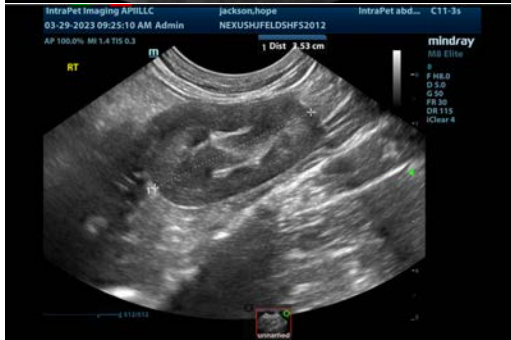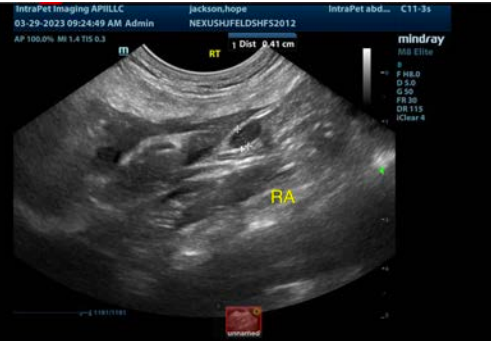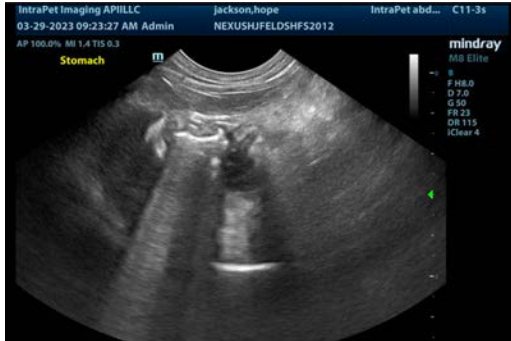## **ULTRASONOGRAPHIC FINDINGS**

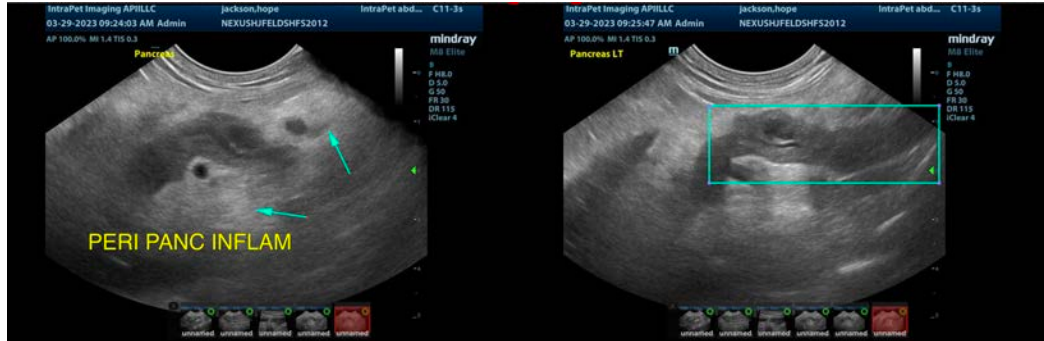
- Large, hypoechoic pancreas with a cystic lesion and severe surrounding inflammation – Findings are most consistent with moderate/severe pancreatitis – The pancreatic changes are most consistent with moderate pancreatitis/pancreatic inflammation. Recommend fPLI testing and continued monitoring for improvement or possible development of a pancreatic abscess. Consider fine needle aspirate if not improving.
- Prominent, borderline large spleen – Possible differentials include anatomic variation, congestion, infiltrative disease, etc.

## **INTERPRETATION OF THE FINDINGS & FURTHER RECOMMENDATIONS**

Ultrasonographic abnormalities noted on today's exam include a large inflamed hypoechoic pancreas with a pancreatic cystic structure and a borderline large spleen with scalloped edges.

Further diagnostic and therapeutic recommendations regarding this exam to be made by Dr. Cara Steele.





The information and recommendations provided are based on the images presented by the referring veterinarian/sonographer. No evaluation can be communicated regarding pathology that was not visible in the image/video clips provided.

Thank you for this referral. If the clinical or image interpretation does not parallel your findings or if I can be of any further assistance please contact me.

Kathleen Sennello DVM,MS, Diplomate ACVIM (Small animal Internal Medicine)  
kathleen.sennello@sonopath.com