

**DATE PRESENTING CLINICAL SIGNS**

3/29/22 Seen for simple diarrhea on 3/28/22. On abdominal palpation, able to feel a 4cm firm abdominal mass.

PATIENT Date of Previous IntraPet Ultrasound: No previous.

Zoe Perrone Sedation: Not required to complete full diagnostic ultrasound.

Stat Report: Not requested.

SPECIES ULTRASONOGRAPHIC EXAMINATION OF THE ABDOMEN

Canine

Urinary System

The urinary bladder is moderately distended with anechoic urine. The Bladder wall, trigone, ureteral papillae and visible urethra (to a depth of 2cm) appear normal with no evidence of wall thickening, mucosal irregularities, masses or cystic calculi.

BREED

Pit X

The left kidney has a normal shape and size (6.28 cm). Overall echogenicity is normal with adequate corticomedullary distinction and a typical 1:3 cortex:medulla ratio. There is no evidence of perinephric inflammation or effusion. There is no evidence of pyelectasia, nephroliths, infarcts or hydroureter. Renal vasculature is normal.

SEX

Spayed Female

AGE

8/8/07

The right kidney has a normal shape and size (6.65 cm). Overall echogenicity is normal with adequate corticomedullary distinction and a typical 1:3 cortex:medulla ratio. There is no evidence of perinephric inflammation or effusion. There is no evidence of pyelectasia, nephroliths, infarcts or hydroureter. Renal vasculature is normal.

WEIGHT

40.2 Pounds

Adrenal Glands

The left adrenal gland is normal in size measuring 0.63 cm at the caudal pole. It is observed in its normal position cranial to the left renal artery. It is normal in appearance (uniformly hypoechoic) and shape with no evidence of a mass effect.

INTERPRETED BY

Kathleen Sennello DVM,
MS, Diplomate ACVIM
(Small Animal Internal
Medicine)

The right adrenal gland is normal in size measuring 0.60 cm at the caudal pole. It is observed in its normal position between the cranial aspect of the right kidney and the caudal vena cava. It is normal in appearance (uniformly hypoechoic) and shape with no evidence of a mass effect.

IMAGING PERFORMED BY

Stephanie Pearce
RDMS, RVT

Spleen

The spleen is large in size. The spleen echotexture is heterogenous and mottled, the splenic capsule is smooth with no irregularities. The blood flow through the hilus and splenic parenchyma appears normal. There is a non-cavitated, mixed echogenicity mass effect in the caudal third of the spleen measuring 2.73 cm x 3.11 cm.

HOSPITAL NAME

Hickory Vet Hospital

Liver

The liver is subjectively normal in size, and echogenicity with smooth peripheral margins. The parenchyma is homogenous echotexture. The visible portions of the vasculature and biliary tract appear normal. No focal nodules or cystic lesions are observed.

REFERRING VET

Dr. Silcox

The gall bladder lumen is moderately distended. The wall of the gall bladder is not thickened and has a smooth mucosal surface. There is a moderate amount of non-organized echogenic debris. The cystic and common bile ducts are normal/not visible.

INVOICE

36548

Gastrointestinal

The stomach contains minimal luminal contents. It measures at a normal thickness of <0.7cm with some variability due to the presence of rugal folds. The distinction of the gastric wall layers is adequate and there is no impression of reduced peristaltic activity. No masses or focal lesions were observed.

The visualized areas of duodenum, jejunum and ileum have a relatively uniform diameter with minimal fluid distension. Wall thickness is normal. Bowel loops follow a curvilinear path with distinct wall layering maintaining the typical 1:3 muscularis:mucosa layer ratio. The duodenum measured as normal (between 0.3-0.5cm in wall thickness) and the jejunum measured as normal (between 0.2-0.47cm.) Visualized peristalsis appears appropriate. There were no focal lesions consistent with obstruction or a mass effect observed.

The ileocecal junction was visualized and exhibited normal intact wall layering and is subjectively of normal thickness. Sections of colon are visualized with formed fecal material and gas shadowing distally. There is no observed focal or generalized colon wall thickening or loss of layering.

Pancreas

The pancreas is normal and isoechoic to surrounding mesentery. There is no evidence of nodules or cystic lesions. There is no evidence of regional mesenteric inflammation or fluid.

Free Abdomen

Evaluation of the peritoneal cavity did not reveal any evidence of effusion, or subjective lymphadenomegaly. The Medial iliac nodes appear normal and there was no evidence of a caudal aortic thrombus at the bifurcation. The omentum is of normal uniform echogenicity.

Other

A brief view of the heart was submitted. No significant pericardial effusion was seen.

There is an approximately 3.5 cm diameter, rounded structure visualized caudal to the urinary bladder and partially intrapelvic, most consistent with an intraluminal mass effect. Primary differential would be uterine body mass/granuloma, etc. Other differentials are possible.

PRIMARY FINDINGS

- Moderate sized, mixed echogenicity splenic mass – A focal, solid, mixed echogenic mass is present within the splenic parenchyma. This mass distorts the splenic capsule. Differentials include benign lesions such as lymphoid hyperplasia, hemangioma, etc., or neoplastic lesions such as hemangiosarcoma, lymphoma, histiocytic sarcoma, etc.
- Large intrapelvic mass – Consider such differentials as a benign or malignant uterine stump mass/granuloma

SECONDARY FINDINGS

- Moderate gallbladder debris – The significance of the aggregated gallbladder sludge is unclear. This could represent an early mucocele, cholestasis, or may be secondary to fasting.

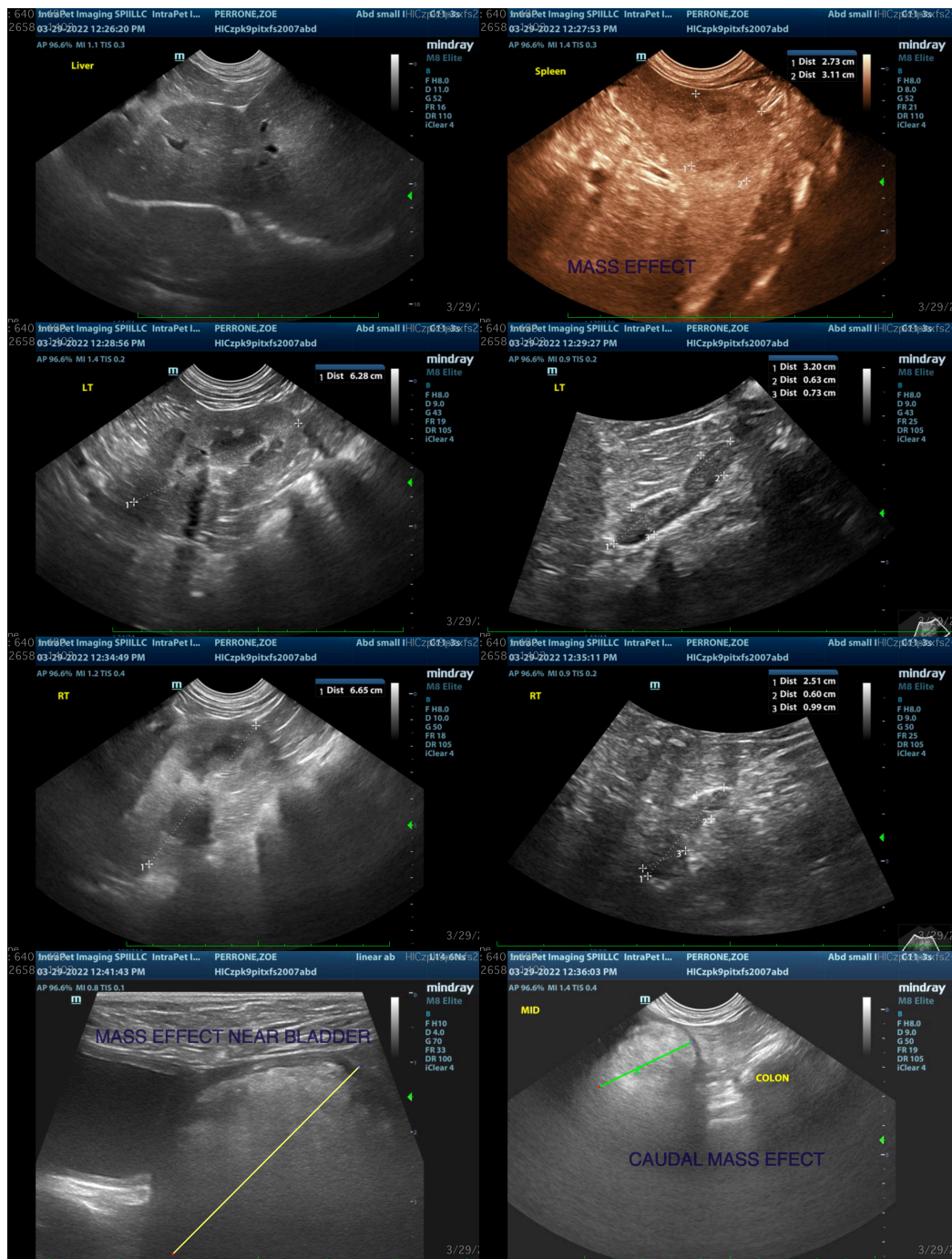
INTERPRETATION OF THE FINDINGS & FURTHER RECOMMENDATIONS

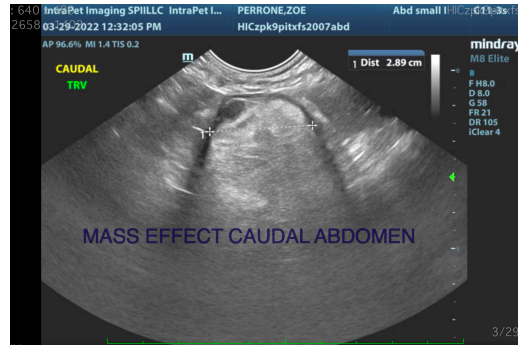
There is a solid splenic mass lesion visualized. Options moving forward include either surgical splenectomy with histopath for both therapeutic and diagnostic purposes (as long as 3-view thoracic radiographs appear normal) or alternately, if a more conservative approach is desired, a fine needle aspirate of the mass effect could be considered, although this would not definitively rule out a neoplastic process.

Additionally, there is an intrapelvic lesion present. This appears to be a luminal structure with either a mass effect or echogenic material within it. This is most likely uterine body in origin, although other possibilities exist. Consider a fine needle aspirate of this lesion.

This intrapelvic mass could be evaluated at the time of surgery of the spleen (ideally referral to a veterinary

surgeon, due to the challenging location, or alternately you could consider a contrast CT scan prior to moving forward to look for any evidence of metastasis and to get better resolution and information on the intrapelvic mass.





The information and recommendations provided are based on the images presented by the referring veterinarian/sonographer. No evaluation can be communicated regarding pathology that was not visible in the image/video clips provided.

Thank you for this referral. If the clinical or image interpretation does not parallel your findings or if I can be of any further assistance please contact me.

Kathleen Sennello DVM,MS, Diplomate ACVIM (Small animal Internal Medicine)
kathleen.sennello@sonopath.com