



**PATIENT**

Tolkien Coenung

**SPECIES**

Feline

**BREED**

Domestic Shorthair

**SEX**

Neutered male

**AGE**

4 years

**WEIGHT**

11 lbs 12 oz

**INTERPRETED BY**

Kathleen Sennello  
DVM, MS, Diplomate  
ACVIM (Small Animal  
Internal Medicine)

**IMAGING  
PERFORMED BY**

Jessica Miller, RDMS

**HOSPITAL NAME**

Animal Care Center of  
Flanders

**REFERRING VET**

Dr. Hallihan

**INVOICE**

97909

**DATE**

3/29/22

**PRESENTING CLINICAL SIGNS**

History: Pre dental, iris stage 2 renal BUN 29, CREAT 2.3  
Abnormal PE/Chem/CBC/UA Results: Albumin 4.0, Calcium 10.9, Chole 292, Platelet Count 190 UA:  
pH 7.5 SG: 1.036

**ULTRASONOGRAPHIC EXAMINATION OF THE ABDOMEN**

*Urinary System*

The urinary bladder is moderately distended with anechoic urine. The Bladder wall, trigone, ureteral papillae and visible urethra (to a depth of 2cm) appear normal with no evidence of wall thickening, mucosal irregularities, masses or cystic calculi.

The left kidney has a normal shape and size (4.13 cm). Overall echogenicity is normal with adequate corticomedullary distinction and a typical 1:3 cortex:medulla ratio. There is no evidence of perinephric inflammation or effusion. There is no evidence of pyelectasia, nephroliths, infarcts or hydroureter. Renal vasculature is normal.

The right kidney has a normal shape and size (4.37 cm). Overall echogenicity is normal with adequate corticomedullary distinction and a typical 1:3 cortex:medulla ratio. There is no evidence of perinephric inflammation or effusion. There is no evidence of pyelectasia, nephroliths, infarcts or hydroureter. Renal vasculature is normal.

*Adrenal Glands*

The left adrenal gland is normal in size measuring 0.28 cm at the caudal pole. It is observed in its normal position cranial to the left renal artery. It is normal in appearance (uniformly hypoechoic) and shape with no evidence of a mass effect.

The right adrenal gland is normal in size measuring 0.35 cm at the caudal pole. It is observed in its normal position between the cranial aspect of the right kidney and the caudal vena cava. It is normal in appearance (uniformly hypoechoic) and shape with no evidence of a mass effect.

*Spleen*

The spleen is subjectively normal in size, echotexture is homogenous, and the splenic capsule is smooth with no irregularities. The blood flow through the hilus and splenic parenchyma appears normal. No focal parenchymal abnormalities are visualized.

*Liver*

The liver is subjectively normal in size, and echogenicity with smooth peripheral margins. The parenchyma is homogenous echotexture. The visible portions of the vasculature and biliary tract appear normal. No focal nodules or cystic lesions are observed. The gallbladder lumen is moderately distended. The wall of the gallbladder is not thickened and has a smooth mucosal surface. Luminal contents are primarily anechoic. The cystic and common bile ducts are normal/not visible.



**PATIENT**

**Gastrointestinal**

Tolkien Coenung

The stomach contains minimal luminal contents. It measures at a normal thickness of <0.36cm with some variability due to the presence of rugal folds. The distinction of the gastric wall layers is adequate and there is no impression of reduced peristaltic activity. No masses or focal lesions were observed.

**SPECIES**

Feline

The visualized areas of duodenum, jejunum and ileum have a relatively uniform diameter with minimal fluid distension. Wall thickness is normal. Bowel loops follow a curvilinear path with distinct wall layering maintaining the typical 1:3 muscularis:mucosa layer ratio. The duodenum measured as normal (between 0.13-0.38cm in wall thickness) and the jejunum measured as normal (between 0.15-0.36cm.) Visualized peristalsis appears appropriate. There were no focal lesions consistent with obstruction or a mass effect observed.

**BREED**

Domestic Shorthair

**SEX**

Neutered male

The ileocecal junction was visualized and exhibited normal intact wall layering and is subjectively of normal thickness. Sections of colon are visualized with formed fecal material and gas shadowing distally. There is no observed focal or generalized colon wall thickening or loss of layering.

**AGE**

4 years

**Pancreas**

The pancreas is prominent and mottled compared to the surrounding isoechoic mesentery. There is no evidence of nodules or cystic lesions. There is no evidence of regional mesenteric inflammation or fluid.

**WEIGHT**

11 lbs 12 oz

**Free Abdomen**

Evaluation of the peritoneal cavity did not reveal any evidence of effusion, or subjective lymphadenomegaly. The Medial iliac nodes appear normal and there was no evidence of a caudal aortic thrombus at the bifurcation. The omentum is of normal uniform echogenicity.

**INTERPRETED BY**

Kathleen Sennello  
DVM, MS, Diplomate  
ACVIM (Small Animal  
Internal Medicine)

**ULTRASONOGRAPHIC FINDINGS**

**PRIMARY FINDINGS:**

- Prominent, mottled pancreas. The pancreatic changes are most consistent with age-related parenchymal remodeling, potentially secondary to a prior inflammatory episode, early fibrosis or chronic pancreatitis.

**IMAGING PERFORMED BY**

Jessica Miller, RDMS

**HOSPITAL NAME**

Animal Care Center of  
Flanders

**INTERPRETATION OF THE FINDINGS & FURTHER RECOMMENDATIONS**

**REFERRING VET**

Dr. Hallihan

Today's scan is relatively normal. Despite the lab work provided the kidneys appear to have a normal size and shape and a relatively normal architecture. If not already done consider urinalysis, culture, blood pressure measurements and urine protein to creatinine ratio for a baseline.

**INVOICE**

97909

The pancreas appears somewhat prominent, but not overtly inflamed. This can be consistent with a previous episode of pancreatic inflammation. I recommend to continue monitoring of renal values.

Anesthesia should be okay as long as fluid support is provided.

**DATE**

3/29/22



**PATIENT**

Tolkien Coeung

**SPECIES**

Feline

**BREED**

Domestic Shorthair

**SEX**

Neutered male

**AGE**

4 years

**WEIGHT**

11 lbs 12 oz

**INTERPRETED BY**

Kathleen Sennello  
DVM, MS, Diplomate  
ACVIM (Small Animal  
Internal Medicine)

**IMAGING  
PERFORMED BY**

Jessica Miller, RDMS

**HOSPITAL NAME**

Animal Care Center of  
Flanders

**REFERRING VET**

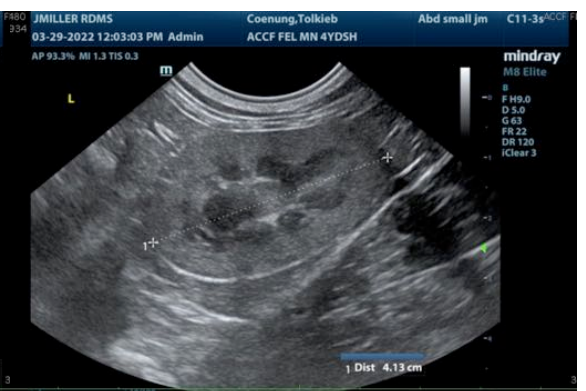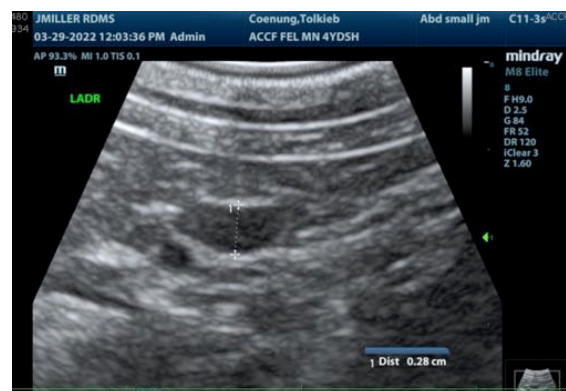
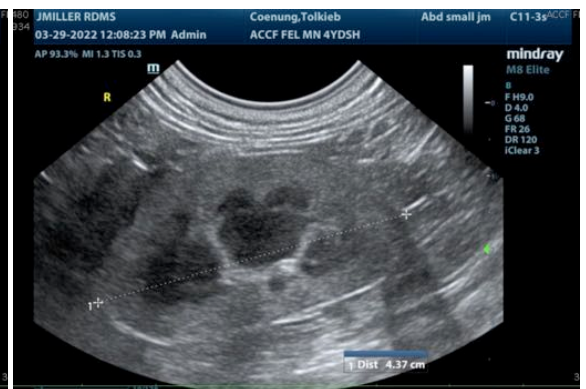
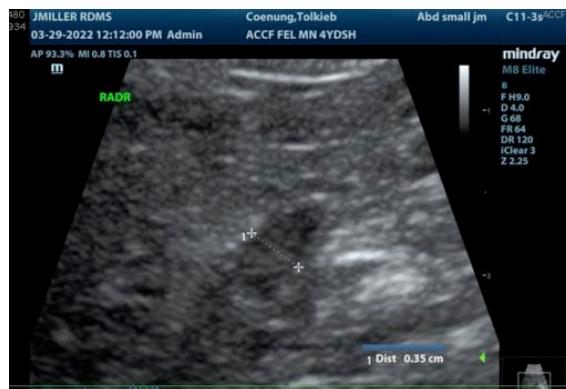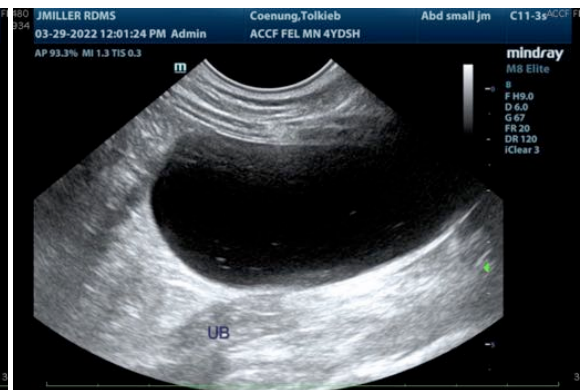
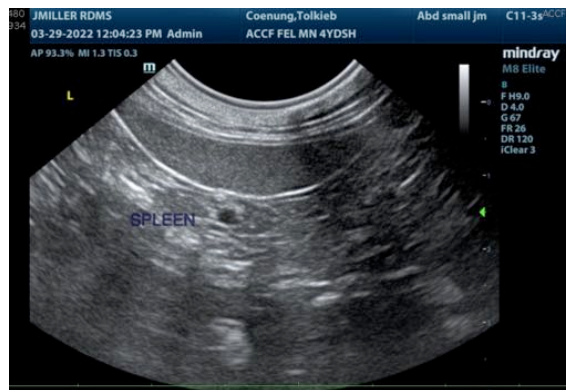
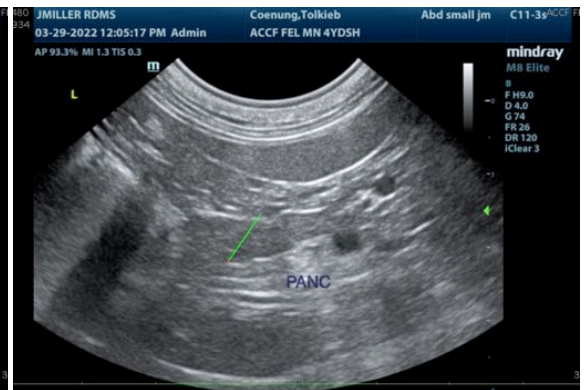
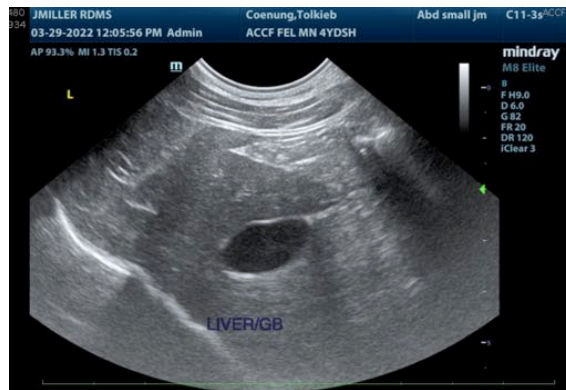Dr. Hallihan

**INVOICE**

97909

**DATE**

3/29/22





**PATIENT**

Tolkien Coenung

The information and recommendations provided are based on the images presented by the referring veterinarian/sonographer. No evaluation can be communicated regarding pathology that was not visible in the image/video clips provided.

**SPECIES**

Feline

Thank you for this referral. If the clinical or image interpretation does not parallel your findings or if I can be of any further assistance please contact me.

**BREED**

Domestic Shorthair

Kathleen Sennello DVM,MS, Diplomate ACVIM (Small animal Internal Medicine)

kathleen.sennello@sonopath.com

**SEX**

Neutered male

**AGE**

4 years

**WEIGHT**

11 lbs 12 oz

**INTERPRETED BY**

Kathleen Sennello  
DVM, MS, Diplomate  
ACVIM (Small Animal  
Internal Medicine)

**IMAGING  
PERFORMED BY**

Jessica Miller, RDMS

**HOSPITAL NAME**

Animal Care Center of  
Flanders

**REFERRING VET**

Dr. Hallihan

**INVOICE**

97909

**DATE**

3/29/22