

**DATE PRESENTING CLINICAL SIGNS**

3/29/22

Patient presents for evaluation - history of DM - went into a remission but recently did relapse (March 2022.) Was doing well on Glargine 2 units BID, but now decreased appetite and energy. Recently has been straining to urinate. Diagnosed with pancreatitis and treated with hospitalization. On D/M diet. Weight is stable, hydration status is very good.

**PATIENT**

Dexter Pollutra

**SPECIES**

Feline

**BREED**

DSH

**SEX**

Neutered Male

**AGE**

6/29/05

**WEIGHT**

16 Pounds

**INTERPRETED BY**

Kathleen Sennello DVM,  
MS, Diplomate ACVIM  
(Small Animal Internal  
Medicine)

**IMAGING PERFORMED BY**

Stephanie Pearce  
RDMS, RVT

**HOSPITAL NAME**

Perry Hall AH

**REFERRING VET**

Dr. Miller

**INVOICE**

36551

Current Medications: Glargine 2 units BID, (note - has not been on recently due to hyporexia, last dose was Saturday 3/26/2022.)

Just started Entyce last PM.

Radiographs: 3 view chest: Moderate diffuse, primary bronchial pulmonary patterns - non-specific. Right midline lung lobe collapse likely due to bronchial plugging Intestinal mineral content likely suggestive of dietary indiscretion, no evidence of mechanical obstruction (abdominal included in rads.) Central contour of the liver is suspected to be due to incidental delineation of the GB, (abdominal included in rads.)

Date of Previous IntraPet Ultrasound: No previous.

Sedation: Not required to complete full diagnostic ultrasound.

Stat Report: Not requested.

**ULTRASONOGRAPHIC EXAMINATION OF THE ABDOMEN****Urinary System**

The urinary bladder is moderately distended with anechoic urine. The Bladder wall is somewhat irregular. There are focal areas of irregular bladder wall thickening involving both the dependent/apical portion of the urinary bladder and near the trigone. The more apical lesion measures 3.5 cm x 1.44 cm. The abnormal area towards the trigone is 1.34 cm x 2.4 cm.

The left kidney has a normal shape and size (4.23 cm) with pyelectasia at 0.38 cm. Overall echogenicity is normal with adequate corticomedullary distinction and a typical 1:3 cortex:medulla ratio. There is no evidence of perinephric inflammation or effusion. There is no evidence of pyelectasia, nephroliths, infarcts or hydroureter. Renal vasculature is normal.

The right kidney has a normal shape and size (4.34 cm) with mild pyelectasia at 0.17 cm. Overall echogenicity is normal with adequate corticomedullary distinction and a typical 1:3 cortex:medulla ratio. There is no evidence of perinephric inflammation or effusion. There is no evidence of pyelectasia, nephroliths, infarcts or hydroureter. Renal vasculature is normal.

**Adrenal Glands**

The left adrenal gland is normal in size measuring 0.46 cm at the caudal pole. It is observed in its normal position cranial to the left renal artery. It is normal in appearance (uniformly hypoechoic) and shape with no evidence of a mass effect.

The right adrenal gland is normal in size measuring 0.46 cm at the caudal pole. It is observed in its normal position between the cranial aspect of the right kidney and the caudal vena cava. It is normal in appearance (uniformly hypoechoic) and shape with no evidence of a mass effect.

**Spleen**

The spleen is subjectively normal in size, echotexture is homogenous, and the splenic capsule is smooth with no irregularities. The blood flow through the hilus and splenic parenchyma appears normal. No focal parenchymal abnormalities are visualized.

### ***Liver***

The liver is large in size with smooth peripheral margins. The parenchyma is hyperechoic and homogenous in echotexture. The visible portions of the vasculature and biliary tract appear normal. No focal nodules or cystic lesions are observed.

The gallbladder lumen is moderately distended. The wall of the gall bladder is not thickened and has a smooth mucosal surface. Luminal contents are primarily anechoic. The cystic and common bile ducts are normal/not visible.

### ***Gastrointestinal***

The stomach contains minimal luminal contents. It measures at a normal thickness of <0.36cm with some variability due to the presence of rugal folds. The distinction of the gastric wall layers is adequate and there is no impression of reduced peristaltic activity. No masses or focal lesions were observed.

The visualized areas of duodenum, jejunum and ileum have a relatively uniform diameter with minimal fluid distension. Wall thickness is normal. Bowel loops follow a curvilinear path with distinct wall layering maintaining the typical 1:3 muscularis:mucosa layer ratio. The duodenum measured as normal (between 0.13-0.38cm in wall thickness) and the jejunum measured as normal (between 0.15-0.36cm.) Visualized peristalsis appears appropriate. There were no focal lesions consistent with obstruction or a mass effect observed.

The ileocecal junction was visualized and exhibited normal intact wall layering and is subjectively of normal thickness. Sections of colon are visualized with formed fecal material and gas shadowing distally. There is no observed focal or generalized colon wall thickening or loss of layering.

### ***Pancreas***

The pancreas is prominent and hypoechoic as compared to the surrounding isoechoic mesentery. There is no evidence of nodules or cystic lesions. There is no evidence of regional mesenteric inflammation or fluid.

### ***Free Abdomen***

Evaluation of the peritoneal cavity did not reveal any evidence of effusion, or subjective lymphadenomegaly. The Medial iliac nodes appear normal and there was no evidence of a caudal aortic thrombus at the bifurcation. The omentum is of normal uniform echogenicity.

## **ULTRASONOGRAPHIC FINDINGS**

- Focal urinary bladder wall irregularities – These changes are concerning for bladder wall mass effects.
- Bilateral renal pyelectasia – Pyelectasia of the left/right kidney could be consistent with pyelonephritis, chronic renal disease, secondary to PU/PD or fluid therapy (if applicable), other.
- Hypoechoic, prominent pancreas – The pancreatic changes are most consistent with mild pancreatitis or a recent episode of pancreatic inflammation.
- Large, hyperechoic liver – Hepatic changes are non-specific and could be consistent with hepatic lipidosis, inflammatory/infectious disease, infiltrative neoplasia, or other hepatopathy. This is likely associated with a diabetic hepatopathy.

## **INTERPRETATION OF THE FINDINGS & FURTHER RECOMMENDATIONS**

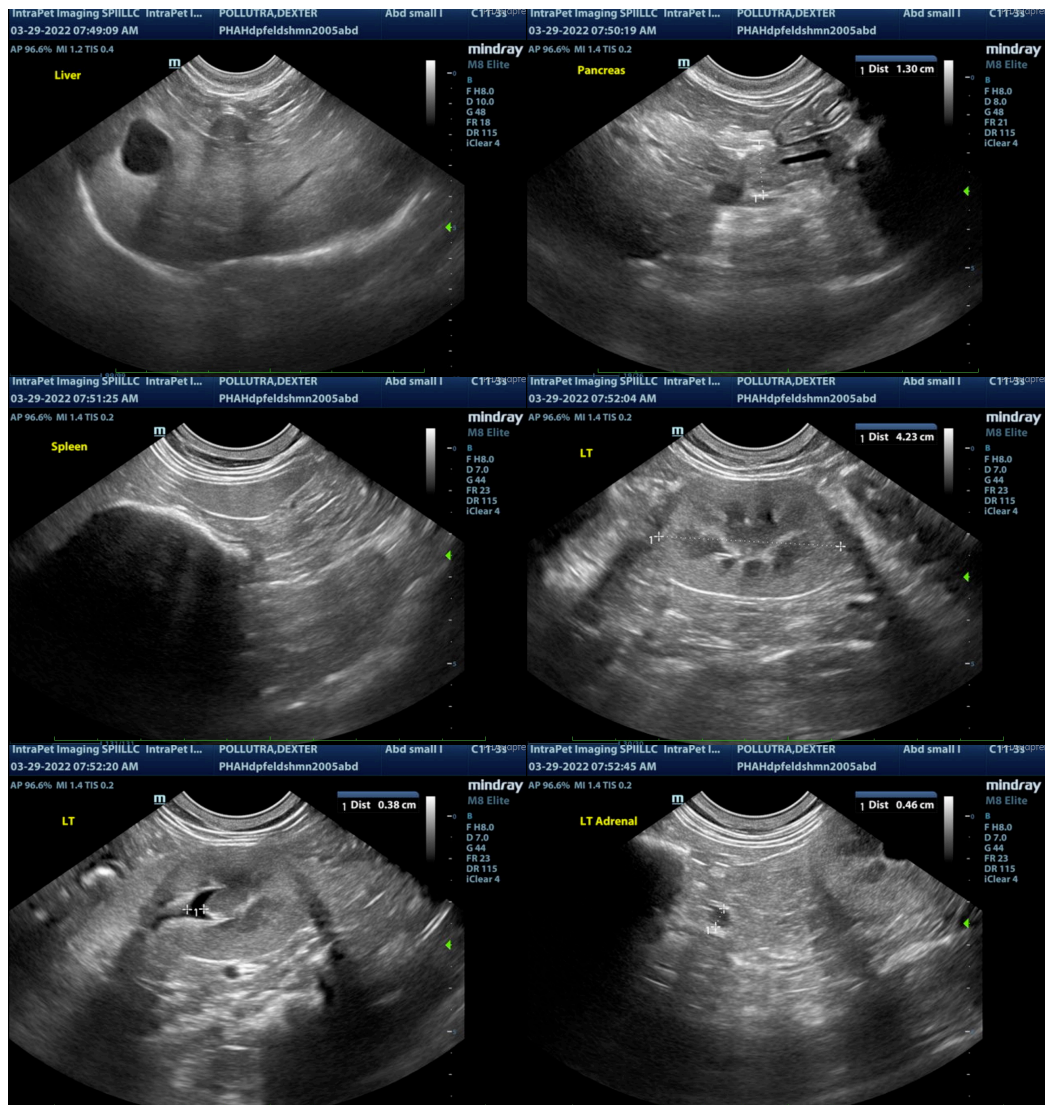
There is focal thickening and irregularity to the urinary bladder wall. Some of this area is located near the trigone region, which I suspect is part of the stranguria reported. Consider a fine needle aspirate of the urinary bladder wall. There is some risk for tracking a neoplasm through the abdomen with this method.

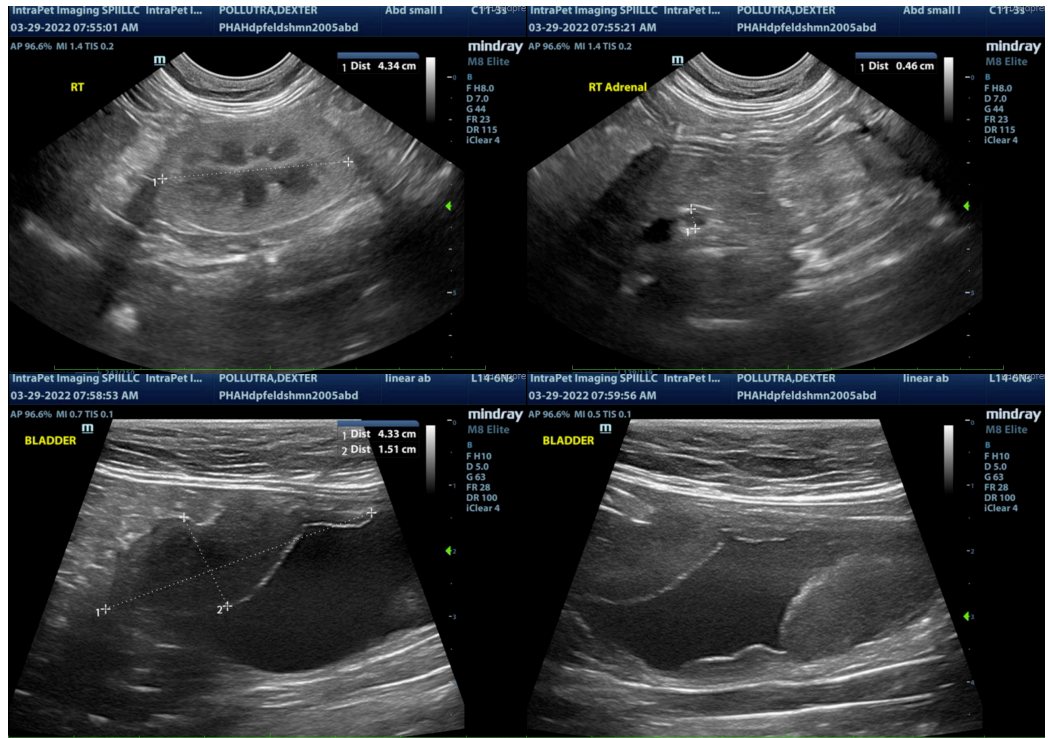
Alternately, a surgical biopsy would likely be necessary. Recommend urinalysis and culture.

Both kidneys have mild/moderate pyelectasia. This could be secondary to a partial obstruction due to the irregularities seen in the urinary bladder, or could be due to secondary infection. Recommend urinalysis and culture as recommended above.

The pancreas appears somewhat hypoechoic. This could be consistent with mild current pancreatitis or a previous episode of pancreatitis. Consider evaluation of a quantitative feline specific pancreatic lipase (Texas A&M University) to further evaluate the pancreas.

Consider three view thoracic radiographs to rule out concurrent thoracic disease/involvement.





The information and recommendations provided are based on the images presented by the referring veterinarian/sonographer. No evaluation can be communicated regarding pathology that was not visible in the image/video clips provided.

Thank you for this referral. If the clinical or image interpretation does not parallel your findings or if I can be of any further assistance please contact me.

Kathleen Sennello DVM,MS, Diplomate ACVIM (Small animal Internal Medicine)  
kathleen.sennello@sonopath.com