



PATIENT

Coco Li

SPECIES

Feline

BREED

Ragdoll Cat

SEX

Spayed Female

AGE

11 Years

WEIGHT

6.34 Pounds

INTERPRETED BY

Kathleen Sennello DVM,
MS, Diplomate ACVIM
(Small Animal Internal
Medicine)

IMAGING PERFORMED BY

Kelly Vazquez

HOSPITAL NAME

Summit Dog & Cat
Hospital

REFERRING VET

Dr. Lepowski

INVOICE

46216

DATE

3/28/23

PRESENTING CLINICAL SIGNS

Prolapsed rectal mucosa twice. On 3/4 issue resolved spontaneously, on 3/23 a reduced purse string was placed. Current meds: Convenia given on 3/23, Lactulose, miralax, and Gabapentin.

Abnormal PE/Chem/CBC/UA Results: At E.R. facility on 3/4 blood work was WNL. U/A: trace protein, RBCs 29/ hpf.

ULTRASONOGRAPHIC EXAMINATION OF THE ABDOMEN

Urinary System

The urinary bladder is moderately distended with anechoic urine. The Bladder wall, trigone, ureteral papillae and visible urethra (to a depth of 2cm) appear normal with no evidence of wall thickening, mucosal irregularities, masses or cystic calculi.

The left kidney has a normal shape and size (3.63 cm). Overall echogenicity is normal with adequate corticomedullary distinction and a typical 1:3 cortex:medulla ratio. There is no evidence of focal perinephric inflammation or effusion. There is no evidence of pyelectasia, nephroliths, infarcts or hydroureter. Renal vasculature is normal.

The right kidney has a normal shape and size (4.04 cm). Overall echogenicity is normal with adequate corticomedullary distinction and a typical 1:3 cortex:medulla ratio. There is no evidence of focal perinephric inflammation or effusion. There is no evidence of pyelectasia, nephroliths, infarcts or hydroureter. Renal vasculature is normal.

Adrenal Glands

The left adrenal gland is normal/borderline large in size measuring 0.54 cm at the caudal pole. It is observed in its normal position cranial to the left renal artery. It is normal in appearance (uniformly hypoechoic) and shape with no evidence of a mass effect.

The right adrenal gland is normal/borderline large in size measuring 0.57 cm at the caudal pole. It is observed in its normal position between the cranial aspect of the right kidney and the caudal vena cava. It is normal in appearance (uniformly hypoechoic) and shape with no evidence of a mass effect.

Spleen

The spleen is subjectively normal in size (0.88 cm), echotexture is homogenous, and the splenic capsule is smooth with no irregularities. The blood flow through the hilus and splenic parenchyma appears normal. No focal parenchymal abnormalities are visualized.

Liver

The liver is subjectively normal in size, and echogenicity with smooth peripheral margins. The parenchyma is homogenous echotexture. The visible portions of the vasculature and biliary tract appear normal. No focal nodules or cystic lesions are observed.

The gallbladder lumen is moderately distended. The wall of the gall bladder is not thickened and has a smooth mucosal surface. Luminal contents are mild and primarily anechoic. The cystic and common bile ducts are normal/not visible.



PATIENT

Coco Li

SPECIES

Feline

BREED

Ragdoll Cat

SEX

Spayed Female

AGE

11 Years

WEIGHT

6.34 Pounds

INTERPRETED BY

Kathleen Sennello DVM,
MS, Diplomate ACVIM
(Small Animal Internal
Medicine)

IMAGING PERFORMED BY

Kelly Vazquez

HOSPITAL NAME

Summit Dog & Cat
Hospital

REFERRING VET

Dr. Lepowski

INVOICE

46216

DATE

3/28/23

Gastrointestinal

The stomach contains moderate fluid. It measures at a normal thickness of <0.36cm with some variability due to the presence of rugal folds. The distinction of the gastric wall layers is adequate and there is no impression of reduced peristaltic activity. No masses or focal lesions were observed.

The visualized areas of duodenum, jejunum and ileum have a relatively uniform diameter with occasional mild/moderate fluid distension. Wall thickness is normal. Bowel loops follow a curvilinear path with distinct wall layering maintaining the typical 1:3 muscularis:mucosa layer ratio. Jejunum wall measures 0.22 cm. Visualized peristalsis appears appropriate. There were no focal lesions consistent with obstruction or a mass effect observed.

The ileocecal junction was visualized and exhibited normal intact wall layering and is subjectively of normal thickness. Sections of colon are visualized with formed fecal material and gas shadowing distally. There is no observed focal or generalized colon wall thickening or loss of layering. Colon wall measures 0.14 cm.

Pancreas

The pancreas is prominent and hypoechoic as compared to the surrounding isoechoic mesentery. There is no evidence of nodules or cystic lesions. There is no evidence of regional mesenteric inflammation or fluid.

Free Abdomen

Evaluation of the peritoneal cavity did not reveal any evidence of effusion, or subjective lymphadenomegaly. The Medial iliac nodes appear normal and there was no evidence of a caudal aortic thrombus at the bifurcation. The omentum is of normal uniform echogenicity.

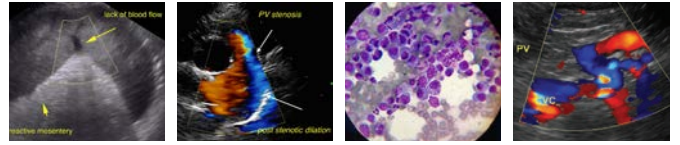
ULTRASONOGRAPHIC FINDINGS

- Prominent, hypoechoic pancreas – The pancreatic changes are most consistent with age-related parenchymal remodeling, potentially secondary to a prior inflammatory episode, early fibrosis or chronic pancreatitis.
- Mild/moderate fluid distention of the stomach and some areas of the small bowel – Correlate these findings with feeding history. If the patient was adequately fasted, consider such differentials as delayed gastric emptying/ileus, less likely an obstructive process.
- Borderline adenomegaly – The significance of the prominent lymph nodes is uncertain. Recommend continued monitoring.

INTERPRETATION OF THE FINDINGS & FURTHER RECOMMENDATIONS

Today's scan is largely normal. If this patient was not fasted, the fluid/ingesta visualized in the stomach and small bowel is likely within normal limits. Additionally, the pancreas is somewhat prominent, but there is minimal surrounding inflammation, and no colonic wall thickening visualized.

There are many potential causes for straining and prolapse that cannot be visualized with ultrasound such as colitis, strictures, parasitism, etc. If the problem persists, consider a colonoscopy to further evaluate and obtain biopsies.



PATIENT

Coco Li

SPECIES

Feline

BREED

Ragdoll Cat

SEX

Spayed Female

AGE

11 Years

WEIGHT

6.34 Pounds

INTERPRETED BY

Kathleen Sennello DVM,
MS, Diplomate ACVIM
(Small Animal Internal
Medicine)

**IMAGING
PERFORMED BY**

Kelly Vazquez

HOSPITAL NAME

Summit Dog & Cat
Hospital

REFERRING VET

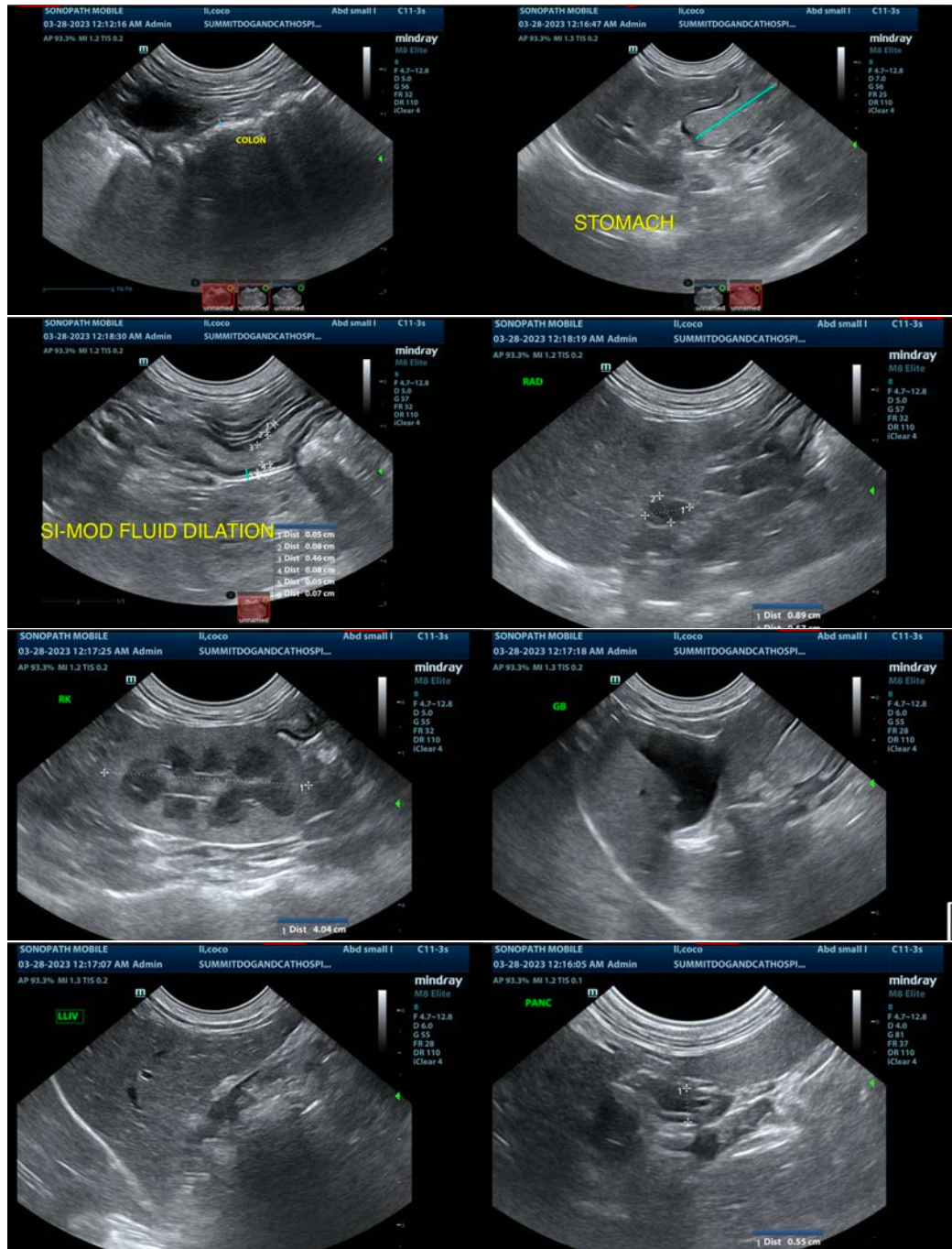
Dr. Lepowski

INVOICE

46216

DATE

3/28/23





PATIENT

Coco Li

SPECIES

Feline

BREED

Ragdoll Cat

SEX

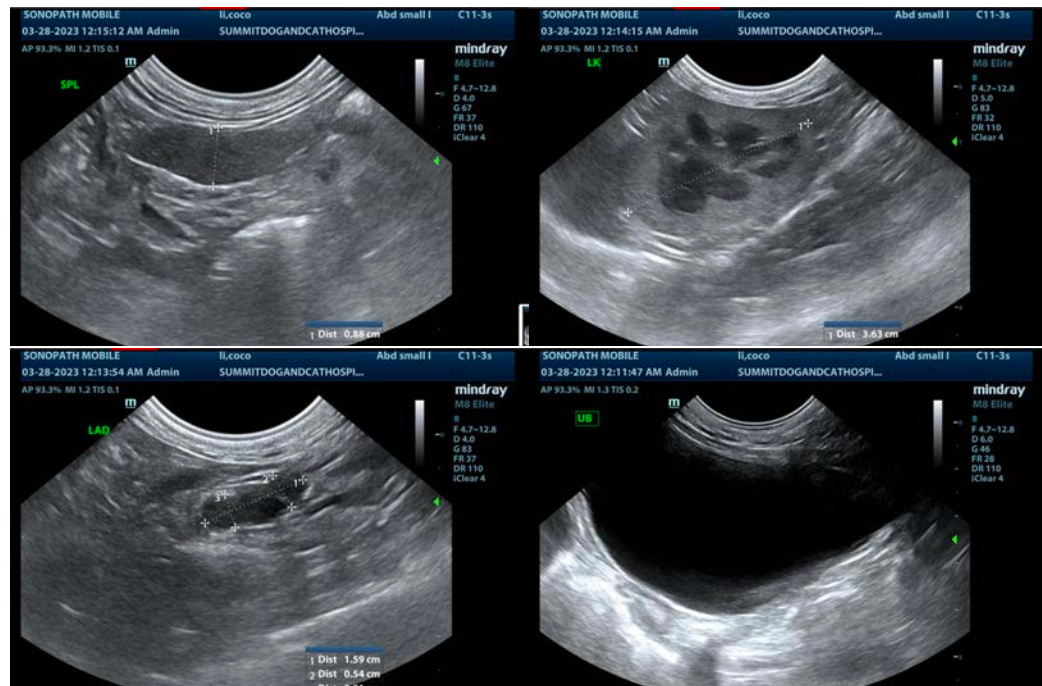
Spayed Female

AGE

11 Years

WEIGHT

6.34 Pounds



INTERPRETED BY

Kathleen Sennello DVM,
MS, Diplomate ACVIM
(Small Animal Internal
Medicine)

The information and recommendations provided are based on the images presented by the referring veterinarian/sonographer. No evaluation can be communicated regarding pathology that was not visible in the image/video clips provided.

Thank you for this referral. If the clinical or image interpretation does not parallel your findings or if I can be of any further assistance please contact me.

IMAGING PERFORMED BY

Kelly Vazquez

Kathleen Sennello DVM,MS, Diplomate ACVIM (Small animal Internal Medicine)

kathleen.sennello@sonopath.com

HOSPITAL NAME

Summit Dog & Cat
Hospital

REFERRING VET

Dr. Lepowski

INVOICE

46216

DATE

3/28/23