



**DATE PRESENTING CLINICAL SIGNS**

3/27/2026 **Patient History:** Continued elevated liver values.

**PATIENT**

Maron Rupert Ong

**Current Medications:** Denamarin Advanced Large Canine Bottle - Instructions: Give 0.25 chewable tablets every 24 hours until gone.

**SPECIES**

Canine

**Labwork Results:** Labwork not attached, reported as: CBC/IOF - ALKP 716, ALT 1684, BUN 54 (3/18/26) IOF/CBC- elevated ALKP, ALT, BUN (4/2/25)

**BREED**

Schnauzer

**Date of Previous IntraPet Ultrasound:** 12/30/24. See attached.

**Sedation:** Not required to complete full diagnostic ultrasound.

**Stat Report:** Not requested.

**SEX**

MN

**Imaging Performed by:** Rachel Brillhart, RDMS.

**AGE**

13 years

**ULTRASONOGRAPHIC EXAMINATION OF THE ABDOMEN**

**Urinary System**

The urinary bladder is moderately distended with anechoic urine. The Bladder wall, trigone, ureteral papillae and visible urethra (to a depth of 2cm) appear normal with no evidence of wall thickening, mucosal irregularities, masses or cystic calculi.

**WEIGHT**

12.4 lbs

The prostate is normal in size (0.77 cm) and shape for this neutered male dog. The parenchyma is homogenous and the external margins are smooth. The prostatic urethra appears normal with no evidence of irregularity, invasion, mass effect or calculi.

**INTERPRETED BY**

Kathleen Sennello DVM,  
MS, Diplomate ACVIM  
(Small Animal Internal  
Medicine)

The left kidney has a normal shape and size (4.55 cm). Overall echogenicity is normal with adequate corticomedullary distinction and a typical 1:3 cortex:medulla ratio. There is no evidence of focal perinephric inflammation or effusion. Occasional cortical mineralizations noted. There is no evidence of pyelectasia, infarcts or hydroureter. Renal vasculature is normal.

**HOSPITAL NAME**

Banfield Timonsium

The right kidney has a normal shape and size (4.19 cm). Overall echogenicity is normal with adequate corticomedullary distinction and a typical 1:3 cortex:medulla ratio. There is no evidence of focal perinephric inflammation or effusion. Occasional cortical mineralizations noted. There is no evidence of pyelectasia, infarcts or hydroureter. Renal vasculature is normal.

**REFERRING VET**

Dr. Borrison

**Adrenal Glands**

**INVOICE**

11572

The left adrenal gland is plump in size measuring 0.69 cm at the cranial pole and 0.8 cm at the caudal pole (previous 12/24 was 0.65 cm at the cranial pole and 0.73 cm at the caudal pole). It is observed in its normal position cranial to the left renal artery. It is normal in appearance (uniformly hypoechoic) and shape with no evidence of a mass effect.

The right adrenal gland is borderline plump in size measuring 0.67 cm at the cranial pole and 0.72 cm at the caudal pole. It is observed in its normal position between the cranial aspect of the right kidney and the

caudal vena cava. It is normal in appearance (uniformly hypoechoic) and shape with no evidence of a mass effect.

### ***Spleen***

The spleen is subjectively normal in size (0.98 cm) and the echotexture is homogenous. The splenic capsule is smooth with no visible irregularities. The blood flow through the hilus and splenic parenchyma appears normal. No focal parenchymal abnormalities are visualized. The splenic confirmation is slightly curled. The previously described isoechoic nodule is not clearly visualized on today's exam.

### ***Liver***

The liver is large in size, and rounded. The parenchyma is heterogenous in echotexture with subtle, indistinct focal mottling. The visible portions of the vasculature and biliary tract appear normal. No focal nodules or cystic lesions are observed.

The gall bladder lumen is moderately distended. The wall of the gall bladder is not thickened and has a smooth mucosal surface. There is a moderate amount of non-organized echogenic debris. The cystic and common bile ducts are normal/not visible.

### ***Gastrointestinal***

The stomach contains minimal luminal contents. It measures at a normal thickness of <0.7cm with some variability due to the presence of rugal folds. The distinction of the gastric wall layers is adequate and there is no impression of reduced peristaltic activity. No masses or focal lesions were observed.

The visualized areas of duodenum (0.48 cm), jejunum (0.3 cm) and ileum have a uniform diameter with minimal fluid distension. Wall appears subjectively, mildly increased. Bowel loops follow a typical curvilinear path with distinct wall layering. There is mild mucosal speckling visualized associated with the small intestine. Visualized peristalsis appears appropriate. There were no focal lesions consistent with obstruction or a mass effect observed.

Sections of colon are visualized with formed fecal material and gas shadowing distally. There is no observed focal or generalized colon wall thickening or loss of layering.

### ***Pancreas***

The pancreas is visible/mildly mottled in the right limb. There is no evidence of nodules or cystic lesions. There is no evidence of regional mesenteric inflammation or fluid.

### ***Free Abdomen***

Evaluation of the peritoneal cavity did not reveal any evidence of effusion, or subjective lymphadenomegaly. The Medial iliac nodes appear normal and there was no evidence of a caudal aortic thrombus at the bifurcation. The omentum is of normal uniform echogenicity.

## **PRIMARY FINDINGS**

- Borderline plump adrenals. Findings could be consistent with anatomic variation, or hyperplasia. The appearance is similar to the previous exam.

- Large, rounded heterogenous liver. The diffuse hepatic changes are non-specific and could be consistent with vacuolar hepatopathy, nodular hyperplasia, inflammatory/immune-mediated disease, infiltrative neoplasia (less likely) or other hepatopathy.
- Moderate gallbladder debris. The significance of the aggregated gallbladder debris is unclear. This could represent an early mucocele, cholestasis, or may be secondary to fasting but seems unlikely to be causing a current issue. Recommend continued monitoring.
- Prominent/mildly thickened small intestine with mild mucosal speckling visualized associated with the duodenum. Bright mucosal speckling has been postulated to represent dilated lacteals or focal accumulations of mucus, cellular debris, etc.. in the mucosal crypts.

## **SECONDARY FINDINGS**

- Bilateral mineralizations/non-obstructive nephroliths visualized associated with both kidneys. Hyperechoic foci are visualized in the kidney most consistent with nephroliths. There is no current evidence of obstructive disease. Correlate findings with abdominal radiographs, urinalysis, and culture. Continued monitoring is warranted for progression/obstruction.
- Pancreatic changes consistent with chronic pancreatic remodeling.

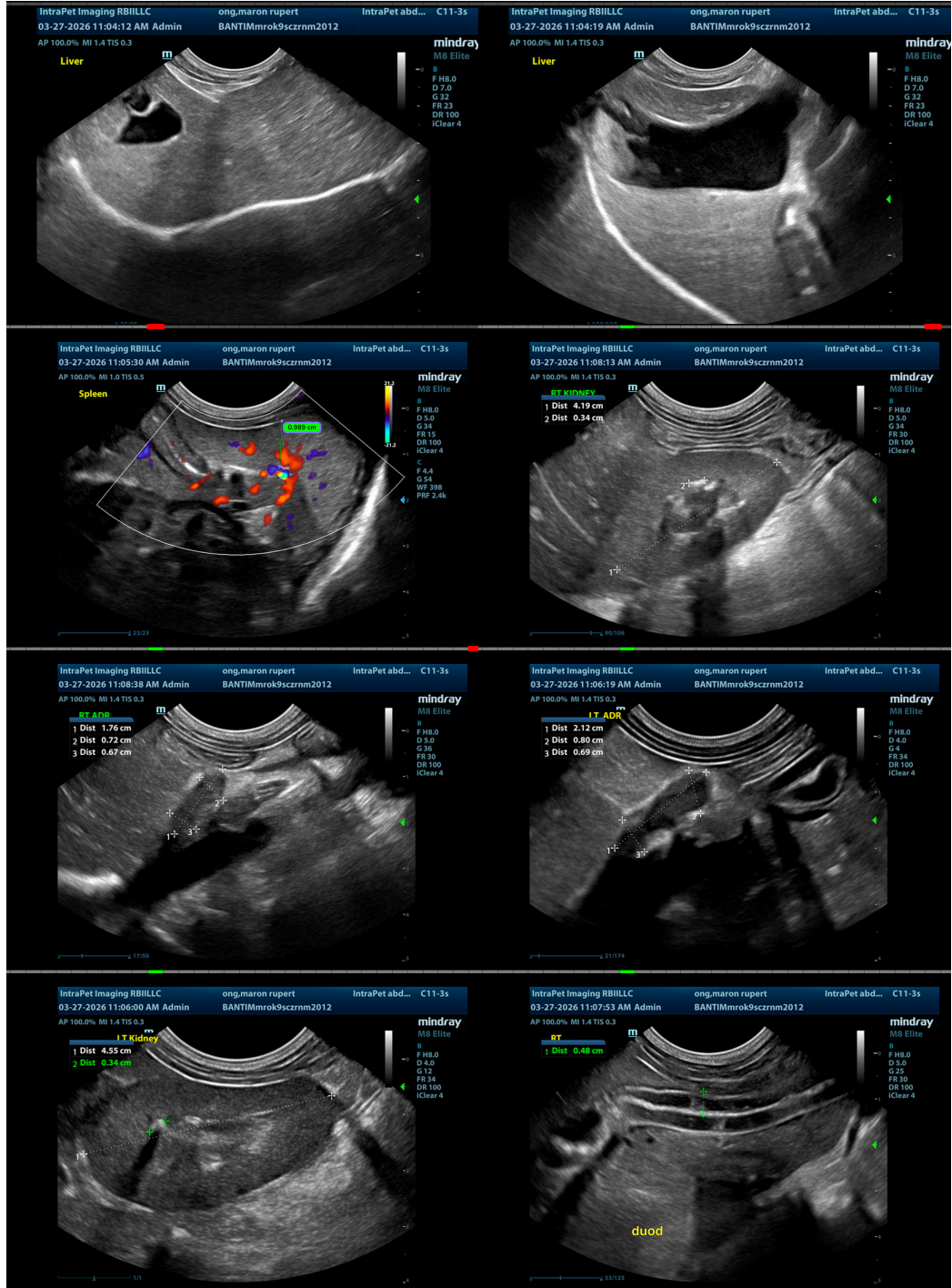
## **INTERPRETATION OF THE FINDINGS & FURTHER RECOMMENDATIONS**

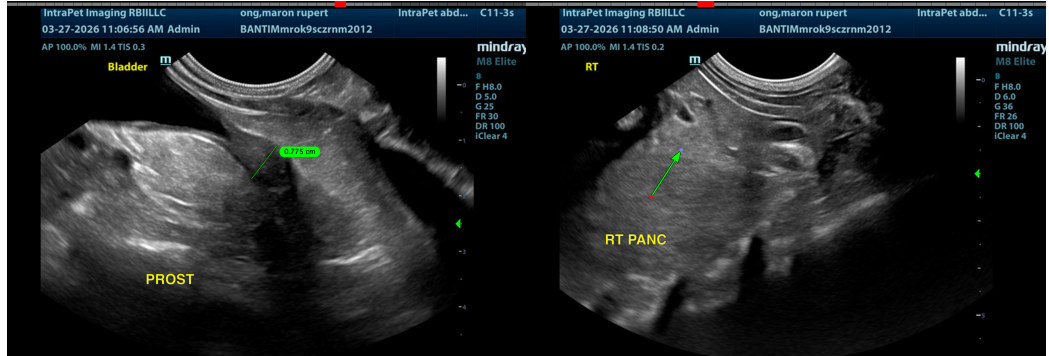
Both adrenals appear somewhat plump. The left adrenal is slightly irregular, but no focal lesions are observed. Findings are likely most consistent with hyperplasia. Recommend continued monitoring of both adrenals.

The liver is large and heterogenous with no distinctive focal lesions observed. The general appearance could be consistent with a vacuolar hepatopathy although the enzyme profile (ALT greater than ALP) is not classic or there could be a concurrent hepatopathy present. Recommend a liver function test (pre- and post-prandial bile acids and a fine needle aspirate of the liver.) Additionally, if symptoms consistent with Cushing's are present you could consider adrenal function testing. Ultimately, if liver enzymes continue to rise and/or liver function is abnormal, biopsies of the liver may be necessary (histopathology, culture, and copper levels, to further evaluate.)

There's a moderate amount of gallbladder debris but no evidence of significant wall thickening or pathology. Ursodiol therapy could be considered out of the utmost of caution.

There is very mild mucosal speckling visualized associated with the duodenum. The significance of this in the absence of underlying gastrointestinal disease is uncertain. Recommend continued monitoring.





The information and recommendations provided are based on the images presented by the referring veterinarian/sonographer. No evaluation can be communicated regarding pathology that was not visible in the image/video clips provided.

Thank you for this referral. If the clinical or image interpretation does not parallel your findings or if I can be of any further assistance please contact me.

Kathleen Sennello DVM,MS, Diplomate ACVIM (Small animal Internal Medicine)  
info@sonopath.com