

**DATE PRESENTING CLINICAL SIGNS**

3/26/26

**Patient History:** Has been in and out since October 2025 for GI upset, vomiting and persistent soft stool diarrhea. Labs show no obvious reasons, want to pursue ultrasound. Has lost ten pound since this started in October and a total of 15 pounds since 09/2024. Fecal tests and CPL all negative

**PATIENT**

Apollo Klein

**Current Medications:** Metamucil, tylan, proviable, metronidazole (off now)

**Labwork Results:** Labwork attached, reported as: Chem - SDMA 16.8 (<14), BUN 9 (6-31), creatinine 0.8 (0.5-1.6)

**SPECIES**

Canine

**Date of Previous IntraPet Ultrasound:** No previous.

**Sedation:** Not required to complete full diagnostic ultrasound.

**Stat Report:** Not requested.

**Imaging Performed by:** Stephanie Warga RDCS, RVT.

**BREED**

Husky

**ULTRASONOGRAPHIC EXAMINATION OF THE ABDOMEN****SEX**

Neutered Male

**Urinary System**

The urinary bladder is moderately distended with anechoic urine. The Bladder wall, trigone, ureteral papillae and visible urethra (to a depth of 2cm) appear normal with no evidence of wall thickening, mucosal irregularities, masses or cystic calculi.

**AGE**

9/19/14

The prostate is normal in size (1.38 cm) and shape for this neutered male dog. The parenchyma is homogenous and the external margins are smooth. The prostatic urethra appears normal with no evidence of irregularity, invasion, mass effect or calculi.

**WEIGHT**

49.4 lbs

The left kidney has a normal shape and size (6.87 cm). Overall echogenicity is slightly hyperechoic with mildly reduced corticomedullary distinction and a typical 1:3 cortex:medulla ratio. There is no evidence of focal perinephric inflammation or effusion. There is no evidence of pyelectasia, nephroliths, infarcts or hydroureter. Renal vasculature is normal.

**INTERPRETED BY**

Kathleen Sennello DVM,  
MS, Diplomate ACVIM  
(Small Animal Internal  
Medicine)

The right kidney has a normal shape and size (5.27 cm) with occasional cortical mineralizations. Overall echogenicity is slightly hyperechoic with mildly reduced corticomedullary distinction and a typical 1:3 cortex:medulla ratio. There is no evidence of focal perinephric inflammation or effusion. There is no evidence of pyelectasia, infarcts or hydroureter. Renal vasculature is normal.

**HOSPITAL NAME**

Docside Veterinary  
Medical Center

**Adrenal Glands**

The left adrenal gland is normal in size measuring 0.45 cm at the cranial pole and 0.42 cm at the caudal pole. It is observed in its normal position cranial to the left renal artery. It is normal in appearance (uniformly hypoechoic) and shape with no evidence of a mass effect.

**REFERRING VET**

Dr. Vaughan

The right adrenal gland is normal in size measuring 0.61 cm at the cranial pole and 0.49 cm at the caudal pole. It is observed in its normal position between the cranial aspect of the right kidney and the caudal vena cava. It is normal in appearance (uniformly hypoechoic) and shape with no evidence of a mass effect.

**INVOICE**

74064

**Spleen**

The spleen is subjectively normal in size (2.57 cm), echotexture is homogenous, and the splenic capsule is smooth with no irregularities. The blood flow through the hilus and splenic parenchyma appears normal. No focal parenchymal abnormalities are visualized.

### **Liver**

The liver is subjectively normal in size, and echogenicity with smooth peripheral margins. The parenchyma is mildly heterogenous in echotexture with subtle, indistinct focal mottling. The visible portions of the vasculature and biliary tract appear normal. No focal nodules or cystic lesions are observed.

The gall bladder lumen is significantly distended. Some areas of the wall appear mildly thickened with adherent debris. There is a large amount of primarily non-organized echogenic debris. There is no evidence of bile duct dilation.

### **Gastrointestinal**

The stomach contains moderate gas. It measures at a normal thickness of 0.28 cm with some variability due to the presence of rugal folds. The distinction of the gastric wall layers is adequate and there is no impression of reduced peristaltic activity. Intraluminal gas interferes with full evaluation of the stomach. This is likely secondary to excessive vocalization.

The visualized areas of duodenum, jejunum and ileum have a relatively uniform diameter with minimal fluid distension. Wall thickness is normal. Bowel loops follow a curvilinear path with distinct wall layering maintaining the typical 1:3 muscularis:mucosa layer ratio. Duodenum wall measures 0.49 cm. Jejunum wall measures 0.27 cm. Visualized peristalsis appears appropriate. There were no focal lesions consistent with obstruction or a mass effect observed.

The ileocecal junction was visualized and exhibited normal intact wall layering and is subjectively of normal thickness. Sections of colon are visualized with formed fecal material and gas shadowing distally. The descending colon wall is somewhat prominent, measuring at 0.42 cm with intact wall layering.

### **Pancreas**

The area of the pancreas is normal and isoechoic to surrounding mesentery. There is no evidence of nodules or cystic lesions. There is no evidence of regional mesenteric inflammation or fluid.

### **Free Abdomen**

Evaluation of the peritoneal cavity did not reveal any evidence of effusion. There is no significant lymphadenopathy. A prominent iliac lymph node is visualized measuring 0.54 cm. A mesenteric lymph node is visualized measuring 0.38 cm. The omentum is normal echogenicity.

## **ULTRASONOGRAPHIC FINDINGS**

- Mild age related changes visualized associated with both kidneys.
- Heterogeneous liver – The diffuse hepatic changes are non-specific and could be consistent with vacuolar hepatopathy, nodular hyperplasia, inflammatory/immune-mediated disease, fibrosis, extramedullary hematopoiesis, toxic hepatopathy (e.g., copper), infiltrative neoplasia (less likely) or other hepatopathy. The significance of this is uncertain in the absence of liver enzyme elevations.
- Large gallbladder debris – The appearance may be exacerbated by a fasting state. Recommend continued monitoring +/- Ursodiol therapy.
- Occasional prominent/likely reactive mesenteric lymph nodes.

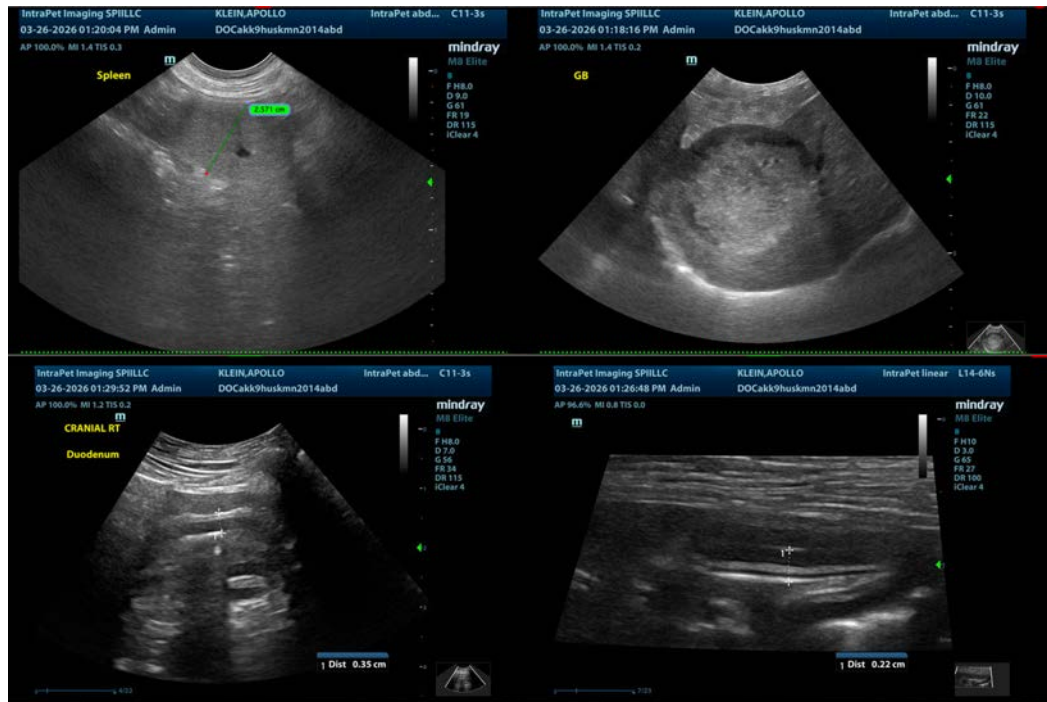
## INTERPRETATION OF THE FINDINGS & FURTHER RECOMMENDATIONS

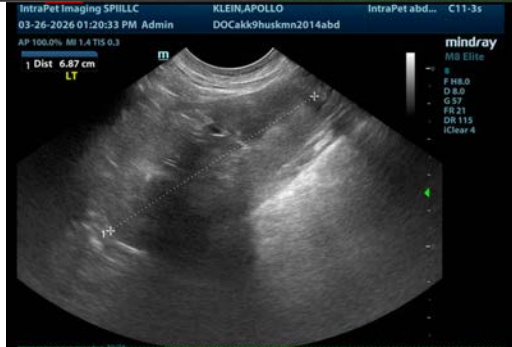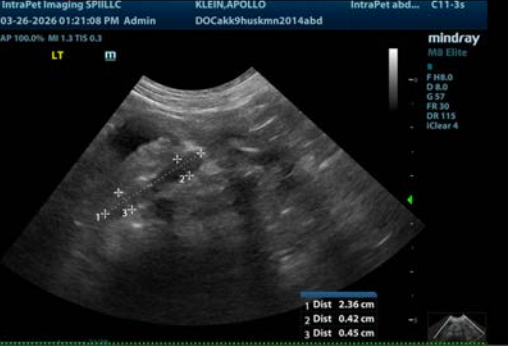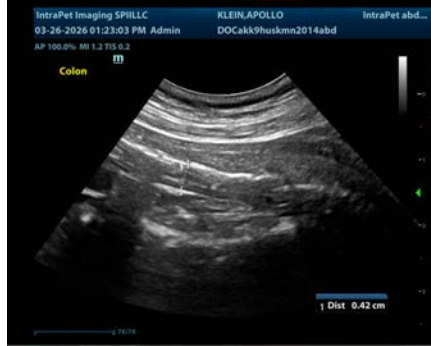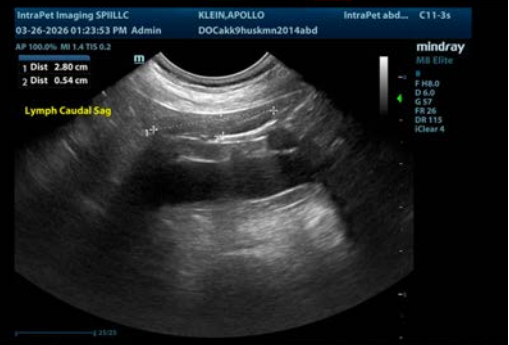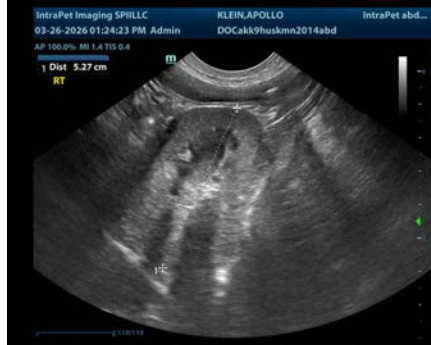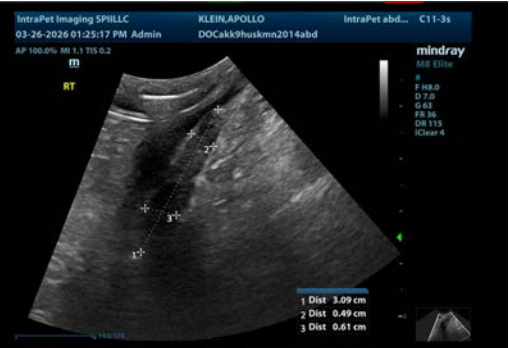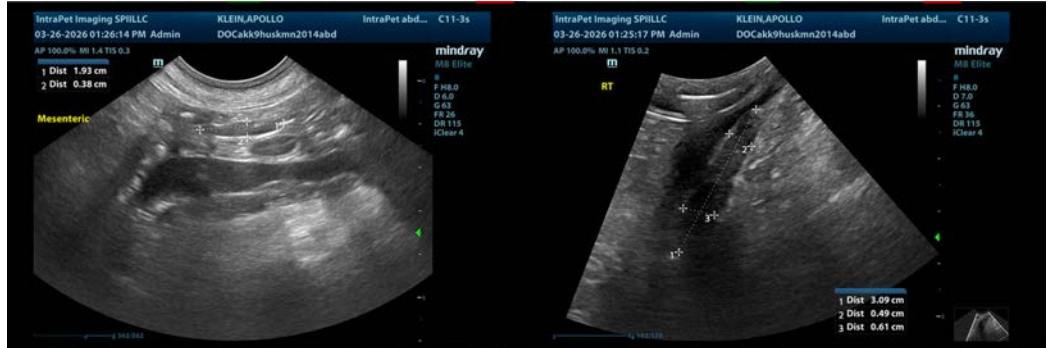
No significant lesions are visualized associated with the GI tract to explain the vomiting and diarrhea reported, although a small focal lesion cannot be definitively ruled out. Unfortunately, there are many causes for these symptoms that cannot be definitively diagnosed by ultrasound alone. Consider the following:

- Consider a novel protein/hydrolyzed protein diet (exclusively at least 4-6 weeks)
- Consider a GI panel to Texas A&M for evaluation of B12 levels, folate, PLI/TLI etc.. to further evaluate for pancreatic/small intestinal disease.
- Recommend chronic probiotic therapy.

Consider a panel looking for infectious causes of chronic diarrhea.

Based on the severity and chronicity of the symptoms reported, ultimately biopsies of the GI tract will likely be necessary for further evaluation.





**The information and recommendations provided are based on the images presented by the referring veterinarian/sonographer. No evaluation can be communicated regarding pathology that was not visible in the image/video clips provided.**

Thank you for this referral. If the clinical or image interpretation does not parallel your findings or if I can be of any further assistance please contact me.

Kathleen Sennello DVM,MS, Diplomate ACVIM (Small animal Internal Medicine)  
info@sonopath.com