



PATIENT

Scout Phillips

SPECIES

Canine

BREED

Labrador Retriever x

SEX

Spayed Female

AGE

7 Years

WEIGHT

84.2lbs

INTERPRETED BY

Kathleen Sennello DVM,
MS, Diplomate ACVIM
(Small Animal Internal
Medicine)

IMAGING PERFORMED BY

Meghan Myers, VMD

HOSPITAL NAME

Hershire Animal
Hospital

REFERRING VET

Companion Animal
Hospital

INVOICE

73988

DATE

3/25/26

PRESENTING CLINICAL SIGNS

Referral for AUS due to chronically mildly increased liver enzymes. 2/20/26: alt 352, alp 279 ast 61. X-rays at that time unremarkable. Trial of denamarin and Clavamox. Repeat labwork 3/12/26: alt 608. Ursodiol added and referred for ultrasound.

ULTRASONOGRAPHIC EXAMINATION OF THE ABDOMEN

Urinary System

The urinary bladder is moderately distended with anechoic urine. The Bladder wall, trigone, ureteral papillae and visible urethra (to a depth of 2cm) appear normal with no evidence of wall thickening, mucosal irregularities, masses or cystic calculi.

The left kidney has a normal shape and size (7.06 cm). Overall echogenicity is normal with adequate corticomedullary distinction and a typical 1:3 cortex:medulla ratio. There is no evidence of focal perinephric inflammation or effusion. There is no evidence of pyelectasia, nephroliths, infarcts or hydroureter. Renal vasculature is normal.

The right kidney has a normal shape and size (6.42 cm). Overall echogenicity is normal with adequate corticomedullary distinction and a typical 1:3 cortex:medulla ratio. There is no evidence of focal perinephric inflammation or effusion. There is no evidence of pyelectasia, nephroliths, infarcts or hydroureter. Renal vasculature is normal.

Adrenal Glands

The left adrenal gland is "plump" measuring 0.90 cm at the cranial pole and 0.87 cm at the caudal pole. It is observed in its normal position cranial to the left renal artery. It is normal in appearance (uniformly hypoechoic) and shape with no evidence of a mass effect.

The right adrenal gland is normal/borderline "plump" measuring 0.77 cm at the cranial pole and 0.83 cm at the caudal pole. It is observed in its normal position between the cranial aspect of the right kidney and the caudal vena cava. It is normal in appearance (uniformly hypoechoic) and shape with no evidence of a mass effect.

Spleen

The spleen is subjectively normal in size (2.23 cm), echotexture is homogenous, and the splenic capsule is smooth with no irregularities. The blood flow through the hilus and splenic parenchyma appears normal. No focal parenchymal abnormalities are visualized.

Liver

The liver is subjectively normal in size, and echogenicity with smooth peripheral margins. The parenchyma is heterogenous in echotexture with subtle, indistinct focal mottling. The visible portions of the vasculature and biliary tract appear normal. No focal nodules or cystic lesions are observed.

The gall bladder lumen is moderately distended. The wall of the gall bladder is not thickened and has a smooth mucosal surface. Luminal contents are mild and likely incidental at this time. The cystic and common bile ducts are normal/not visible.



PATIENT

Scout Phillips

SPECIES

Canine

BREED

Labrador Retriever x

SEX

Spayed Female

AGE

7 Years

WEIGHT

84.2lbs

INTERPRETED BY

Kathleen Sennello DVM,
MS, Diplomate ACVIM
(Small Animal Internal
Medicine)

IMAGING PERFORMED BY

Meghan Myers, VMD

HOSPITAL NAME

Hershire Animal
Hospital

REFERRING VET

Companion Animal
Hospital

INVOICE

73988

DATE

3/25/26

Gastrointestinal

The stomach contains minimal luminal contents. It measures at a normal thickness of <0.7cm with some variability due to the presence of rugal folds. The distinction of the gastric wall layers is adequate and there is no impression of reduced peristaltic activity. No masses or focal lesions were observed.

The visualized areas of duodenum, jejunum and ileum have a relatively uniform diameter with minimal fluid distension. Wall thickness is normal. Bowel loops follow a curvilinear path with distinct wall layering maintaining the typical 1:3 muscularis:mucosa layer ratio. Duodenum wall measures 0.54 cm. Jejunum wall measures 0.37 cm. Visualized peristalsis appears appropriate. There were no focal lesions consistent with obstruction or a mass effect observed.

Sections of colon are visualized with formed fecal material and gas shadowing distally. There is no observed focal or generalized colon wall thickening or loss of layering.

Pancreas

The area of the pancreas is normal and isoechoic to surrounding mesentery. There is no evidence of nodules or cystic lesions. There is no evidence of regional mesenteric inflammation or fluid.

Free Abdomen

Evaluation of the peritoneal cavity did not reveal any evidence of effusion, or subjective lymphadenomegaly. The Medial iliac nodes appear normal and there was no evidence of a caudal aortic thrombus at the bifurcation. The omentum is of normal uniform echogenicity.

ULTRASONOGRAPHIC FINDINGS

- Borderline “plump” adrenal glands – Findings could be consistent with anatomic variation or early hyperplasia.
- Heterogeneous liver – The diffuse hepatic changes are non-specific and could be consistent with vacuolar hepatopathy, nodular hyperplasia, inflammatory/immune-mediated disease, fibrosis, extramedullary hematopoiesis, toxic hepatopathy (e.g., copper), infiltrative neoplasia (less likely) or other hepatopathy.

INTERPRETATION OF THE FINDINGS & FURTHER RECOMMENDATIONS

The liver appears heterogeneous. No focal lesions are visualized. This is a non-specific change that could be consistent with a vacuolar hepatopathy, inflammatory or infectious disease, even early infiltrative neoplasia (seems unlikely). The adrenals are somewhat “plump” but this is a large dog, so it could be normal for this individual. If symptoms consistent with Cushing’s disease are present, consider adrenal function testing. Additionally, there could be concern for a smoldering hepatitis. If left untreated/undiagnosed, these can sometimes progress to significant liver dysfunction. Consider pre- and post-prandial bile acids and potentially biopsies of the liver with samples for histopathology, culture and copper levels (provided coagulation parameters are normal).



PATIENT

Scout Phillips

SPECIES

Canine

BREED

Labrador Retriever x

SEX

Spayed Female

AGE

7 Years

WEIGHT

84.2lbs

INTERPRETED BY

Kathleen Sennello DVM,
MS, Diplomate ACVIM
(Small Animal Internal
Medicine)

**IMAGING
PERFORMED BY**

Meghan Myers, VMD

HOSPITAL NAME

Hershire Animal
Hospital

REFERRING VET

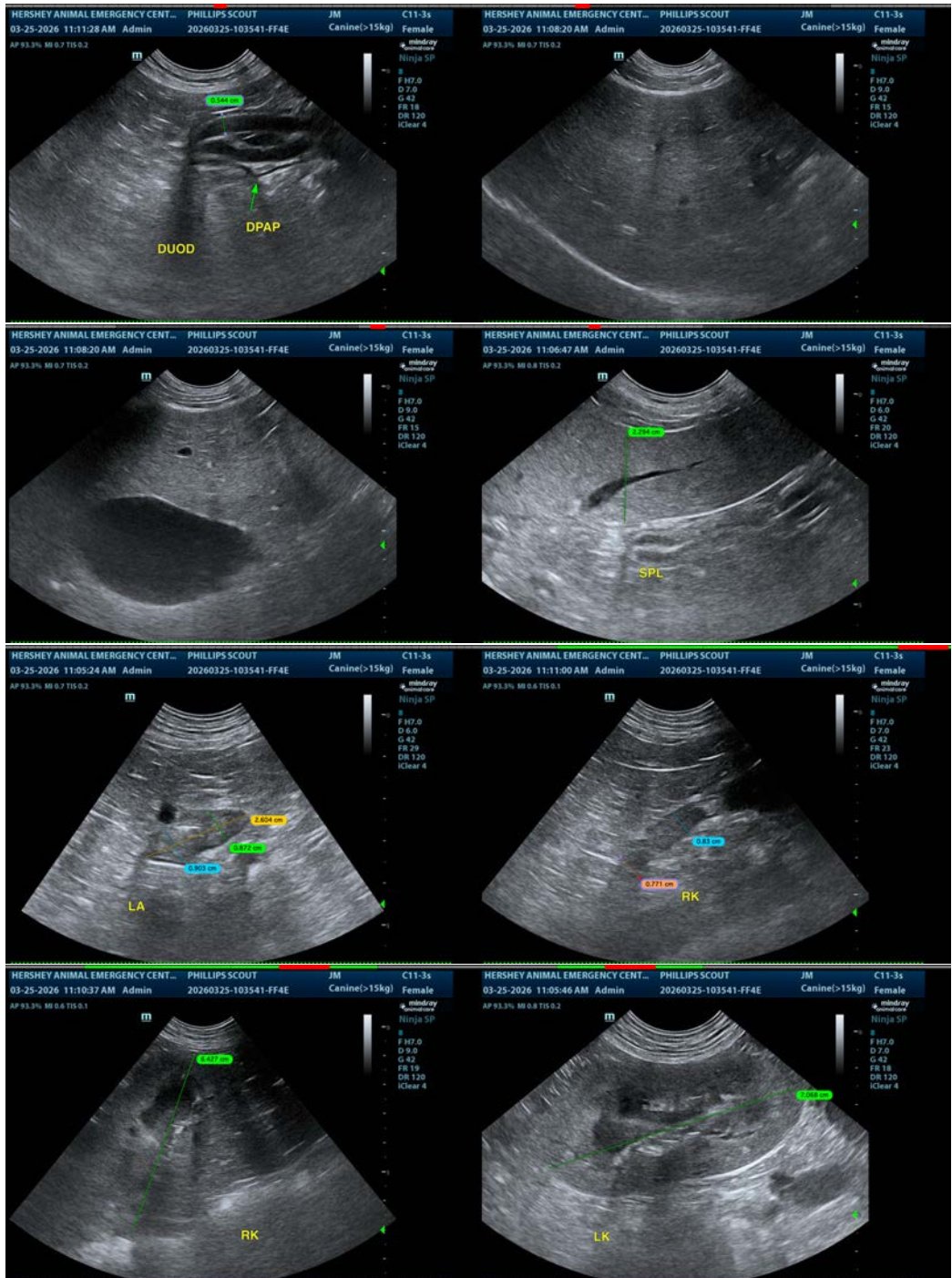
Companion Animal
Hospital

INVOICE

73988

DATE

3/25/26





PATIENT

Scout Phillips

SPECIES

Canine

BREED

Labrador Retriever x

SEX

Spayed Female

AGE

7 Years

WEIGHT

84.2lbs

INTERPRETED BY

Kathleen Sennello DVM,
MS, Diplomate ACVIM
(Small Animal Internal
Medicine)

IMAGING PERFORMED BY

Meghan Myers, VMD

HOSPITAL NAME

Hershire Animal
Hospital

REFERRING VET

Companion Animal
Hospital

INVOICE

73988

DATE

3/25/26

The information and recommendations provided are based on the images presented by the referring veterinarian/sonographer. No evaluation can be communicated regarding pathology that was not visible in the image/video clips provided.

Thank you for this referral. If the clinical or image interpretation does not parallel your findings or if I can be of any further assistance please contact me.

Kathleen Sennello DVM,MS, Diplomate ACVIM (Small animal Internal Medicine)

info@sonopath.com