



PATIENT

Jax MacFarlane-Mitchell

SPECIES

Canine

BREED

Boxer x St. Bernard

SEX

Neutered Male

AGE

10 Years

WEIGHT

35.4kg

INTERPRETED BY

Kathleen Sennello DVM,
 MS, Diplomate ACVIM
 (Small Animal Internal
 Medicine)

IMAGING PERFORMED BY

Amanda Stewart

HOSPITAL NAME

Main Street
 Animal Hospital

REFERRING VET

Dr. Morris

INVOICE

73991

DATE

3/25/26

PRESENTING CLINICAL SIGNS

Examined Feb. 17/26 as concerns about increased appetite and weight loss, licking at penis. It was noted that BCS was a 4/9 with muscle wasting along spine, crepitus on flexion of both stifles, delayed proprioceptive reflexes both hind limbs, no abnormalities around penis or prepuce. Bloodwork and urinalysis performed (see results): r/o liver disease, Cushings, neoplasia. Recommended LDDST, radiographs and ultrasound. Low Dose Dexamethasone Suppression Test performed March 17/26 to r/o Cushings (see results, not Cushings). Ultrasound recommended as next step

Current Medications: Gabapentin 400mg BID, Metacam SID, Librela once monthly

Abnormal PE/Chem/CBC/UA Results: See attached BW Primary Question to Be Answered in This Exam Cause of abnormal labwork values, cholangiohepatitis? neoplasia?

ULTRASONOGRAPHIC EXAMINATION OF THE ABDOMEN

Urinary System

The urinary bladder is moderately distended with anechoic urine. The Bladder wall, trigone, ureteral papillae and visible urethra (to a depth of 2cm) appear normal with no evidence of wall thickening, mucosal irregularities, masses or cystic calculi.

The prostate is normal in size (1.03 cm) and shape for this neutered male dog. The parenchyma is homogenous and the external margins are smooth. The prostatic urethra appears normal with no evidence of irregularity, invasion, mass effect or calculi.

The left kidney has a normal shape and size (7.8cm) with occasional cortical cysts. Overall echogenicity is slightly hyperechoic with mildly reduced corticomedullary distinction and a typical 1:3 cortex:medulla ratio. There is no evidence of focal perinephric inflammation or effusion. There is no evidence of pyelectasia, nephroliths, infarcts or hydroureter. Renal vasculature is normal.

The right kidney has a normal shape and size (7.98 cm) with numerous cortical cysts. A large cortical cyst in the caudal pole measures 2.97 cm x 3.32 cm. Overall echogenicity is slightly hyperechoic with mildly reduced corticomedullary distinction and a typical 1:3 cortex:medulla ratio. There is no evidence of focal perinephric inflammation or effusion. There is no evidence of pyelectasia, nephroliths, infarcts or hydroureter. Renal vasculature is normal.

Adrenal Glands

The left adrenal gland is normal in size measuring 0.53 cm at the cranial pole and 0.54 cm at the caudal pole. It is observed in its normal position cranial to the left renal artery. It is normal in appearance (uniformly hypoechoic) and shape with no evidence of a mass effect.

The region of the right adrenal (between right cranial kidney and vena cava) is unremarkable, but the adrenal is not distinctly visualized. No evidence of a mass effect is visualized.

Spleen

The spleen is large, irregular and mottled. The blood flow through the hilus and splenic parenchyma appears normal. There is a very large, mixed echogenicity, hyperechoic mass effect visualized measuring 6.41 cm x 10.19 cm. Additionally there is a smaller hypoechoic nodule in the parenchyma measuring 1.78 cm x 0.98 cm.



PATIENT

Jax MacFarlane-Mitchell

SPECIES

Canine

BREED

Boxer x St. Bernard

SEX

Neutered Male

AGE

10 Years

WEIGHT

35.4kg

INTERPRETED BY

Kathleen Sennello DVM,
 MS, Diplomate ACVIM
 (Small Animal Internal
 Medicine)

IMAGING PERFORMED BY

Amanda Stewart

HOSPITAL NAME

Main Street
 Animal Hospital

REFERRING VET

Dr. Morris

INVOICE

73991

DATE

3/25/26

Liver

The liver is large in size and irregular in shape. The parenchyma is heterogenous in echotexture with subtle, indistinct focal mottling. The visible portions of the vasculature and biliary tract appear normal. There is a very large, mixed echogenicity, hypoechoic mass effect arising from the right side of the liver measuring 7.07 cm x 9.62 cm. Additionally, there is a mass effect in the left cranial abdomen, most consistent with a hepatic mass lesion, measuring 3.56 cm x 5.14 cm. Splenic origin cannot be ruled out.

The gall bladder lumen is moderately distended. The wall of the gall bladder is not thickened and has a smooth mucosal surface. Luminal contents are mild and likely incidental at this time. The cystic and common bile ducts are normal/not visible.

Gastrointestinal

The stomach contains moderate fluid and gas. It measures at a normal thickness of 0.64 cm with some variability due to the presence of rugal folds. The distinction of the gastric wall layers is adequate and there is no impression of reduced peristaltic activity. No masses or focal lesions were observed.

The visualized areas of duodenum, jejunum and ileum have a relatively uniform diameter with minimal fluid distension. Wall thickness is normal. Bowel loops follow a curvilinear path with distinct wall layering maintaining the typical 1:3 muscularis:mucosa layer ratio. Duodenum wall measures 0.38 cm. Jejunum wall measures 0.40 cm. Visualized peristalsis appears appropriate. There were no focal lesions consistent with obstruction or a mass effect observed.

Sections of colon are visualized with formed fecal material and gas shadowing distally. There is no observed focal or generalized colon wall thickening or loss of layering.

Pancreas

The area of the pancreas is normal and isoechoic to surrounding mesentery. There is no evidence of nodules or cystic lesions. There is no evidence of regional mesenteric inflammation or fluid.

Free Abdomen

Evaluation of the peritoneal cavity did not reveal any evidence of effusion, or subjective lymphadenomegaly. The Medial iliac nodes appear normal and there was no evidence of a caudal aortic thrombus at the bifurcation. The omentum is of normal uniform echogenicity.

ULTRASONOGRAPHIC FINDINGS

- Large, hyperechoic, mixed echogenicity splenic mass lesion with a hypoechoic nodule in the spleen with mottled parenchyma – A focal solid mixed echogenicity mass is visualized associated with the spleen. This mass distorts the splenic capsule. Differentials include: benign lesions (lymphoid hyperplasia, hemangioma etc..) or cancerous lesions (hemangiosarcoma, lymphoma, histiocytic sarcoma etc..)
- Large, heterogeneous liver with a large, hypoechoic right-sided mass lesion and a suspected smaller left hypoechoic mass lesion – The diffuse hepatic changes are non-specific and could be consistent with vacuolar hepatopathy, nodular hyperplasia, inflammatory/immune-mediated disease, fibrosis, extramedullary hematopoiesis, toxic hepatopathy (e.g., copper), infiltrative neoplasia (less likely) or other hepatopathy. The hypoechoic lesions have the appearance most consistent with primary hepatic mass lesions such as adenoma or carcinoma. Metastatic lesions



PATIENT

Jax MacFarlane-Mitchell

SPECIES

Canine

BREED

Boxer x St. Bernard

SEX

Neutered Male

AGE

10 Years

WEIGHT

35.4kg

INTERPRETED BY

Kathleen Sennello DVM,
 MS, Diplomate ACVIM
 (Small Animal Internal
 Medicine)

IMAGING PERFORMED BY

Amanda Stewart

HOSPITAL NAME

Main Street
 Animal Hospital

REFERRING VET

Dr. Morris

INVOICE

73991

DATE

3/25/26

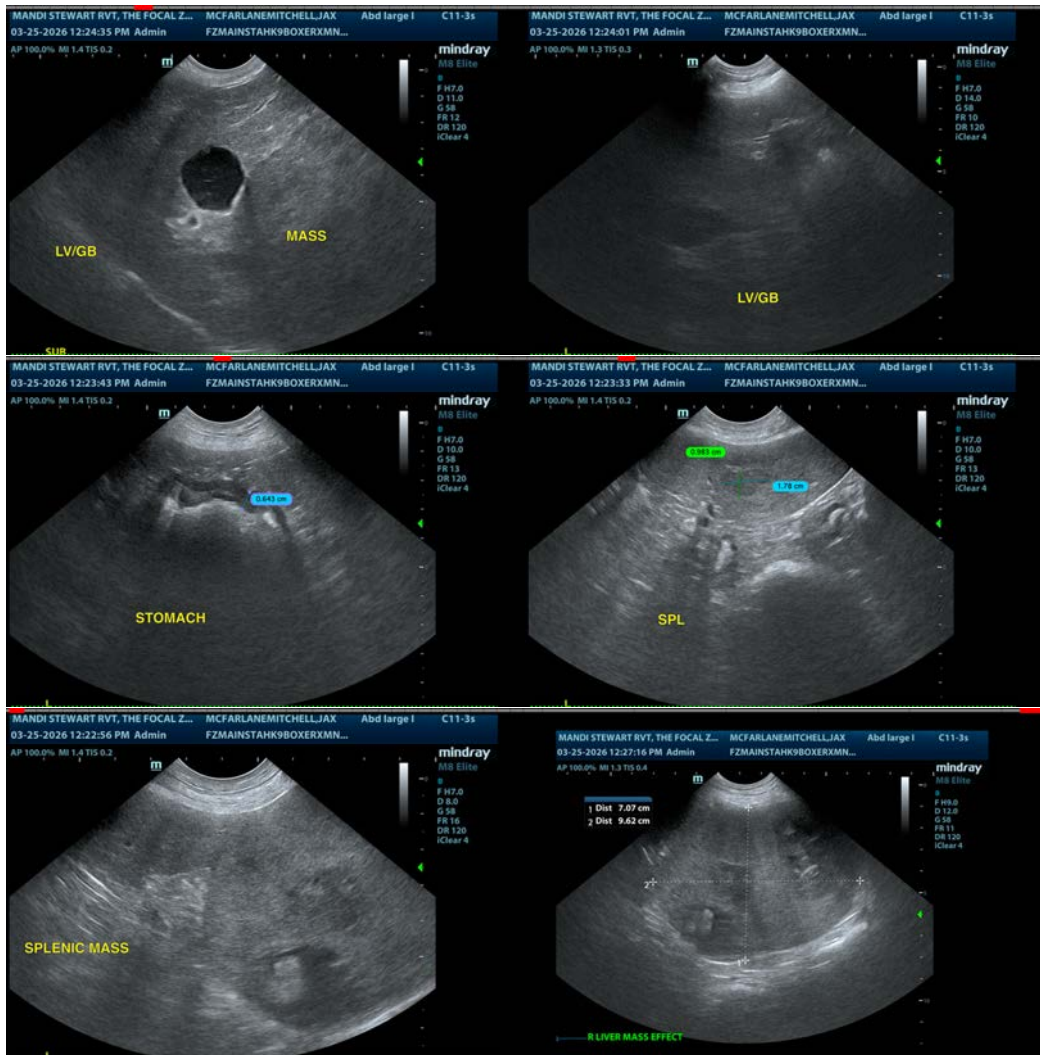
are possible.

- Age related changes visualized associated with both kidneys.

INTERPRETATION OF THE FINDINGS & FURTHER RECOMMENDATIONS

There is a large splenic mass lesion and two suspected hepatic mass lesions. These could represent benign or neoplastic processes and could represent different disease processes. Options moving forward could include a fine needle aspirate of these lesions or a contrast CT scan to further evaluate for possible surgical planning.

Recommend three view thoracic radiographs to evaluate for possible concurrent thoracic disease/involvement (disregard if this has already been done).





PATIENT

Jax MacFarlane-Mitchell

SPECIES

Canine

BREED

Boxer x St. Bernard

SEX

Neutered Male

AGE

10 Years

WEIGHT

35.4kg

INTERPRETED BY

Kathleen Sennello DVM,
 MS, Diplomate ACVIM
 (Small Animal Internal
 Medicine)

IMAGING PERFORMED BY

Amanda Stewart

HOSPITAL NAME

Main Street
 Animal Hospital

REFERRING VET

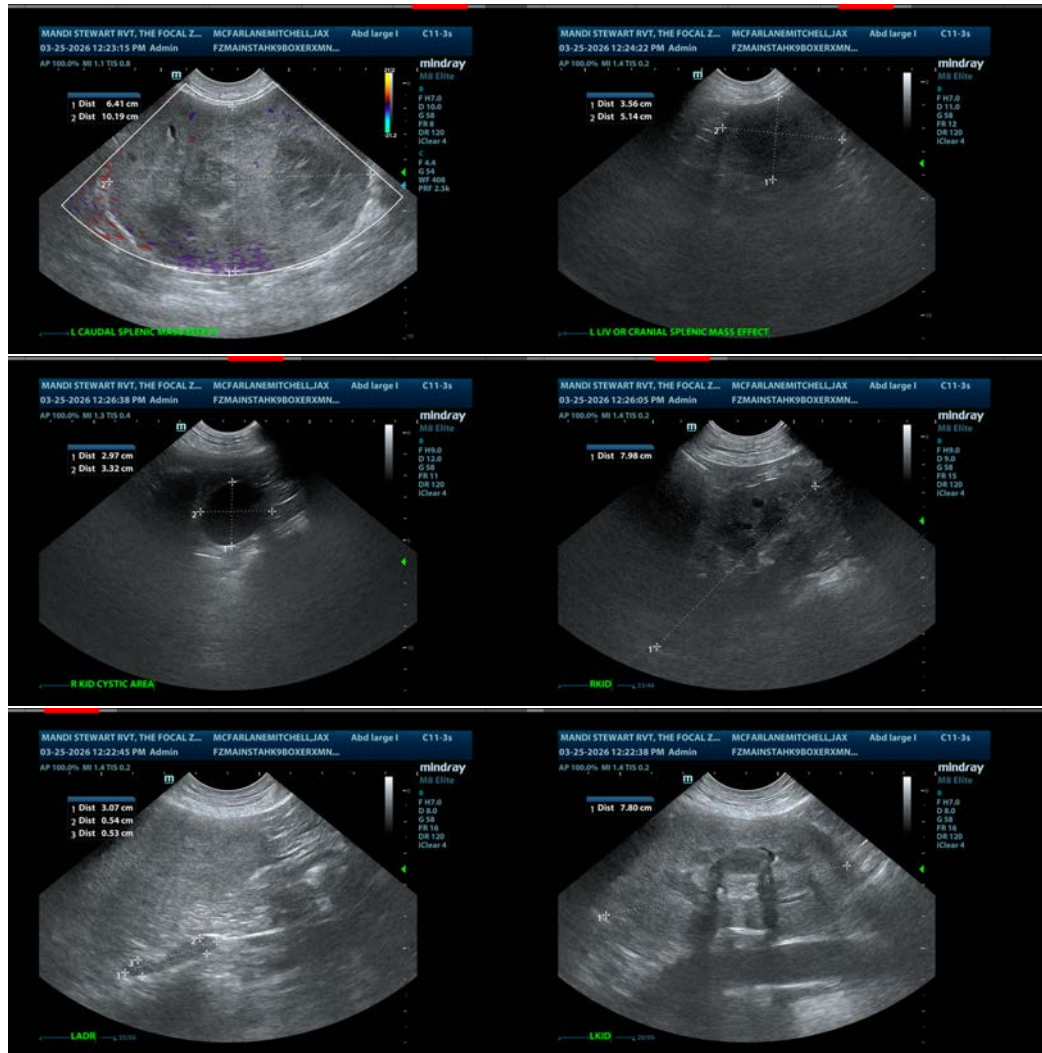
Dr. Morris

INVOICE

73991

DATE

3/25/26



The information and recommendations provided are based on the images presented by the referring veterinarian/sonographer. No evaluation can be communicated regarding pathology that was not visible in the image/video clips provided.

Thank you for this referral. If the clinical or image interpretation does not parallel your findings or if I can be of any further assistance please contact me.

Kathleen Sennello DVM,MS, Diplomate ACVIM (Small animal Internal Medicine)

info@sonopath.com