



PATIENT

Epi Samalgalski

SPECIES

Canine

BREED

Lab Retriever x

SEX

Spayed Female

AGE

10 Years

WEIGHT

29.6 kg

INTERPRETED BY

Kathleen Sennello DVM,
MS, Diplomate ACVIM
(Small Animal Internal
Medicine)

IMAGING PERFORMED BY

Carlie Kolttek, RVT

HOSPITAL NAME

Tuxedo Animal
Hospital

REFERRING VET

Dr. Hickling

INVOICE

73990

DATE

3/25/26

PRESENTING CLINICAL SIGNS

Presented to rDVM March 18th for progressive and worsening hesitation to eat (since February). Vomited bile and food 3 times last week. Good energy, happy. No diarrhea. Owner reports dark yellow urine. March 25th - owner reports Epi is "a new dog last few days" and has seen improvement

Abnormal PE/Chem/CBC/UA Results: PE: Grade 2/6 heart murmur, no pain on abd palpation Worn/fractured teeth (appears chronic) Jaundiced on March 25th, medical record reports pink MM on March 18th CBC: RBC $5.5 \times 10^9/L$ (5.8-8.5) MCV 81fL (66-75) MCH 25pg (21-25) MCHC 310g/L (321-360) RDW 16.2% (11-14) Retics $172 \times 10^9/L$ (<80) Segs $2.6 \times 10^9/L$ (2.9-10.6) CHEM: Anion Gap 25mmol/L (13-24) CA 2.38mmol/L (2.5-3) AMYL 1324u/l (299-947) ALKP 1752u/l(22-143) Steroid ALKP 549u/l (0-84) GGT 38u/l (0-7) TBIL 44umol/l (0-4) Unconj Bili 9umol/l (0-3) Conj Bili 35umol/l (0-1) ALT 170u/l (19-107) CHOL 10.63mmol/L (3.6-10.2) ALB 28g/l (29-43) 1+ icteric sample, slight hemolysis Abd rads:hepatomegaly and splenomegaly Urinalysis: USG 1.039, 3+bili, 2+ prot, NSF sedi - some transitional cell clumps.

ULTRASONOGRAPHIC EXAMINATION OF THE ABDOMEN

Urinary System

The urinary bladder is moderately distended with anechoic urine. The Bladder wall appears mildly thickened with a hyperechoic mucosa, measuring 0.56 cm in the apical region. The region of the trigone, ureteral papillae and proximal urethra appear free of any mass lesions or calculi.

The left kidney was not clearly visualized.

The right kidney has a normal shape and size (5.84 cm). Overall echogenicity is normal with adequate corticomedullary distinction and a typical 1:3 cortex:medulla ratio. There is no evidence of focal perinephric inflammation or effusion. There is no evidence of pyelectasia, nephroliths, infarcts or hydroureter. Renal vasculature is normal.

Adrenal Glands

The left adrenal gland is normal in size measuring 0.56 cm at the cranial pole and 0.53 cm at the caudal pole. It is observed in its normal position cranial to the left renal artery. It is normal in appearance (uniformly hypoechoic) and shape with no evidence of a mass effect.

The right adrenal gland is normal in size measuring 0.44 cm at the cranial pole and 0.60 cm at the caudal pole. It is observed in its normal position between the cranial aspect of the right kidney and the caudal vena cava. It is normal in appearance (uniformly hypoechoic) and shape with no evidence of a mass effect.

Spleen

The spleen is subjectively large, measuring 2.57 cm in width at the level of the hilus. The spleen echotexture is mottled, the splenic capsule is smooth with no irregularities. The blood flow through the hilus and splenic parenchyma appears normal. There is a poorly defined hypoechoic nodule in the parenchyma measuring 0.99 cm x 0.80 cm.



PATIENT

Epi Samalgalski

SPECIES

Canine

BREED

Lab Retriever x

SEX

Spayed Female

AGE

10 Years

WEIGHT

29.6 kg

INTERPRETED BY

Kathleen Sennello DVM,
MS, Diplomate ACVIM
(Small Animal Internal
Medicine)

IMAGING PERFORMED BY

Carlie Kolttek, RVT

HOSPITAL NAME

Tuxedo Animal
Hospital

REFERRING VET

Dr. Hickling

INVOICE

73990

DATE

3/25/26

Liver

The liver is large in size, and normal in echogenicity with smooth peripheral margins. The parenchyma is heterogenous in echotexture with subtle, indistinct focal mottling. The visible portions of the vasculature and biliary tract appear normal. There is a small cystic structure in the left liver measuring 0.92 cm.

The gall bladder lumen is significantly distended. The gallbladder wall appears slightly hyperechoic and prominent with some adherent debris. There is a large amount of primarily non-organized echogenic debris. The common bile duct is not clearly visualized.

Gastrointestinal

The stomach contains minimal luminal contents. It measures at a normal thickness of <0.7cm with some variability due to the presence of rugal folds. The distinction of the gastric wall layers is adequate and there is no impression of reduced peristaltic activity. No masses or focal lesions were observed.

The visualized areas of duodenum, jejunum and ileum have a relatively uniform diameter with minimal fluid distension. Wall thickness is normal. Bowel loops follow a curvilinear path with distinct wall layering maintaining the typical 1:3 muscularis:mucosa layer ratio. Duodenum wall measures 0.53 cm. Jejunum wall measures 0.31 cm. Visualized peristalsis appears appropriate. There were no focal lesions consistent with obstruction or a mass effect observed.

Sections of colon are visualized with formed fecal material and gas shadowing distally. There is no observed focal or generalized colon wall thickening or loss of layering.

Pancreas

The pancreas is normal and isoechoic to surrounding mesentery. There is no evidence of nodules or cystic lesions. There is no evidence of regional mesenteric inflammation or fluid.

Free Abdomen

Evaluation of the peritoneal cavity did not reveal any evidence of effusion, or subjective lymphadenomegaly. The Medial iliac nodes appear normal and there was no evidence of a caudal aortic thrombus at the bifurcation. The omentum is of normal uniform echogenicity.

ULTRASONOGRAPHIC FINDINGS

- Thickened apical wall of the urinary bladder with a prominent muscularis – The bladder mucosal changes could be consistent with cystitis or artifactual due to lack of adequate luminal distension. Bladder neoplasia cannot be ruled out but is considered unlikely in this patient.
- Subjectively large, mottled spleen with a hypoechoic nodule – The diffuse splenic changes are non-specific and could be consistent with lymphoid hyperplasia, extramedullary hematopoiesis, infiltrative neoplasia, inflammation, other. Cytology or histopathology would be necessary to get a definitive diagnosis. The focal hypoechoic nodule could represent a benign or focal neoplastic lesion.
- Heterogeneous liver with a small cystic structure – The diffuse hepatic changes are non-specific and could be consistent with vacuolar hepatopathy, nodular hyperplasia, inflammatory/immune-mediated disease, fibrosis, extramedullary hematopoiesis, toxic



PATIENT

hepatopathy (e.g., copper), infiltrative neoplasia (less likely) or other hepatopathy.

Epi Samalgalski

- Large gallbladder debris with prominent gallbladder wall – The significance of these changes are uncertain but could be consistent with mild cholecystitis.

SPECIES

Canine

BREED

Lab Retriever x

SEX

Spayed Female

AGE

10 Years

WEIGHT

29.6 kg

INTERPRETED BY

Kathleen Sennello DVM,
MS, Diplomate ACVIM
(Small Animal Internal
Medicine)

IMAGING PERFORMED BY

Carlie Koltek, RVT

HOSPITAL NAME

Tuxedo Animal
Hospital

REFERRING VET

Dr. Hickling

INVOICE

73990

DATE

3/25/26

INTERPRETATION OF THE FINDINGS & FURTHER RECOMMENDATIONS

The liver changes are somewhat non-specific, and the gallbladder has some debris and a mildly thickened wall, but not definitive severe disease. Based on these findings it is still difficult to say if this is a primary hepatopathy, hepatobiliary disease, or possibly a component of hemolysis (regenerative anemia, etc.). Further evaluation will be necessary to evaluate. Recommend the following:

- Recommend pre- and post-prandial bile acids to assess liver function.
- Recommend fine needle aspirate of the liver (provided coagulation parameters are normal).
- Consider pathologist review of a blood smear.
- Recommend empirical treatment for cholecystitis with Ursodiol, Denamarin, and a course of antibiotics.
- If hemolysis is strongly suspected, consider testing for vector borne diseases, and look for evidence of autoimmune disease on your pathologist review.
- Additionally consider screening for Leptospirosis.

If the ionized calcium is reported as elevated, consider an ionized calcium PTH/PTHrP level.

Albumin levels are low. If liver function is normal, consider evaluation of urine to assess for excess urine protein loss (urine protein to creatinine ratio). Unfortunately, a focal gastrointestinal lesion cannot be definitively ruled out based on today's exam, so this would be a persistent consideration as a cause for the anemia and low albumin level.

Recommend a fine needle aspirate of the spleen, as it appears somewhat mottled and large on today's exam.

If symptoms are progressive despite further evaluation and treatment, you could consider repeat imaging, looking for the progression of today's lesion. Ideally recommend sedation to help with patient motion, panting artifact, etc.

Recommend three view thoracic radiographs to evaluate for possible concurrent thoracic disease/involvement (disregard if this has already been done).



PATIENT

Epi Samalgalski

SPECIES

Canine

BREED

Lab Retriever x

SEX

Spayed Female

AGE

10 Years

WEIGHT

29.6 kg

INTERPRETED BY

Kathleen Sennello DVM,
MS, Diplomate ACVIM
(Small Animal Internal
Medicine)

IMAGING PERFORMED BY

Carlie Koltek, RVT

HOSPITAL NAME

Tuxedo Animal
Hospital

REFERRING VET

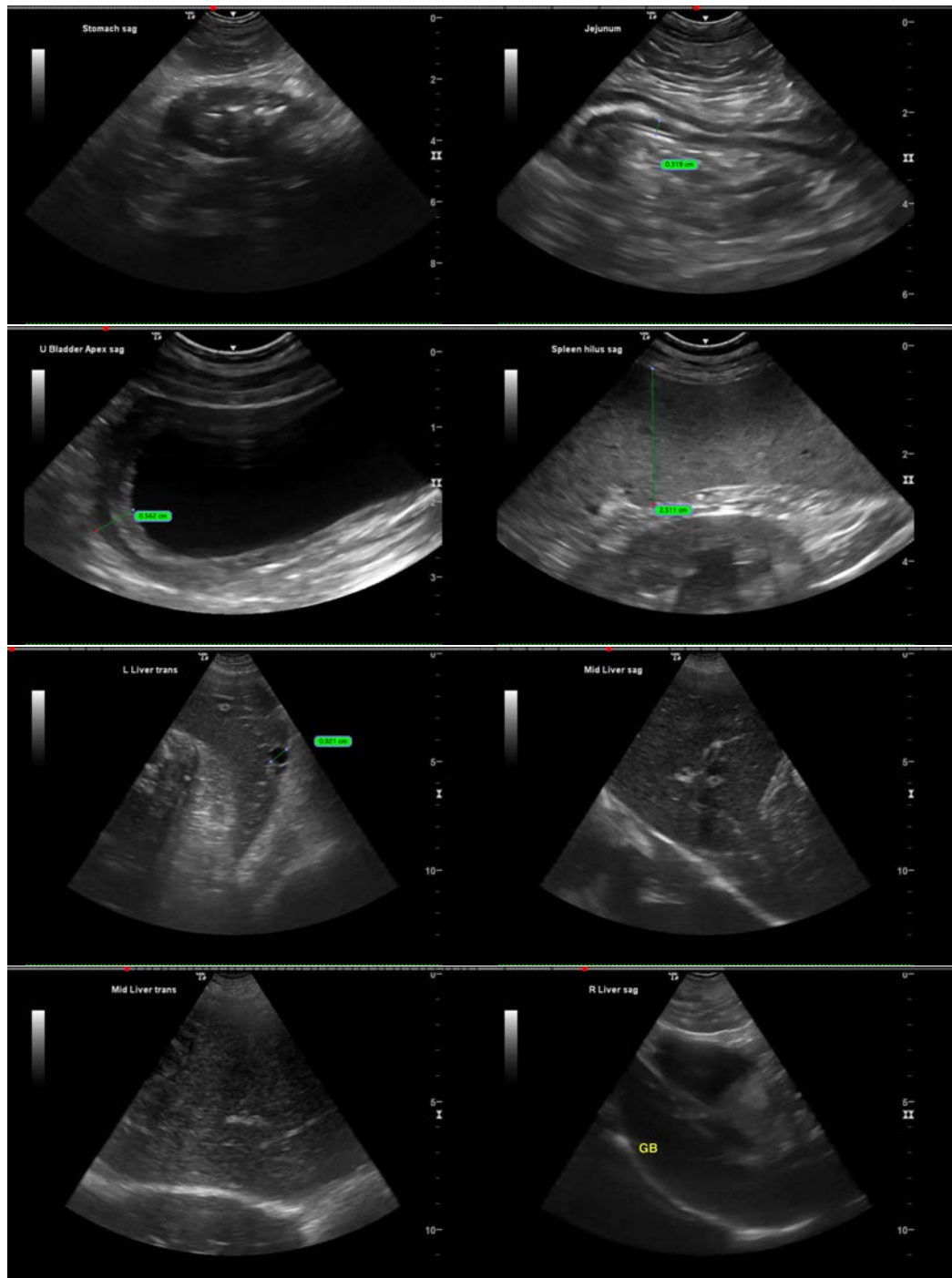
Dr. Hickling

INVOICE

73990

DATE

3/25/26





PATIENT

Epi Samalgalski

SPECIES

Canine

BREED

Lab Retriever x

SEX

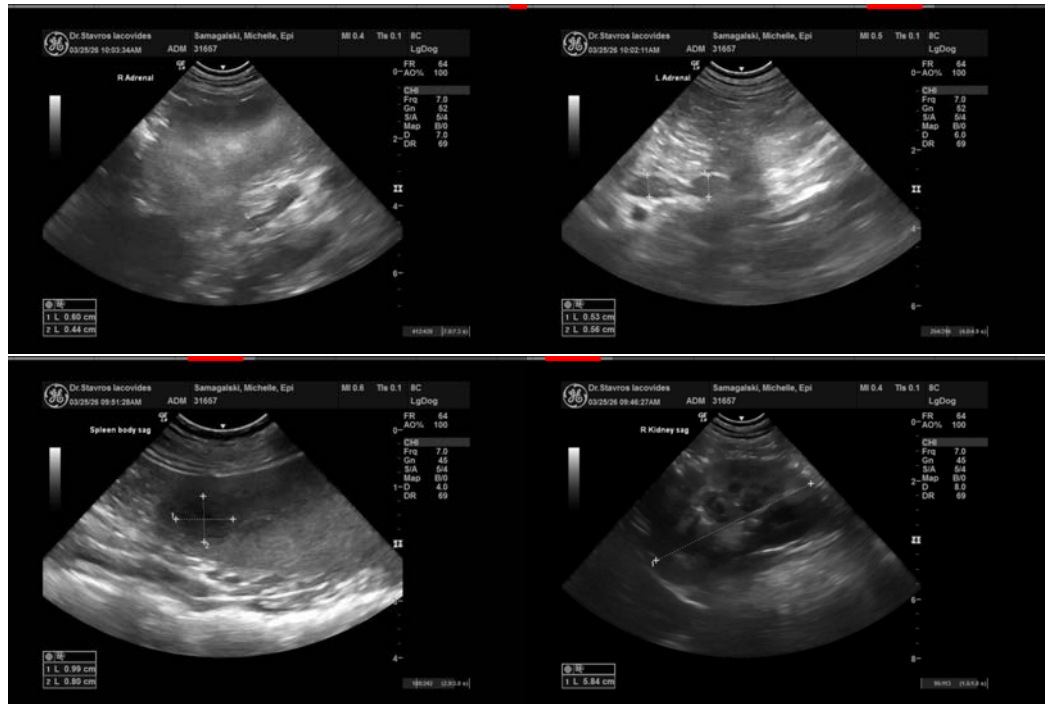
Spayed Female

AGE

10 Years

WEIGHT

29.6 kg



INTERPRETED BY

Kathleen Sennello DVM,
MS, Diplomate ACVIM
(Small Animal Internal
Medicine)

The information and recommendations provided are based on the images presented by the referring veterinarian/sonographer. No evaluation can be communicated regarding pathology that was not visible in the image/video clips provided.

Thank you for this referral. If the clinical or image interpretation does not parallel your findings or if I can be of any further assistance please contact me.

Kathleen Sennello DVM,MS, Diplomate ACVIM (Small animal Internal Medicine)

IMAGING PERFORMED BY

Carlie Kolttek, RVT

info@sonopath.com

HOSPITAL NAME

Tuxedo Animal
Hospital

REFERRING VET

Dr. Hickling

INVOICE

73990

DATE

3/25/26