



PATIENT

Agnes Zaleski

SPECIES

Canine

BREED

American Eskimo x

SEX

Spayed Female

AGE

10 Years

WEIGHT

17 lbs

INTERPRETED BY

Kathleen Sennello DVM,
MS, Diplomate ACVIM
(Small Animal Internal
Medicine)

IMAGING PERFORMED BY

Vincent Ravancho, CVT

HOSPITAL NAME

Millburn Veterinary
Hospital

REFERRING VET

Dr. Mosquera

INVOICE

73997

DATE

3/25/26

PRESENTING CLINICAL SIGNS

Mild ALT elevation (192). Exam from 12/2025 unremarkable, no concerns from O

Abnormal PE/Chem/CBC/UA Results: ALT 192, SDMA 15, Cholesterol 452, USG - 1.035

ULTRASONOGRAPHIC EXAMINATION OF THE ABDOMEN

Urinary System

The urinary bladder is moderately distended with anechoic urine. The Bladder wall, trigone, ureteral papillae and visible urethra (to a depth of 2cm) appear normal with no evidence of wall thickening, mucosal irregularities, masses or cystic calculi.

The left kidney has a normal shape and size (4.05 cm). Overall echogenicity is normal with adequate corticomedullary distinction and a typical 1:3 cortex:medulla ratio. There is no evidence of focal perinephric inflammation or effusion. There is no evidence of pyelectasia, nephroliths, infarcts or hydroureter. Renal vasculature is normal.

The right kidney has a normal shape and size (3.52 cm). Overall echogenicity is normal with adequate corticomedullary distinction and a typical 1:3 cortex:medulla ratio. There is no evidence of focal perinephric inflammation or effusion. There is no evidence of pyelectasia, nephroliths, infarcts or hydroureter. Renal vasculature is normal.

Adrenal Glands

The left adrenal gland is "plump" measuring 0.65 cm at the cranial pole and 0.67 cm at the caudal pole. It is observed in its normal position cranial to the left renal artery. It is normal in appearance (uniformly hypoechoic) and shape with no evidence of a mass effect.

The right adrenal gland is "plump" measuring 0.78 cm at the cranial pole and 0.77 cm at the caudal pole. It is observed in its normal position between the cranial aspect of the right kidney and the caudal vena cava. It is normal in appearance (uniformly hypoechoic) and shape with no evidence of a mass effect.

Spleen

The spleen is subjectively normal in size (1.76 cm), echotexture is homogenous, and the splenic capsule is smooth with no irregularities. The blood flow through the hilus and splenic parenchyma appears normal. No focal parenchymal abnormalities are visualized.

Liver

The liver is subjectively normal in size, and echogenicity with smooth peripheral margins. The parenchyma is homogenous echotexture. The visible portions of the vasculature and biliary tract appear normal. No focal nodules or cystic lesions are observed.

The gall bladder lumen is moderately distended. The wall of the gall bladder is not thickened and has a smooth mucosal surface. Luminal contents are mild and likely incidental at this time. The cystic and common bile ducts are normal/not visible.



PATIENT

Agnes Zaleski

SPECIES

Canine

BREED

American Eskimo x

SEX

Spayed Female

AGE

10 Years

WEIGHT

17 lbs

INTERPRETED BY

Kathleen Sennello DVM,
MS, Diplomate ACVIM
(Small Animal Internal
Medicine)

IMAGING PERFORMED BY

Vincent Ravancho, CVT

HOSPITAL NAME

Millburn Veterinary
Hospital

REFERRING VET

Dr. Mosquera

INVOICE

73997

DATE

3/25/26

Gastrointestinal

The stomach contains minimal luminal contents. It measures at a normal thickness of <0.7cm with some variability due to the presence of rugal folds. The distinction of the gastric wall layers is adequate and there is no impression of reduced peristaltic activity. No masses or focal lesions were observed.

The visualized areas of duodenum, jejunum and ileum have a relatively uniform diameter with minimal fluid distension. Wall thickness is normal. Bowel loops follow a curvilinear path with distinct wall layering maintaining the typical 1:3 muscularis:mucosa layer ratio. Duodenum wall measures 0.41 cm. Jejunum wall measures 0.37 cm. Visualized peristalsis appears appropriate. There were no focal lesions consistent with obstruction or a mass effect observed.

Sections of colon are visualized with formed fecal material and gas shadowing distally. There is no observed focal or generalized colon wall thickening or loss of layering.

Pancreas

The pancreas is normal and isoechoic to surrounding mesentery. There is no evidence of nodules or cystic lesions. There is no evidence of regional mesenteric inflammation or fluid.

Free Abdomen

Evaluation of the peritoneal cavity did not reveal any evidence of effusion, or subjective lymphadenomegaly. The Medial iliac nodes appear normal and there was no evidence of a caudal aortic thrombus at the bifurcation. The omentum is of normal uniform echogenicity.

ULTRASONOGRAPHIC FINDINGS

- Borderline “plump” adrenal glands – Findings could be consistent with anatomic variation or mild hyperplasia.

INTERPRETATION OF THE FINDINGS & FURTHER RECOMMENDATIONS

No focal lesions are visualized associated with the liver to explain the elevation in ALT reported. The parenchyma appears within normal limits. This does not rule out the possibility of a primary hepatopathy, with inflammatory, infectious and neoplastic differentials. Additionally, you could have a reactive hepatopathy or similar. Further evaluation could include the following:

- Consider pre- and post-prandial bile acids to assess liver function.
- Fine needle aspirate of the liver could be considered (provided coagulation parameters are normal), looking for evidence of infiltrative neoplasia, infectious organisms, etc.
- If the ALT elevation is persistent and/or progressive and/or liver function is abnormal, it is likely that a biopsy of the liver with samples for histopathology and cultures may be warranted.

Prior to any invasive testing, consider screening for Leptospirosis (if clinically appropriate), as well as empirical treatment for acute liver injury with a course of Denamarin +/- Ursodiol and a course of antibiotics (with concurrent probiotics).



PATIENT

Agnes Zaleski

SPECIES

Canine

BREED

American Eskimo x

SEX

Spayed Female

AGE

10 Years

WEIGHT

17 lbs

INTERPRETED BY

Kathleen Sennello DVM,
MS, Diplomate ACVIM
(Small Animal Internal
Medicine)

**IMAGING
PERFORMED BY**

Vincent Ravancho, CVT

HOSPITAL NAME

Millburn Veterinary
Hospital

REFERRING VET

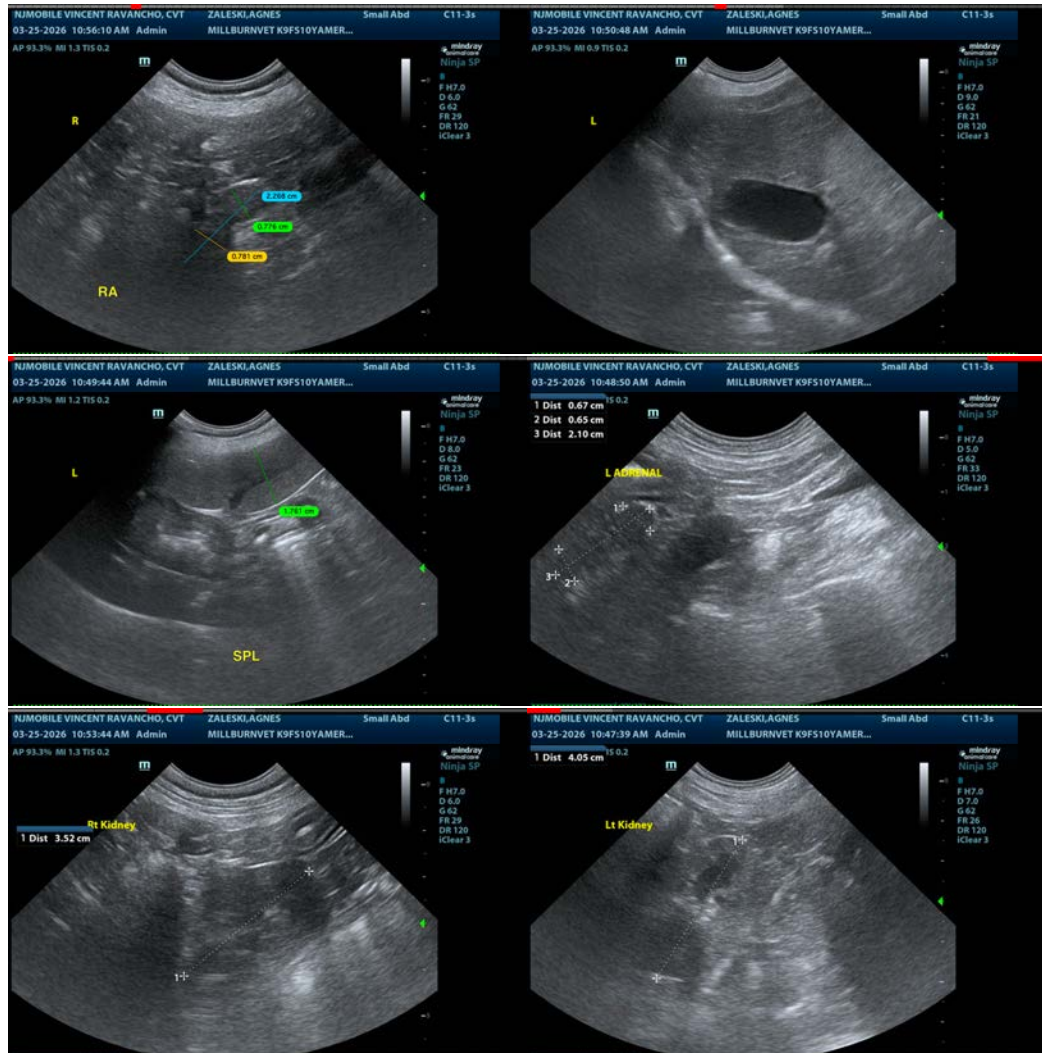
Dr. Mosquera

INVOICE

73997

DATE

3/25/26



The information and recommendations provided are based on the images presented by the referring veterinarian/sonographer. No evaluation can be communicated regarding pathology that was not visible in the image/video clips provided.

Thank you for this referral. If the clinical or image interpretation does not parallel your findings or if I can be of any further assistance please contact me.

Kathleen Sennello DVM,MS, Diplomate ACVIM (Small animal Internal Medicine)

info@sonopath.com