



**PATIENT**

Newman Balta

**SPECIES**

Canine

**BREED**

Weimaraner

**SEX**

Neutered Male

**AGE**

10 Years

**WEIGHT**

80.5 Pounds

**INTERPRETED BY**

Kathleen Sennello DVM,  
MS, Diplomate ACVIM  
(Small Animal Internal  
Medicine)

**IMAGING  
PERFORMED BY**

Shari Reffi, CVT

**HOSPITAL NAME**

North Jersey AH

**REFERRING VET**

Dr. Riedel

**INVOICE**

36416

**DATE**

3/24/22

**PRESENTING CLINICAL SIGNS**

PU/PD, ravenous appetite, weight loss. No current meds.

Abnormal PE/Chem/CBC/UA Results: ALT 139, ALKP 2272, Chol 366, Na 153, Lymph 730. U/A-USG 1.017, PH 6.5

**ULTRASONOGRAPHIC EXAMINATION OF THE ABDOMEN**

**Urinary System**

The urinary bladder is moderately distended with anechoic urine. The Bladder wall, trigone, ureteral papillae and visible urethra (to a depth of 2cm) appear normal with no evidence of wall thickening, mucosal irregularities, masses or cystic calculi.

The prostate is normal in size (1.0 cm) and shape for this neutered male dog. The parenchyma is homogenous and the external margins are smooth. The prostatic urethra appears normal with no evidence of irregularity, invasion, mass effect or calculi.

The left kidney has a normal shape and size (7.38 cm). Overall echogenicity is normal with adequate corticomedullary distinction and a typical 1:3 cortex:medulla ratio. There is no evidence of perinephric inflammation or effusion. There is no evidence of pyelectasia, nephroliths, infarcts or hydroureter. Renal vasculature is normal.

The right kidney has a normal shape and size (7.27 cm). Overall echogenicity is normal with adequate corticomedullary distinction and a typical 1:3 cortex:medulla ratio. There is no evidence of perinephric inflammation or effusion. There is no evidence of pyelectasia, nephroliths, infarcts or hydroureter. Renal vasculature is normal.

**Adrenal Glands**

The left adrenal gland is normal in size measuring 0.54 cm at the caudal pole. It is observed in its normal position cranial to the left renal artery. It is normal in appearance (uniformly hypoechoic) and shape with no evidence of a mass effect.

The right adrenal gland is normal in size measuring 0.59 cm at the caudal pole. It is observed in its normal position between the cranial aspect of the right kidney and the caudal vena cava. It is normal in appearance (uniformly hypoechoic) and shape with no evidence of a mass effect.

**Spleen**

The spleen is subjectively normal in size, echotexture is homogenous, and the splenic capsule is smooth with no irregularities. The blood flow through the hilus and splenic parenchyma appears normal. There is a solitary hyperechoic nodule visualized measuring 0.66 cm. This is most consistent with a benign myelolipoma.

**Liver**

The liver is large in size with smooth peripheral margins. The parenchyma is heterogenous in echotexture with subtle, indistinct focal mottling. The visible portions of the vasculature and biliary tract appear normal. No focal nodules or cystic lesions are observed.

The gallbladder lumen is moderately distended. The wall of the gall bladder is not thickened and has a smooth mucosal surface. Luminal contents are primarily anechoic. The cystic and common bile ducts are normal/not visible.



**PATIENT**

Newman Balta

**Gastrointestinal**

The stomach contains minimal luminal contents. It measures at a normal thickness of <0.7cm with some variability due to the presence of rugal folds. The distinction of the gastric wall layers is adequate and there is no impression of reduced peristaltic activity. No masses or focal lesions were observed.

**SPECIES**

Canine

The visualized areas of duodenum, jejunum and ileum have a relatively uniform diameter with minimal fluid distension. Wall thickness is normal. Bowel loops follow a curvilinear path with distinct wall layering maintaining the typical 1:3 muscularis:mucosa layer ratio. The duodenum measured as normal (between 0.3-0.5cm in wall thickness) and the jejunum measured as normal (between 0.2-0.47cm.)

**BREED**

Weimaraner

Visualized peristalsis appears appropriate. There were no focal lesions consistent with obstruction or a mass effect observed.

**SEX**

Neutered Male

The ileocecal junction was visualized and exhibited normal intact wall layering and is subjectively of normal thickness. Sections of colon are visualized with formed fecal material and gas shadowing distally. There is no observed focal or generalized colon wall thickening or loss of layering.

**Pancreas**

**AGE**

10 Years

The pancreas is normal and isoechoic to surrounding mesentery. There is no evidence of nodules or cystic lesions. There is no evidence of regional mesenteric inflammation or fluid.

**Free Abdomen**

**WEIGHT**

80.5 Pounds

Evaluation of the peritoneal cavity did not reveal any evidence of effusion, or subjective lymphadenomegaly. The Medial iliac nodes appear normal and there was no evidence of a caudal aortic thrombus at the bifurcation. The omentum is of normal uniform echogenicity.

**Other**

**INTERPRETED BY**

Kathleen Sennello DVM,  
MS, Diplomate ACVIM  
(Small Animal Internal  
Medicine)

A brief view of the heart was submitted. No significant pericardial effusion was seen.

**PRIMARY FINDINGS**

- Large, heterogeneous liver – The diffuse hepatic changes are non-specific and could be consistent with vacuolar hepatopathy, nodular hyperplasia, inflammatory/immune-mediated disease, fibrosis, extramedullary hematopoiesis, toxic hepatopathy (e.g., copper), infiltrative neoplasia (less likely) or other hepatopathy.

**IMAGING PERFORMED BY**

Shari Reffi, CVT

**SECONDARY FINDINGS**

- Hyperechoic foci in the spleen – Findings are most consistent with benign myelolipomas.

**HOSPITAL NAME**

North Jersey AH

**INTERPRETATION OF THE FINDINGS & FURTHER RECOMMENDATIONS**

No focal lesions are visualized associated with the liver or biliary tract. Findings are most consistent with a primary hepatopathy.

**REFERRING VET**

Dr. Riedel

- Consider close evaluation of history for possible toxic changes examine medications, diet, dietary indiscretion etc...

**INVOICE**

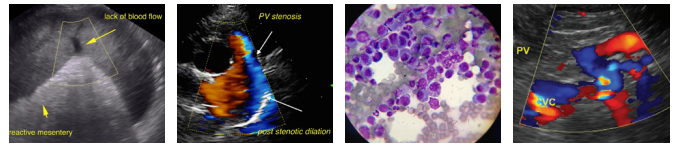
36416

- Consider PCR on urine/serum for leptospirosis (if not on antibiotics)/serology if recent antibiotic history

- If not already done, consider pre and post prandial bile acids to evaluate liver function

**DATE**

3/24/22



**PATIENT**

Newman Balta

- If the ALP is significantly elevated relative to the ALT and symptoms consistent with cushings are present, consider adrenal function testing (ACTH stim)

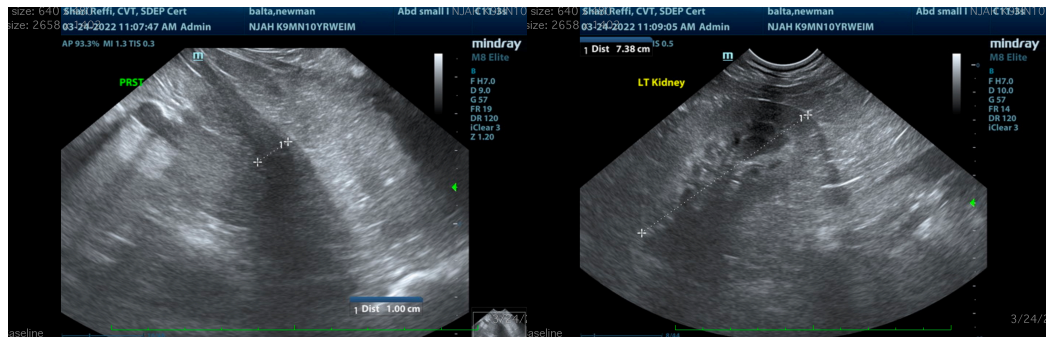
**SPECIES**

Canine

- Consider Fine needle aspirate if round cell neoplasia is on your differential list (25 g needle, normal coags)

**BREED**

Weimaraner



**SEX**

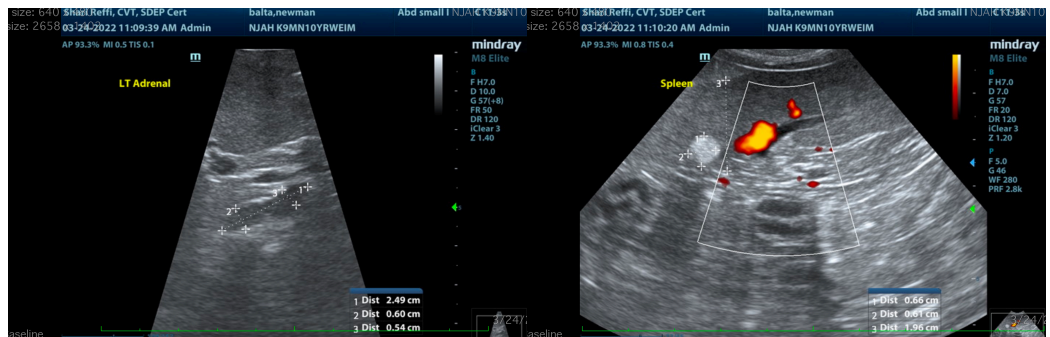
Neutered Male

**AGE**

10 Years

**WEIGHT**

80.5 Pounds

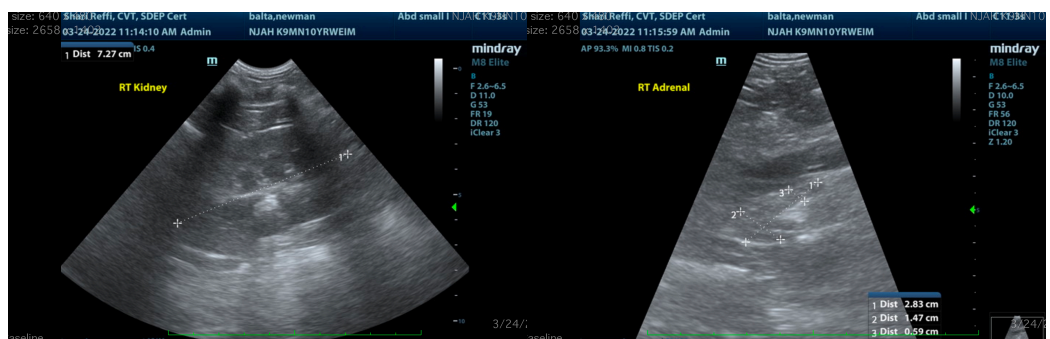


**INTERPRETED BY**

Kathleen Sennello DVM, MS, Diplomate ACVIM (Small Animal Internal Medicine)

**IMAGING PERFORMED BY**

Shari Reffi, CVT

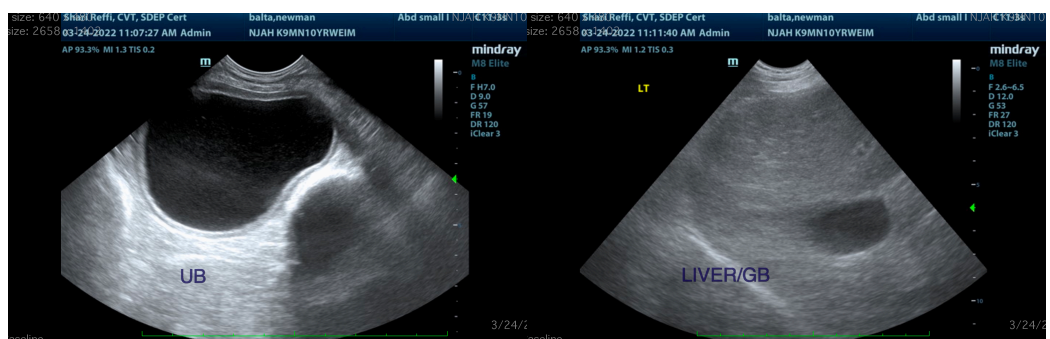


**HOSPITAL NAME**

North Jersey AH

**REFERRING VET**

Dr. Riedel



**INVOICE**

36416

**DATE**

3/24/22



**PATIENT**

Newman Balta

The information and recommendations provided are based on the images presented by the referring veterinarian/sonographer. No evaluation can be communicated regarding pathology that was not visible in the image/video clips provided.

**SPECIES**

Canine

Thank you for this referral. If the clinical or image interpretation does not parallel your findings or if I can be of any further assistance please contact me.

Kathleen Sennello DVM,MS, Diplomate ACVIM (Small animal Internal Medicine)

**BREED**

Weimaraner

kathleen.sennello@sonopath.com

**SEX**

Neutered Male

**AGE**

10 Years

**WEIGHT**

80.5 Pounds

**INTERPRETED BY**

Kathleen Sennello DVM,  
MS, Diplomate ACVIM  
(Small Animal Internal  
Medicine)

**IMAGING  
PERFORMED BY**

Shari Reffi, CVT

**HOSPITAL NAME**

North Jersey AH

**REFERRING VET**

Dr. Riedel

**INVOICE**

36416

**DATE**

3/24/22