**DATE PRESENTING CLINICAL SIGNS**

3/24/22 P presented for glucose curve on 3/15 after having uncontrolled clinical signs of diabetes including PU/PD and weight loss. No glucose lowering effect was appreciated while on 3U BID of insulin. ALP >2000 on 2/14/22 BW. Previous ALP 1094 on 10/9/21.

PATIENT

Dugan Trogdon

Current Medications: Vetsulin 3U BID SQ starting 2/14- increased to 4U BID SQ starting 3/18.
Lab Results: 2/14/22 ALP >2000, Glu 461.

SPECIES

Canine

Date of Previous IntraPet Ultrasound: No previous.
Sedation: Not required to complete full diagnostic ultrasound.
Stat Report: Not requested.

BREED

Mixed

ULTRASONOGRAPHIC EXAMINATION OF THE ABDOMEN**Urinary System**

The urinary bladder is moderately distended with anechoic urine. The Bladder wall, trigone, ureteral papillae and visible urethra (to a depth of 2cm) appear normal with no evidence of wall thickening, mucosal irregularities, masses or cystic calculi.

SEX

Neutered Male

The visualized areas of prostate and surrounding tissue appear normal. Unfortunately, the prostate is not fully visualized likely due to its intrapelvic location. Correlate with rectal exam findings.

AGE

4/1/11

The left kidney has a normal shape and size (4.65 cm) with mild pyelectasia at 0.22 cm. Overall echogenicity is normal with adequate corticomedullary distinction and a typical 1:3 cortex:medulla ratio. There is no evidence of perinephric inflammation or effusion. There is no evidence of nephroliths, infarcts or hydroureter. Renal vasculature is normal.

WEIGHT

17.9 Pounds

The right kidney has a normal shape and size (4.66 cm) with mild pyelectasia at 0.17 cm. Overall echogenicity is normal with adequate corticomedullary distinction and a typical 1:3 cortex:medulla ratio. There is no evidence of perinephric inflammation or effusion. There is no evidence of nephroliths, infarcts or hydroureter. Renal vasculature is normal.

INTERPRETED BY

Kathleen Sennello DVM,
MS, Diplomate ACVIM
(Small Animal Internal
Medicine)

Adrenal Glands

The left adrenal gland is normal in size measuring 0.68 cm at the caudal pole. It is observed in its normal position cranial to the left renal artery. It is normal in appearance (uniformly hypoechoic) and shape with no evidence of a mass effect.

IMAGING PERFORMED BY

Andi Parkinson RDMS

The right adrenal gland is normal in size measuring 0.54 cm at the caudal pole. It is observed in its normal position between the cranial aspect of the right kidney and the caudal vena cava. It is normal in appearance (uniformly hypoechoic) and shape with no evidence of a mass effect.

HOSPITAL NAME

Eastern AH

Spleen

The spleen is subjectively normal in size, echotexture is homogenous, and the splenic capsule is smooth with no irregularities. The blood flow through the hilus and splenic parenchyma appears normal. No focal parenchymal abnormalities are visualized.

REFERRING VET

Dr. Frere

Liver

The liver is large and hyperechoic. The parenchyma is heterogenous in echotexture with subtle, indistinct focal mottling. The visible portions of the vasculature and biliary tract appear normal. No focal nodules or cystic lesions are observed.

INVOICE

36442

The gall bladder lumen is significantly distended. Some areas of the wall appear mildly thickened with adherent debris. There is a large amount of echogenic debris with early mucosal stranding and organization, most consistent with development of an early mucocele. There is no evidence of bile duct dilation.

Gastrointestinal

The stomach contains minimal luminal contents. It measures at a normal thickness of <0.7cm with some variability due to the presence of rugal folds. The distinction of the gastric wall layers is adequate and there is no impression of reduced peristaltic activity. No masses or focal lesions were observed.

The visualized areas of duodenum, jejunum and ileum have a relatively uniform diameter with minimal fluid distension. Wall thickness is normal. Bowel loops follow a curvilinear path with distinct wall layering maintaining the typical 1:3 muscularis:mucosa layer ratio. Jejunum wall measured 0.34 cm. Visualized peristalsis appears appropriate. There were no focal lesions consistent with obstruction or a mass effect observed.

The ileocecal junction was visualized and exhibited normal intact wall layering and is subjectively of normal thickness. Sections of colon are visualized with formed fecal material and gas shadowing distally. There is no observed focal or generalized colon wall thickening or loss of layering.

Pancreas

The pancreas is normal and isoechoic to surrounding mesentery. There is no evidence of nodules or cystic lesions. There is no evidence of regional mesenteric inflammation or fluid.

Free Abdomen

Evaluation of the peritoneal cavity did not reveal any evidence of effusion, or subjective lymphadenomegaly. The Medial iliac nodes appear normal and there was no evidence of a caudal aortic thrombus at the bifurcation. The omentum is of normal uniform echogenicity.

ULTRASONOGRAPHIC FINDINGS

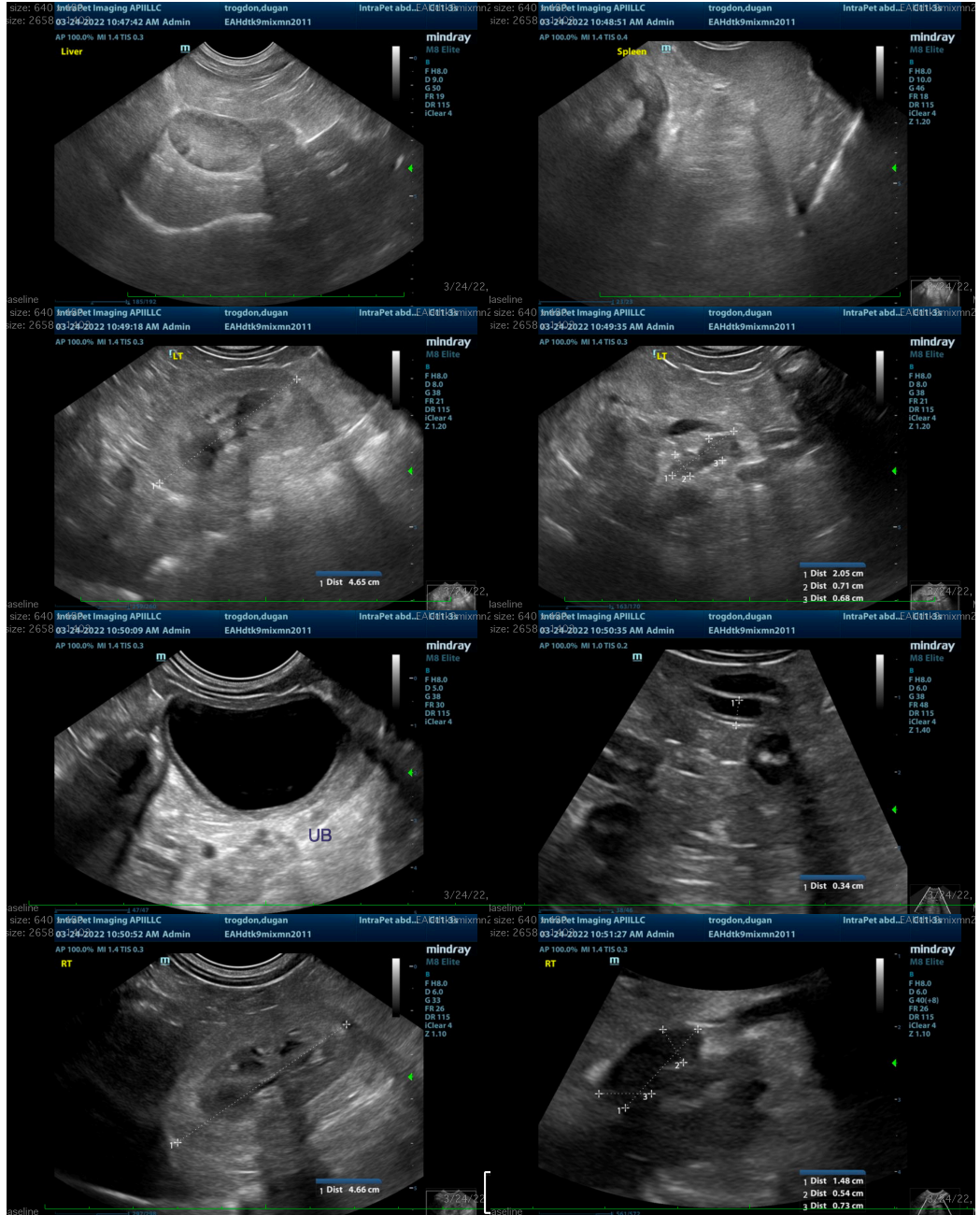
- Large, heterogeneous, hyperechoic liver – The diffuse hepatic changes are non-specific and could be consistent with vacuolar hepatopathy, nodular hyperplasia, inflammatory/immune-mediated disease, fibrosis, extramedullary hematopoiesis, toxic hepatopathy (e.g., copper), infiltrative neoplasia (less likely) or other hepatopathy. This is most consistent with a diabetic hepatopathy.
- Large amount of adhered gallbladder debris with early mucosal stranding and organization – Findings are consistent with early mucocele formation. There is no obvious inflammation or fluid surrounding the gallbladder at this time.
- Bilateral mild renal pyelectasia – Pyelectasia of the left/right kidney could be consistent with pyelonephritis, chronic renal disease, secondary to PU/PD or fluid therapy (if applicable), other.

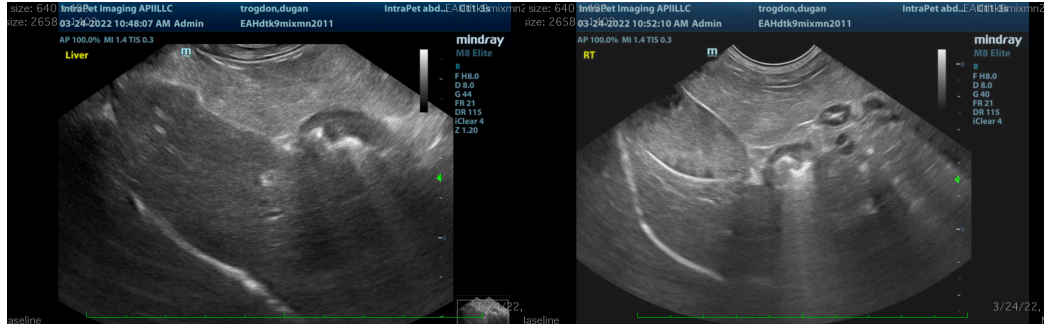
INTERPRETATION OF THE FINDINGS & FURTHER RECOMMENDATIONS

The changes observed in the liver and kidneys could be consistent with the diabetes reported. Recommend a urinalysis and culture.

Additionally, there is an early mucocele present. Recommend initiating medical therapy with Ursodiol +/- antibiotics and close monitoring, as this could develop into a surgical lesion.

This patient is still on a relatively low-dose of insulin. Recommend very gradual increase in insulin with the guidance of glucose curves. If dosing exceeds 8 units BID, I would consider this consistent with insulin resistance and consider adrenal function testing, etc.





The information and recommendations provided are based on the images presented by the referring veterinarian/sonographer. No evaluation can be communicated regarding pathology that was not visible in the image/video clips provided.

Thank you for this referral. If the clinical or image interpretation does not parallel your findings or if I can be of any further assistance please contact me.

Kathleen Sennello DVM,MS, Diplomate ACVIM (Small animal Internal Medicine)
kathleen.sennello@sonopath.com