



PATIENT

Max Kamenir

SPECIES

Feline

BREED

DSH

SEX

Neutered Male

AGE

8 Years

WEIGHT

13.7 Pounds

INTERPRETED BY

Kathleen Sennello DVM,
MS, Diplomate ACVIM
(Small Animal Internal
Medicine)

**IMAGING
PERFORMED BY**

Diane McFadden

HOSPITAL NAME

Whippany VH

REFERRING VET

Dr. Smith

INVOICE

46155

DATE

3/23/23

PRESENTING CLINICAL SIGNS

check bladder. Suspect cystic calculi seen on rad. On convenia.

Abnormal PE/Chem/CBC/UA Results: neutrophilia 13,892 absolute; UA: protein 4+, blood 3+ (cysto), USPG 1.068

ULTRASONOGRAPHIC EXAMINATION OF THE ABDOMEN

Urinary System

The urinary bladder is moderately distended with anechoic urine. The Bladder wall, trigone, ureteral papillae and visible urethra (to a depth of 2cm) appear normal with no evidence of wall thickening, mucosal irregularities, or masses. In the dependent portion of the urinary bladder, there is a focus of hyperechoic irregular shadowing material most consistent with two small stones or an accumulation of mineralized debris.

The left kidney has a normal shape and size (4.52 cm). Overall echogenicity is normal with adequate corticomedullary distinction and a typical 1:3 cortex:medulla ratio. There is no evidence of focal perinephric inflammation or effusion. There is no evidence of pyelectasia, nephroliths, infarcts or hydroureter. Renal vasculature is normal.

The right kidney has a normal shape and size (4.35 cm). Overall echogenicity is normal with adequate corticomedullary distinction and a typical 1:3 cortex:medulla ratio. There is no evidence of focal perinephric inflammation or effusion. There is no evidence of pyelectasia, nephroliths, infarcts or hydroureter. Renal vasculature is normal.

Adrenal Glands

The left adrenal gland is normal in size measuring 0.48 cm at the caudal pole. It is observed in its normal position cranial to the left renal artery. It is normal in appearance (uniformly hypoechoic) and shape with no evidence of a mass effect. Pinpoint mineralizations are present.

The right adrenal gland is normal in size measuring 0.40 cm at the caudal pole. It is observed in its normal position between the cranial aspect of the right kidney and the caudal vena cava. It is normal in appearance (uniformly hypoechoic) and shape with no evidence of a mass effect.

Spleen

The spleen is subjectively normal in size (0.79 cm in width at the level of the hilus), echotexture is homogenous, and the splenic capsule is smooth with no irregularities. The blood flow through the hilus and splenic parenchyma appears normal. No focal parenchymal abnormalities are visualized.

Liver

The liver is subjectively normal in size, and echogenicity with smooth peripheral margins. The parenchyma is homogenous echotexture. The visible portions of the vasculature and biliary tract appear normal. No focal nodules or cystic lesions are observed.

The gallbladder lumen is moderately distended. The wall of the gall bladder is not thickened and has a smooth mucosal surface. Luminal contents are mild and primarily anechoic. The cystic and common bile ducts are normal/not visible.



PATIENT

Max Kamenir

SPECIES

Feline

BREED

DSH

SEX

Neutered Male

AGE

8 Years

WEIGHT

13.7 Pounds

INTERPRETED BY

Kathleen Sennello DVM,
MS, Diplomate ACVIM
(Small Animal Internal
Medicine)

**IMAGING
PERFORMED BY**

Diane McFadden

HOSPITAL NAME

Whippany VH

REFERRING VET

Dr. Smith

INVOICE

46155

DATE

3/23/23

Gastrointestinal

The stomach contains minimal luminal contents. It measures at a normal thickness of <0.36cm with some variability due to the presence of rugal folds. The distinction of the gastric wall layers is adequate and there is no impression of reduced peristaltic activity. No masses or focal lesions were observed.

The visualized areas of duodenum, jejunum and ileum have a relatively uniform diameter with minimal fluid distension. Wall thickness is normal. Bowel loops follow a curvilinear path with distinct wall layering maintaining the typical 1:3 muscularis:mucosa layer ratio. Jejunum wall measures 0.20 cm. Visualized peristalsis appears appropriate. There were no focal lesions consistent with obstruction or a mass effect observed.

The ileocecal junction was visualized and exhibited normal intact wall layering and is subjectively of normal thickness. Sections of colon are visualized with formed fecal material and gas shadowing distally. There is no observed focal or generalized colon wall thickening or loss of layering.

Pancreas

The pancreas is normal and isoechoic to surrounding mesentery. There is no evidence of nodules or cystic lesions. There is no evidence of regional mesenteric inflammation or fluid.

Free Abdomen

Evaluation of the peritoneal cavity did not reveal any evidence of effusion, or subjective lymphadenomegaly. The Medial iliac nodes appear normal and there was no evidence of a caudal aortic thrombus at the bifurcation. The omentum is of normal uniform echogenicity.

PRIMARY FINDINGS

- Dependent mineralized debris in the urinary bladder – Findings are most consistent with small stones or mineralized debris. Correlate with abdominal radiographs to better determine the number and size of mineralizations present.

SECONDARY FINDINGS

- Pinpoint mineralizations of the left adrenal gland – This is likely an incidental finding.

INTERPRETATION OF THE FINDINGS & FURTHER RECOMMENDATIONS

There is an accumulation of irregular mineralization in the dependent portion of the urinary bladder, most consistent with 2+ small stones, but I cannot differentiate from the possibility of multiple stones, an accumulation of adhered debris, etc. Recommend a urinalysis and culture. If an infection is present or struvites are suspected, you could attempt dissolution with close monitoring for possible obstruction. If oxalate stones are suspected, a cystotomy may be necessary depending on the radiographs and patient's clinical evaluation.



PATIENT

Max Kamenir

SPECIES

Feline

BREED

DSH

SEX

Neutered Male

AGE

8 Years

WEIGHT

13.7 Pounds

INTERPRETED BY

Kathleen Sennello DVM,
MS, Diplomate ACVIM
(Small Animal Internal
Medicine)

**IMAGING
PERFORMED BY**

Diane McFadden

HOSPITAL NAME

Whippany VH

REFERRING VET

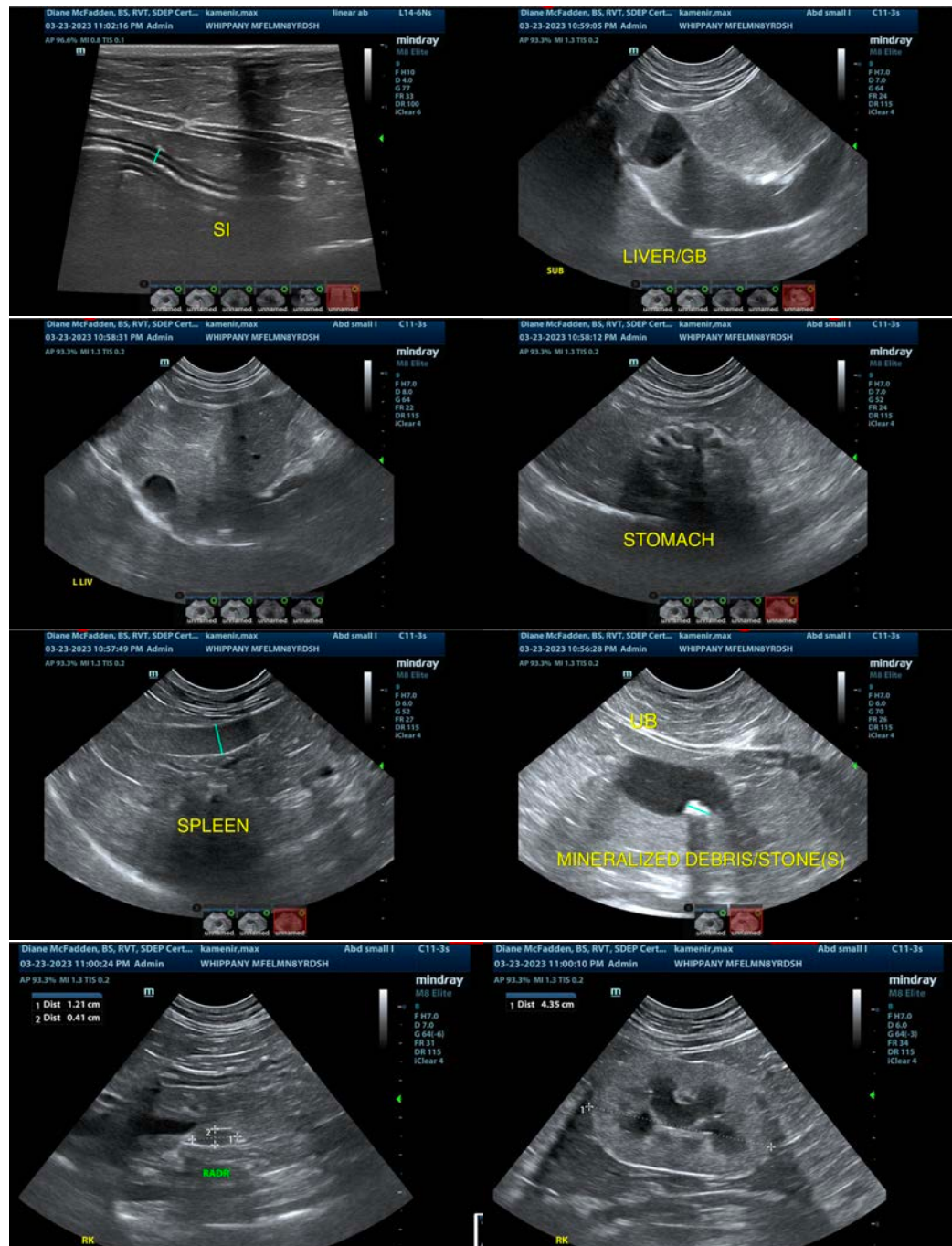
Dr. Smith

INVOICE

46155

DATE

3/23/23





PATIENT

Max Kamenir

SPECIES

Feline

BREED

DSH

SEX

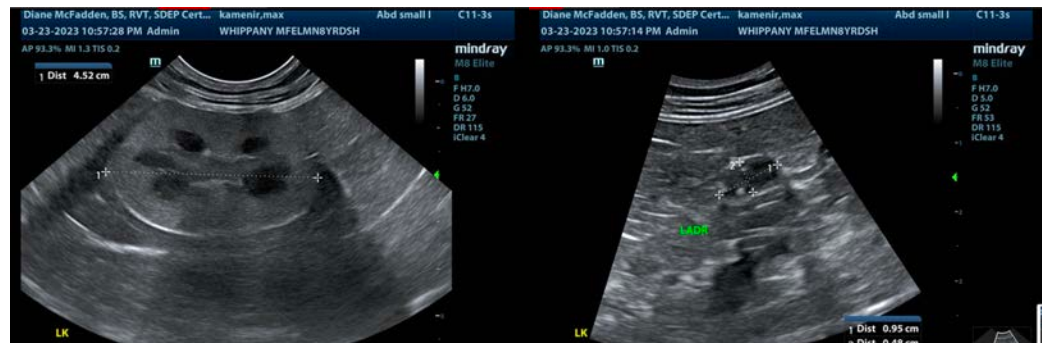
Neutered Male

AGE

8 Years

WEIGHT

13.7 Pounds



The information and recommendations provided are based on the images presented by the referring veterinarian/sonographer. No evaluation can be communicated regarding pathology that was not visible in the image/video clips provided.

Thank you for this referral. If the clinical or image interpretation does not parallel your findings or if I can be of any further assistance please contact me.

Kathleen Sennello DVM,MS, Diplomate ACVIM (Small animal Internal Medicine)

kathleen.sennello@sonopath.com

INTERPRETED BY

Kathleen Sennello DVM,
MS, Diplomate ACVIM
(Small Animal Internal
Medicine)

IMAGING PERFORMED BY

Diane McFadden

HOSPITAL NAME

Whippany VH

REFERRING VET

Dr. Smith

INVOICE

46155

DATE

3/23/23