



**PATIENT**

Jake Paradiso

**SPECIES**

Canine

**BREED**

Australian x Poodle

**SEX**

Neutered Male

**AGE**

10 Months

**WEIGHT**

31.4 Pounds

**INTERPRETED BY**

Kathleen Sennello DVM,  
MS, Diplomate ACVIM  
(Small Animal Internal  
Medicine)

**IMAGING  
PERFORMED BY**

Kelly Vazquez

**HOSPITAL NAME**

Midland Park VH

**REFERRING VET**

Dr. John Shokoff

**INVOICE**

46154

**DATE**

3/23/23

**PRESENTING CLINICAL SIGNS**

Patient presents for recurring vomiting and diarrhea. No current meds or recent blood work.

**ULTRASONOGRAPHIC EXAMINATION OF THE ABDOMEN**

**Urinary System**

The urinary bladder is moderately distended with anechoic urine. The Bladder wall, trigone, ureteral papillae and visible urethra (to a depth of 2cm) appear normal with no evidence of wall thickening, mucosal irregularities, masses or cystic calculi.

The prostate is normal in size (0.82 cm) and shape for this neutered male dog. The parenchyma is homogenous and the external margins are smooth. The prostatic urethra appears normal with no evidence of irregularity, invasion, mass effect or calculi.

The left kidney has a normal shape and size (5.87 cm). Overall echogenicity is normal with adequate corticomedullary distinction and a typical 1:3 cortex:medulla ratio. There is no evidence of focal perinephric inflammation or effusion. There is no evidence of pyelectasia, nephroliths, infarcts or hydroureter. Renal vasculature is normal.

The right kidney has a normal shape and size (4.23 cm). Overall echogenicity is normal with adequate corticomedullary distinction and a typical 1:3 cortex:medulla ratio. There is no evidence of focal perinephric inflammation or effusion. There is no evidence of pyelectasia, nephroliths, infarcts or hydroureter. Renal vasculature is normal.

**Adrenal Glands**

The left adrenal gland is normal in size measuring 0.35 cm at the caudal pole. It is observed in its normal position cranial to the left renal artery. It is normal in appearance (uniformly hypoechoic) and shape with no evidence of a mass effect.

The right adrenal gland is normal in size measuring 0.78 cm at the caudal pole. It is observed in its normal position between the cranial aspect of the right kidney and the caudal vena cava. It is normal in appearance (uniformly hypoechoic) and shape with no evidence of a mass effect.

**Spleen**

The spleen is subjectively normal in size, echotexture is homogenous, and the splenic capsule is smooth with no irregularities. The blood flow through the hilus and splenic parenchyma appears normal. No focal parenchymal abnormalities are visualized.

**Liver**

The liver is subjectively normal in size, and echogenicity with smooth peripheral margins. The parenchyma is homogenous echotexture. The visible portions of the vasculature and biliary tract appear normal. No focal nodules or cystic lesions are observed.

The gallbladder lumen is moderately distended. The wall of the gall bladder is not thickened and has a smooth mucosal surface. Luminal contents are mild and primarily anechoic. The cystic and common bile ducts are normal/not visible.



**PATIENT**

Jake Paradiso

**SPECIES**

Canine

**BREED**

Australian x Poodle

**SEX**

Neutered Male

**AGE**

10 Months

**WEIGHT**

31.4 Pounds

**INTERPRETED BY**

Kathleen Sennello DVM,  
MS, Diplomate ACVIM  
(Small Animal Internal  
Medicine)

**IMAGING PERFORMED BY**

Kelly Vazquez

**HOSPITAL NAME**

Midland Park VH

**REFERRING VET**

Dr. John Shokoff

**INVOICE**

46154

**DATE**

3/23/23

**Gastrointestinal**

The stomach contains minimal luminal contents. It measures at a normal thickness of <0.7cm with some variability due to the presence of rugal folds. The distinction of the gastric wall layers is adequate and there is no impression of reduced peristaltic activity. No masses or focal lesions were observed.

The visualized areas of duodenum, jejunum and ileum have a relatively uniform diameter with minimal fluid distension. Wall thickness is normal. Bowel loops follow a curvilinear path with distinct wall layering maintaining the typical 1:3 muscularis:mucosa layer ratio. Duodenum wall measures 0.46 cm. Jejunum wall measures 0.35 cm. Visualized peristalsis appears appropriate. There were no focal lesions consistent with obstruction or a mass effect observed.

The ileocecal junction was visualized and exhibited normal intact wall layering and is subjectively of normal thickness. Sections of colon are visualized with formed fecal material and gas shadowing distally. There is no observed focal or generalized colon wall thickening or loss of layering.

**Pancreas**

The pancreas is normal and isoechoic to surrounding mesentery. There is no evidence of nodules or cystic lesions. There is no evidence of regional mesenteric inflammation or fluid.

**Free Abdomen**

Evaluation of the peritoneal cavity did not reveal any evidence of effusion. There are occasional prominent mesenteric lymph nodes, examples measure 0.71 cm and 0.76 cm. The omentum is of normal echogenicity.

**ULTRASONOGRAPHIC FINDINGS**

- No significant ultrasonographic lesions observed

**INTERPRETATION OF THE FINDINGS & FURTHER RECOMMENDATIONS**

No focal lesions are visualized today to explain the vomiting and diarrhea reported. Unfortunately, there are many causes for this that cannot always be definitively diagnosed by ultrasound alone.

Initially, I would recommend full bloodwork (if not already done) looking for any metabolic causes of illness. Additionally, you could consider a baseline cortisol to rule out Addison's disease.

If metabolic disease is ruled out or thought unlikely, then consider the possibility of primary gastrointestinal disease. In a young dog like this, the most likely differentials include dietary indiscretion/foreign body ingestion, food allergy/dietary intolerance, dysbiosis, possibly pancreatitis, GI parasitism, and less likely IBD or neoplasia. Consider the following:

- Consider a novel protein/hydrolyzed protein diet (exclusively at least 4-6 weeks)
- Consider a GI panel to Texas A&M for evaluation of B12 levels, folate, PLI/TLI etc.. to further evaluate for pancreatic/small intestinal disease.
- Recommend a baseline cortisol.
- Recommend chronic pre- and probiotic therapy.
- If these steps are taken, and vomiting and diarrhea continue to persist, then consider the possibility of upper and lower GI endoscopy.

Although there is no evidence of ingested foreign material on today's scan, this cannot be definitively ruled out, so correlate findings with serial radiographs.



**PATIENT**

Jake Paradiso

**SPECIES**

Canine

**BREED**

Australian x Poodle

**SEX**

Neutered Male

**AGE**

10 Months

**WEIGHT**

31.4 Pounds

**INTERPRETED BY**

Kathleen Sennello DVM,  
MS, Diplomate ACVIM  
(Small Animal Internal  
Medicine)

**IMAGING  
PERFORMED BY**

Kelly Vazquez

**HOSPITAL NAME**

Midland Park VH

**REFERRING VET**

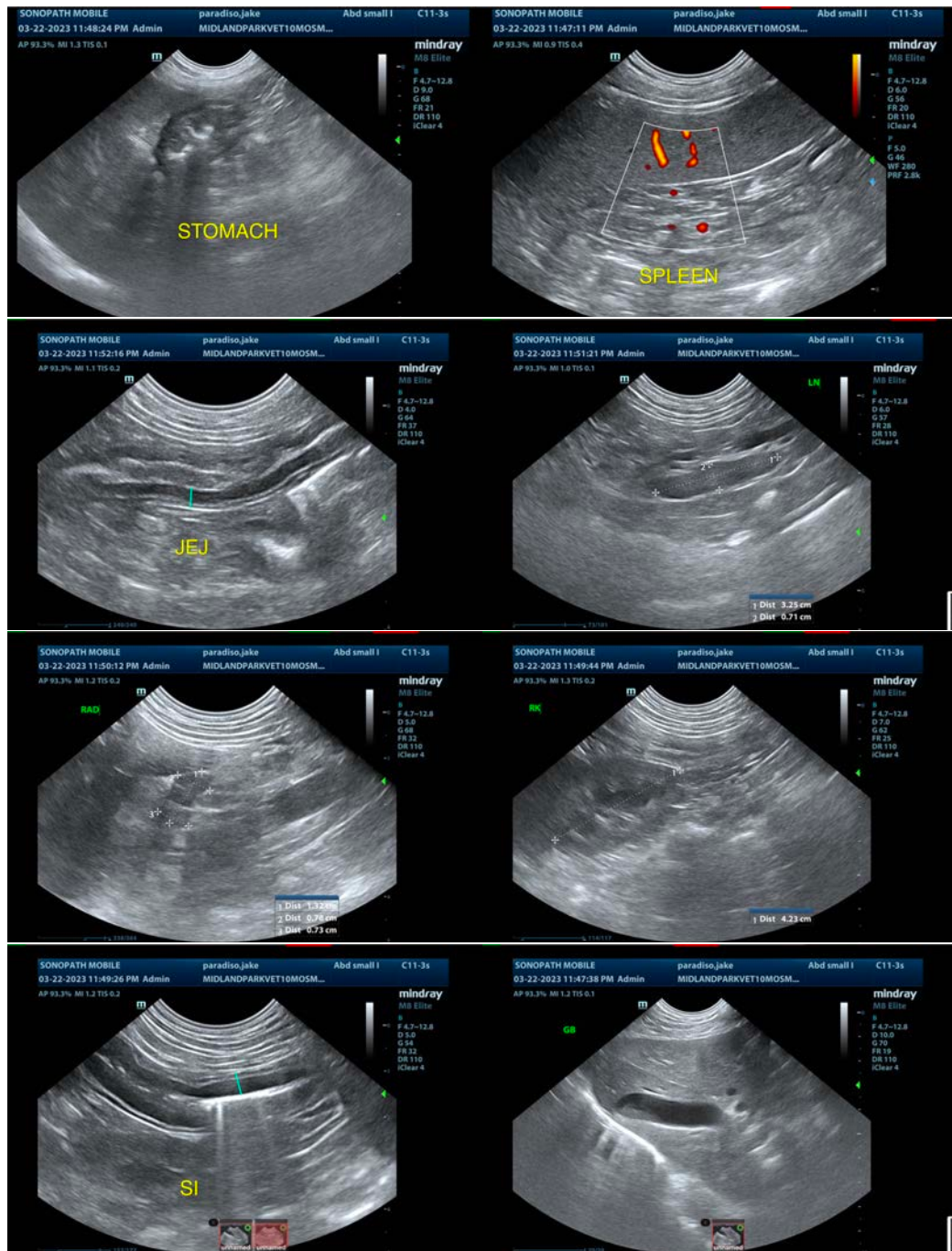
Dr. John Shokoff

**INVOICE**

46154

**DATE**

3/23/23





**PATIENT**

Jake Paradiso

**SPECIES**

Canine

**BREED**

Australian x Poodle

**SEX**

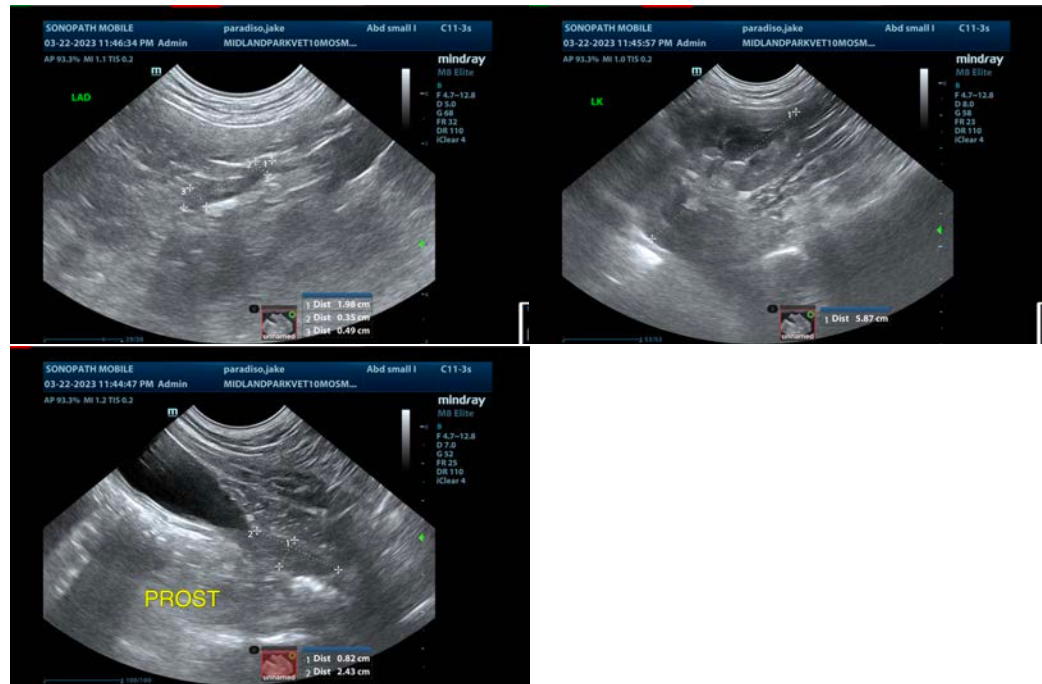
Neutered Male

**AGE**

10 Months

**WEIGHT**

31.4 Pounds



**INTERPRETED BY**

Kathleen Sennello DVM,  
MS, Diplomate ACVIM  
(Small Animal Internal  
Medicine)

The information and recommendations provided are based on the images presented by the referring veterinarian/sonographer. No evaluation can be communicated regarding pathology that was not visible in the image/video clips provided.

Thank you for this referral. If the clinical or image interpretation does not parallel your findings or if I can be of any further assistance please contact me.

**IMAGING PERFORMED BY**

Kelly Vazquez

Kathleen Sennello DVM,MS, Diplomate ACVIM (Small animal Internal Medicine)

kathleen.sennello@sonopath.com

**HOSPITAL NAME**

Midland Park VH

**REFERRING VET**

Dr. John Shokoff

**INVOICE**

46154

**DATE**

3/23/23