

**DATE PRESENTING CLINICAL SIGNS**

2/23/23 2/10/23 - Presented for routine exam and vaccine updates. Exam - Lenticular sclerosis, Periodontal disease, Pelvic limb muscle atrophy. 1 lb. weight loss. 3/14/23 - Repeat bloodwork (no exam) - Additional 1.6 lb. weight loss

PATIENT

Darcy Kapuscinski

Current Medications: Anipryl (10 mg) - 1 SID since 11/2022

Denamarin Advanced Small/Medium dog - 1 SID started 2/11/23 and given for 30 days

SPECIES

Canine

Lab Results: 2/10/23 - CBC/Chem 10 - ALT-408, BUN-40; 4DX-Lyme positive (historically positive since at least 2017). 3/14/23 - ALT-458, BUN-30

Date of Previous IntraPet Ultrasound: No previous.

Sedation: Not required to complete full diagnostic ultrasound.

Stat Report: Not requested.

BREED

German Shepherd X

Imaging Performed By: Stephanie Warga RDCS, RVT.

ULTRASONOGRAPHIC EXAMINATION OF THE ABDOMEN**SEX**

23 Pounds

Urinary System

The urinary bladder is moderately distended with anechoic urine. The Bladder wall, trigone, ureteral papillae and visible urethra (to a depth of 2cm) appear normal with no evidence of wall thickening, mucosal irregularities, masses or cystic calculi.

AGE

6/7/09

The left kidney has a normal shape and size (4.74 cm). Overall echogenicity is normal with adequate corticomedullary distinction and a typical 1:3 cortex:medulla ratio. There is no evidence of focal perinephric inflammation or effusion. There is no evidence of pyelectasia, nephroliths, infarcts or hydroureter. Renal vasculature is normal.

WEIGHT

23 Pounds

The right kidney has a normal shape and size (4.54 cm). Overall echogenicity is normal with adequate corticomedullary distinction and a typical 1:3 cortex:medulla ratio. There is no evidence of focal perinephric inflammation or effusion. There is no evidence of pyelectasia, nephroliths, infarcts or hydroureter. Renal vasculature is normal.

INTERPRETED BY

Kathleen Sennello DVM,
MS, Diplomate ACVIM
(Small Animal Internal
Medicine)

Adrenal Glands

The left adrenal gland is normal in size measuring 0.53 cm at the caudal pole. It is observed in its normal position cranial to the left renal artery. It is normal in appearance (uniformly hypoechoic) and shape with no evidence of a mass effect.

HOSPITAL NAME

Parkville AH

The right adrenal gland is normal in size measuring 0.65 cm at the caudal pole. It is observed in its normal position between the cranial aspect of the right kidney and the caudal vena cava. It is normal in appearance (uniformly hypoechoic) and shape with no evidence of a mass effect.

REFERRING VET

Dr. Suter

Spleen

The spleen is subjectively normal in size, echotexture is homogenous, and the splenic capsule is smooth with no irregularities. The blood flow through the hilus and splenic parenchyma appears normal. No focal parenchymal abnormalities are visualized.

INVOICE

46141

Liver

The liver is subjectively normal in size, and hyperechoic with smooth peripheral margins. The parenchyma is heterogenous in echotexture with subtle, indistinct focal mottling. The visible portions of the vasculature and biliary tract appear normal. There are diffuse ill-defined hypoechoic nodules dispersed throughout the hepatic parenchyma. Additionally, there is a cystic structure visualized measuring 2.23 cm x 1.73 cm.

The gall bladder lumen is moderately distended. The wall of the gall bladder is not thickened and has a smooth mucosal surface. There is a moderate amount of non-organized echogenic debris. The cystic and common bile ducts are normal/not visible.

Gastrointestinal

The stomach contains minimal luminal contents. It measures at a normal thickness of <0.7cm with some variability due to the presence of rugal folds. The distinction of the gastric wall layers is adequate and there is no impression of reduced peristaltic activity. No masses or focal lesions were observed.

The visualized areas of duodenum, jejunum and ileum have a relatively uniform diameter with minimal fluid distension. Wall thickness is normal. Bowel loops follow a curvilinear path with distinct wall layering maintaining the typical 1:3 muscularis:mucosa layer ratio. Duodenum wall measures 0.32 cm. Jejunum wall measures 0.25 cm. Visualized peristalsis appears appropriate. There were no focal lesions consistent with obstruction or a mass effect observed.

The ileocecal junction was visualized and exhibited normal intact wall layering and is subjectively of normal thickness. Sections of colon are visualized with formed fecal material and gas shadowing distally. There is no observed focal or generalized colon wall thickening or loss of layering.

Pancreas

The area of the pancreas is normal and isoechoic to surrounding mesentery. There is no evidence of nodules or cystic lesions. There is no evidence of regional mesenteric inflammation or fluid.

Free Abdomen

Evaluation of the peritoneal cavity did not reveal any evidence of effusion, or subjective lymphadenomegaly. The Medial iliac nodes appear normal and there was no evidence of a caudal aortic thrombus at the bifurcation. The omentum is of normal uniform echogenicity.

ULTRASONOGRAPHIC FINDINGS

- Hyperechoic liver with diffuse hyperechoic nodules – The significance of these lesions is unclear, but the appearance trends towards a more benign etiology. Strongly recommend a fine needle aspirate (provided coagulation parameters are normal).
- Moderate gallbladder debris – The significance of the aggregated gallbladder debris is unclear. This could represent an early mucocele, cholestasis, or may be secondary to fasting but seems unlikely to be causing a current issue. Recommend continued monitoring.

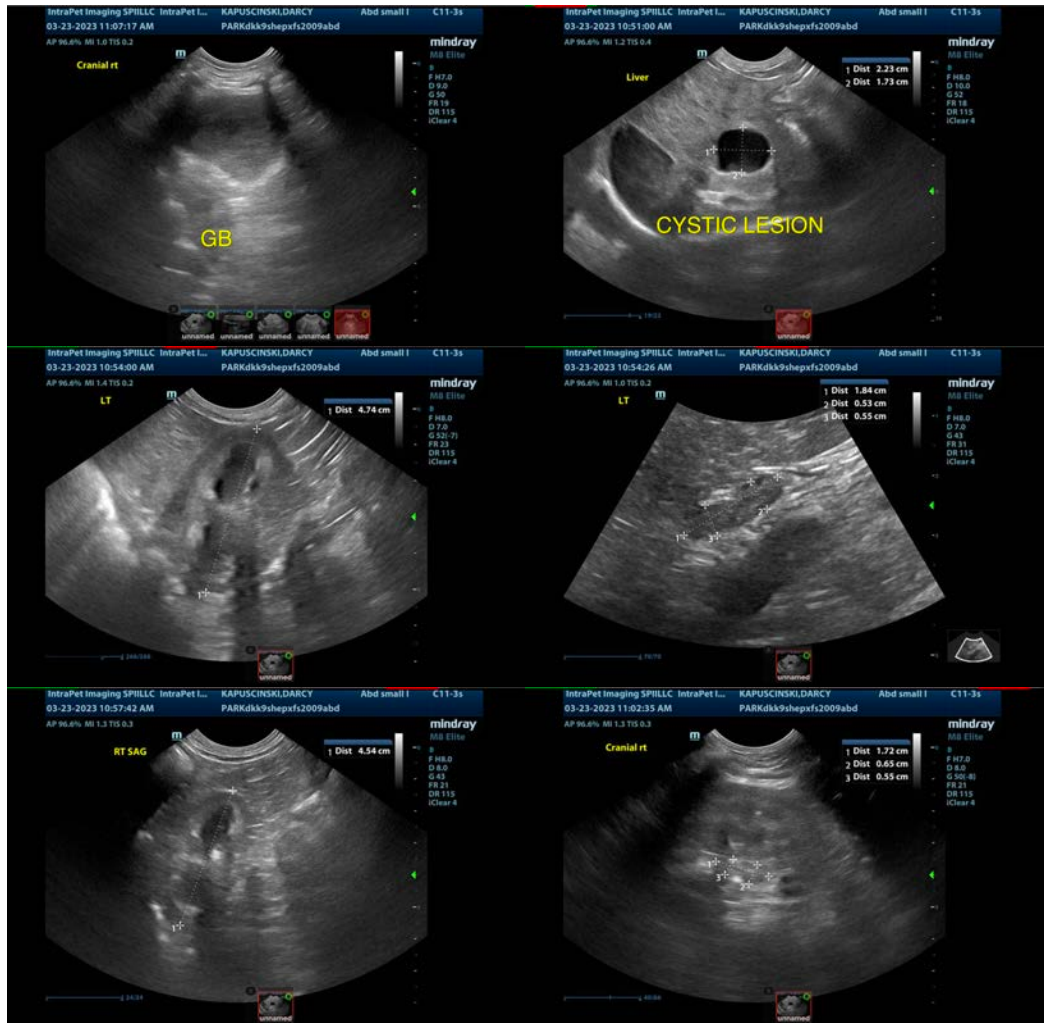
INTERPRETATION OF THE FINDINGS & FURTHER RECOMMENDATIONS

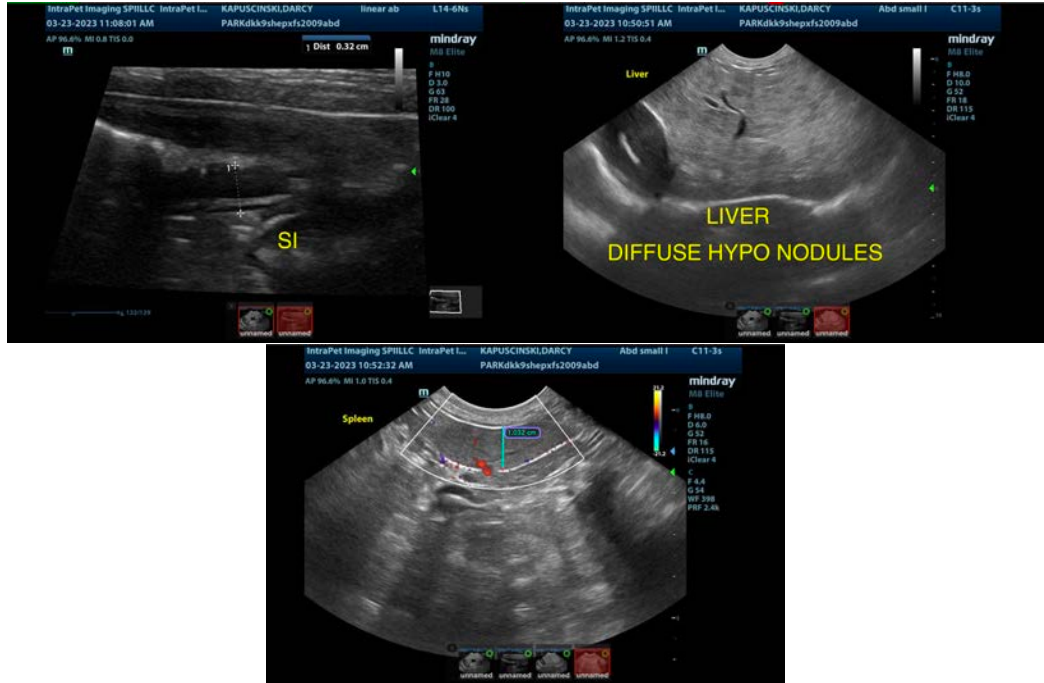
The liver is diffusely nodular. These lesions could represent a benign or neoplastic process. Strongly recommend a fine needle aspirate of the liver. These are additional recommendations/considerations:

- Consider close evaluation of history for possible toxic changes examine medications, diet, dietary indiscretion etc...
- Consider PCR on urine/serum for leptospirosis (if not on antibiotics)/serology if recent antibiotic history
- If not already done, consider pre and post prandial bile acids to evaluate liver function

- Consider Fine needle aspirate if round cell neoplasia is on your differential list (25 g needle, normal coags)
- If no response to supportive care (Denamarin, fluids, antibiotics, +/- ursodiol etc.) Consider liver biopsy with samples obtained for histopathology, culture, and copper levels.

Recommend three view thoracic radiographs to evaluate for possible concurrent thoracic disease/involvement.





The information and recommendations provided are based on the images presented by the referring veterinarian/sonographer. No evaluation can be communicated regarding pathology that was not visible in the image/video clips provided.

Thank you for this referral. If the clinical or image interpretation does not parallel your findings or if I can be of any further assistance please contact me.

Kathleen Sennello DVM,MS, Diplomate ACVIM (Small animal Internal Medicine)
kathleen.sennello@sonopath.com