



PATIENT

Wink Burke

SPECIES

Feline

BREED

DSH

SEX

Neutered Male

AGE

6 Years

WEIGHT

10.8 Pounds

INTERPRETED BY

Kathleen Sennello DVM,
MS, Diplomate ACVIM
(Small Animal Internal
Medicine)

**IMAGING
PERFORMED BY**

Dr. Sorbo

HOSPITAL NAME

Back Bay VC

REFERRING VET

Dr. Sorbo

INVOICE

36384

DATE

3/23/22

PRESENTING CLINICAL SIGNS

V/D in December may or may not be related to new diet. Since been fine since returning to normal diet. However, ongoing unexplained weight loss.

Abnormal PE/Chem/CBC/UA Results: Medium FAS case (fear anxiety stress). Exam largely nsf expect ongoing weight loss: May 2021: 12.92lbs Today: 10.84lbs.

ULTRASONOGRAPHIC EXAMINATION OF THE ABDOMEN

Urinary System

The urinary bladder is moderately distended with anechoic urine. The Bladder wall, trigone, ureteral papillae and visible urethra (to a depth of 2cm) appear normal with no evidence of wall thickening, mucosal irregularities, masses or cystic calculi.

The left kidney has a normal shape and size (3.75 cm). Overall echogenicity is normal with adequate corticomedullary distinction and a typical 1:3 cortex:medulla ratio. There is no evidence of perinephric inflammation or effusion. There is no evidence of pyelectasia, nephroliths, infarcts or hydroureter. Renal vasculature is normal.

The right kidney has a normal shape and size (3.73 cm). Overall echogenicity is normal with adequate corticomedullary distinction and a typical 1:3 cortex:medulla ratio. There is no evidence of perinephric inflammation or effusion. There is no evidence of pyelectasia, nephroliths, infarcts or hydroureter. Renal vasculature is normal.

Adrenal Glands

The left adrenal gland is normal in size measuring 0.23 cm at the caudal pole. It is observed in its normal position cranial to the left renal artery. It is normal in appearance (uniformly hypoechoic) and shape with no evidence of a mass effect.

The right adrenal gland is normal in size measuring 0.34 cm at the caudal pole. It is observed in its normal position between the cranial aspect of the right kidney and the caudal vena cava. It is normal in appearance (uniformly hypoechoic) and shape with no evidence of a mass effect.

Spleen

The spleen is subjectively normal in size, echotexture is homogenous, and the splenic capsule is smooth with no irregularities. The blood flow through the hilus and splenic parenchyma appears normal. No definitive focal splenic lesions are visualized. There are three hypoechoic cystic appearing lesions visualized medial to the head of the spleen. I suspect these are omental or pancreatic lesions, but splenic lesions cannot be excluded as a possibility.

Liver

The liver is subjectively normal in size, and echogenicity with smooth peripheral margins. The parenchyma is heterogenous in echotexture with subtle, indistinct focal mottling. The visible portions of the vasculature and biliary tract appear normal. No focal nodules or cystic lesions are observed.

The gallbladder lumen is moderately distended. The wall of the gall bladder is not thickened and has a smooth mucosal surface. Luminal contents are primarily anechoic. The cystic and common bile ducts are normal/not visible.



PATIENT

Gastrointestinal

Wink Burke

The stomach contains minimal luminal contents. It measures at a normal thickness of <0.36cm with some variability due to the presence of rugal folds. The distinction of the gastric wall layers is adequate and there is no impression of reduced peristaltic activity. No masses or focal lesions were observed.

SPECIES

Feline

The visualized areas of duodenum, jejunum and ileum have a relatively uniform diameter with minimal fluid distension. Wall thickness is normal. Bowel loops follow a curvilinear path with distinct wall layering maintaining the typical 1:3 muscularis:mucosa layer ratio. The duodenum measured as normal (between 0.13-0.38cm in wall thickness) and the jejunum measured as normal (between 0.15-0.36cm.) Visualized peristalsis appears appropriate. There were no focal lesions consistent with obstruction or a mass effect observed.

BREED

DSH

SEX

Neutered Male

The ileocecal junction was visualized and exhibited normal intact wall layering and is subjectively of normal thickness. Sections of colon are visualized with formed fecal material and gas shadowing distally. There is no observed focal or generalized colon wall thickening or loss of layering.

Pancreas

AGE

6 Years

The pancreas is prominent and hypoechoic as compared to the surrounding isoechoic mesentery in the area caudal to the stomach (body of the pancreas). There are no definitive focal lesions observed, although there are some cystic hypoechoic nodules visualized in the left cranial abdomen medial to the splenic head, which could be associated with the pancreas. There is no evidence of regional mesenteric inflammation or fluid.

WEIGHT

10.8 Pounds

Free Abdomen

Evaluation of the peritoneal cavity did not reveal any evidence of effusion. There is no definitive lymph node enlargement noted. There are three hypoechoic lesions in the left cranial abdomen measuring 0.74, 0.52, and 0.40 cm. These are located medial to the head of the spleen in the region of the pancreas and appear to have hyperechoic mesentery surrounding. These could be consistent with cystic lymph nodes, pancreatic cysts, or splenic lesions. The omentum is generally of normal echogenicity.

INTERPRETED BY

Kathleen Sennello DVM,
MS, Diplomate ACVIM
(Small Animal Internal
Medicine)

ULTRASONOGRAPHIC FINDINGS

IMAGING PERFORMED BY

Dr. Sorbo

- Hypoechoic, prominent pancreas – The pancreatic changes are most consistent with mild pancreatitis or a recent episode of pancreatic inflammation.
- Three hypoechoic, likely cystic structures in the left cranial abdomen – These lesions could be consistent with cystic lymph nodes, splenic lesions, or pancreatic lesions.
- Heterogeneous liver – Hepatic changes are non-specific and could be consistent with inflammation/infection (cholangiohepatitis), infiltrative neoplasia, lipidosis or other hepatopathy.

HOSPITAL NAME

Back Bay VC

REFERRING VET

Dr. Sorbo

INTERPRETATION OF THE FINDINGS & FURTHER RECOMMENDATIONS

No focal lesions are visualized associated with the gastrointestinal tract. The pancreas does appear prominent and hypoechoic. Consider a GI panel to Texas A&M for a qualitative fPLI, TLI, cobalamin and folate to further evaluate the pancreas and small intestine.

INVOICE

36384

There are three small hypoechoic structures visualized medial to the head of the spleen in the left cranial abdomen. These lesions appear to be surrounded by a small amount of hyperechoic mesentery. Possible differentials would be splenic lesions, cystic lymph nodes, or pancreatic tissue. For now, consider continued monitoring with ultrasound, treatment for pancreatitis, and additional

DATE

3/23/22



PATIENT

Wink Burke

workup/treatment, and re-evaluation of the abnormal tissue in 2-6 weeks (sooner if not doing well). If the lesions are persistent, a fine needle aspirate could be considered. It is not uncommon to have underlying gastrointestinal disease with minimal ultrasonographic lesions.

SPECIES

Feline

- Consider a novel protein/hydrolyzed protein prescription diet.
- Consider chronic probiotic therapy.

BREED

DSH

- Consider the aforementioned GI panel.

SEX

Neutered Male

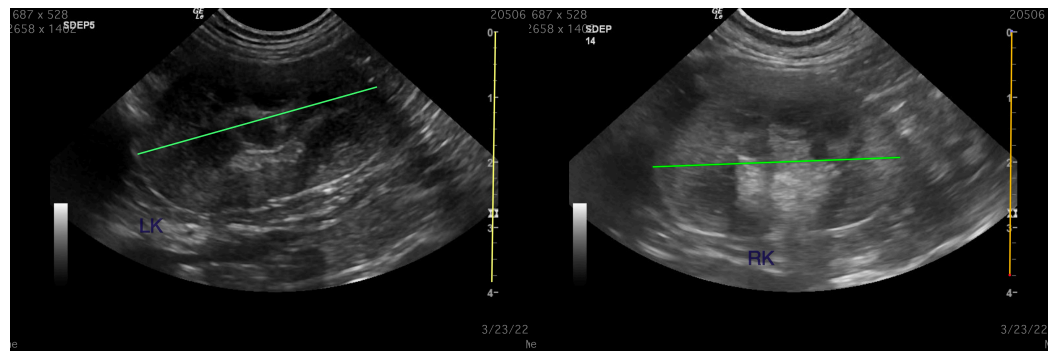
- If symptoms persist and primary GI disease is suspected, recommend intestinal biopsies (biopsies of the small intestine could be combined with evaluation of the abnormal tissue in the left cranial abdomen).

AGE

6 Years

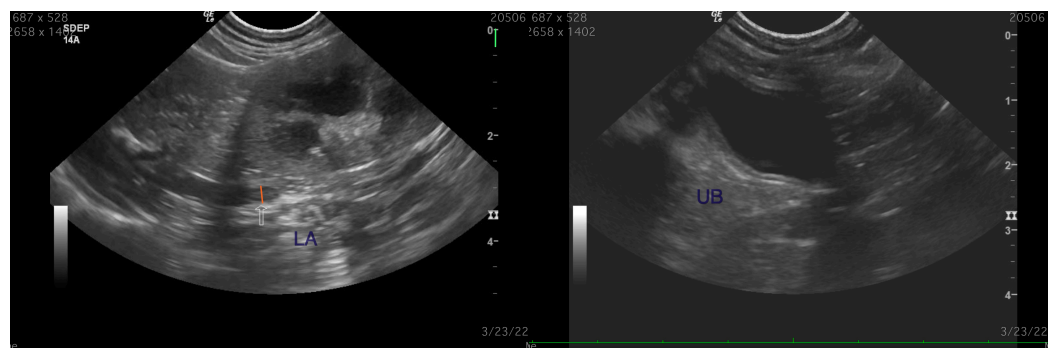
WEIGHT

10.8 Pounds



INTERPRETED BY

Kathleen Sennello DVM, MS, Diplomate ACVIM (Small Animal Internal Medicine)

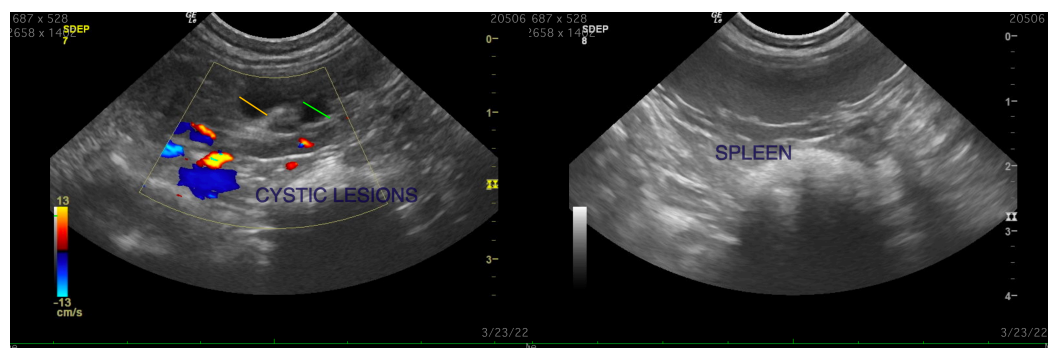


IMAGING PERFORMED BY

Dr. Sorbo

HOSPITAL NAME

Back Bay VC



REFERRING VET

Dr. Sorbo

INVOICE

36384

DATE

3/23/22



PATIENT

Wink Burke

SPECIES

Feline

BREED

DSH

SEX

Neutered Male

AGE

6 Years

WEIGHT

10.8 Pounds

INTERPRETED BY

Kathleen Sennello DVM,
MS, Diplomate ACVIM
(Small Animal Internal
Medicine)

**IMAGING
PERFORMED BY**

Dr. Sorbo

HOSPITAL NAME

Back Bay VC

REFERRING VET

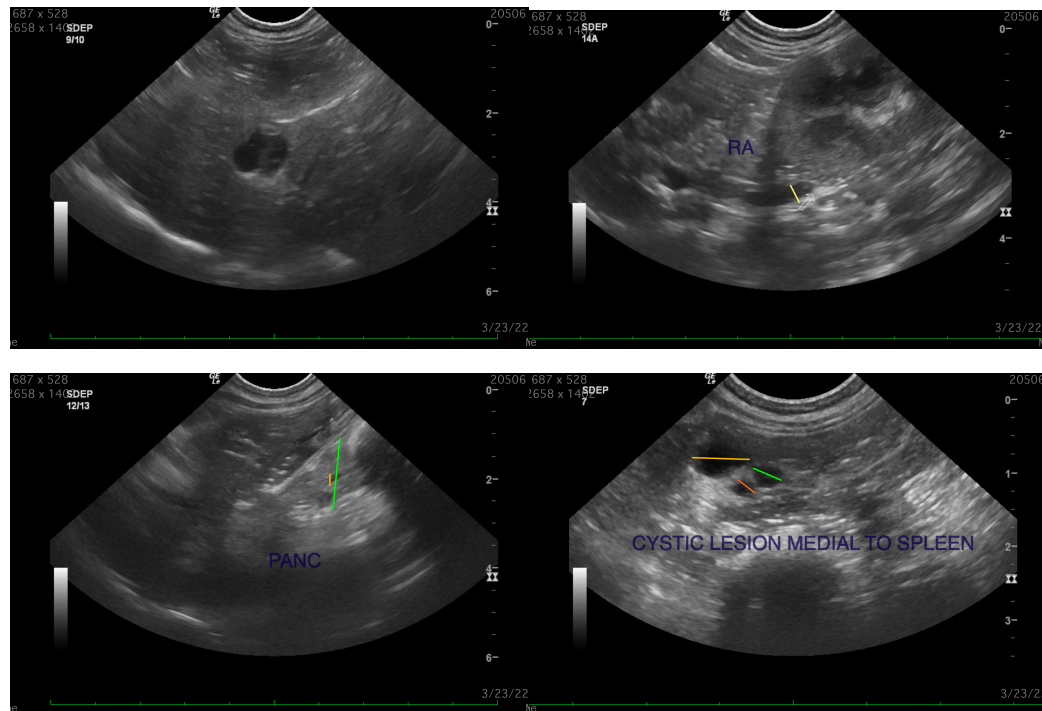
Dr. Sorbo

INVOICE

36384

DATE

3/23/22



The information and recommendations provided are based on the images presented by the referring veterinarian/sonographer. No evaluation can be communicated regarding pathology that was not visible in the image/video clips provided.

Thank you for this referral. If the clinical or image interpretation does not parallel your findings or if I can be of any further assistance please contact me.

Kathleen Sennello DVM,MS, Diplomate ACVIM (Small animal Internal Medicine)

kathleen.sennello@sonopath.com