**PATIENT**

Chip Jennings

SPECIES

Canine

BREED

Bichon Frise

SEX

Neutered Male

AGE

14 Years

WEIGHT

28 Pounds

INTERPRETED BYKathleen Sennello DVM,
MS, Diplomate ACVIM
(Small Animal Internal
Medicine)**IMAGING
PERFORMED BY**

Amy Mayhew, LVT

HOSPITAL NAME

SVS Imaging MI

REFERRING VETWixom Family Pet
Practice**INVOICE**

36381

DATE

3/23/22

PRESENTING CLINICAL SIGNS

Presents for lethargy and vomiting 2 days ago. Seemed uncomfortable. These signs have improved with outpatient care. Areas of possible skin infection in inguinal area and other parts of the abdomen. Abnormal PE/Chem/CBC/UA Results: See attached BW. UA showed USG 1.025 pH 6.5 and trace protein. Sediment: rare WBC, 3-7 RBC/hpf (cysto), epi cells. No bacterial

ULTRASONOGRAPHIC EXAMINATION OF THE ABDOMEN**Urinary System**

The urinary bladder is moderately distended with anechoic urine. The Bladder wall, trigone, ureteral papillae and visible urethra (to a depth of 2cm) appear normal with no evidence of wall thickening, mucosal irregularities, masses or cystic calculi.

The prostate is normal in size (1.0 cm) and shape for this neutered male dog. The parenchyma is homogenous and the external margins are smooth. The prostatic urethra appears normal with no evidence of irregularity, invasion, mass effect or calculi.

The left kidney has a normal shape and size (5.76 cm) with mild pyelectasia at 0.32 cm. Overall echogenicity is normal with adequate corticomedullary distinction and a typical 1:3 cortex:medulla ratio. There is no evidence of perinephric inflammation or effusion. There is no evidence of nephroliths, infarcts or hydroureter. Renal vasculature is normal.

The right kidney has a normal shape and size (5.28 cm) with mild pyelectasia at 0.42 cm and a small cortical cyst at 0.46 cm. Overall echogenicity is normal with adequate corticomedullary distinction and a typical 1:3 cortex:medulla ratio. There is no evidence of perinephric inflammation or effusion. There is no evidence of nephroliths, infarcts or hydroureter. Renal vasculature is normal.

Adrenal Glands

The left adrenal gland is normal in size measuring 0.80 cm at the caudal pole. It is observed in its normal position cranial to the left renal artery. It is normal in appearance (uniformly hypoechoic) and shape with no evidence of a mass effect.

The right adrenal gland is normal in size measuring 0.52 cm at the caudal pole. It is observed in its normal position between the cranial aspect of the right kidney and the caudal vena cava. It is normal in appearance (uniformly hypoechoic) and shape with no evidence of a mass effect.

Spleen

The spleen is subjectively normal in size, echotexture is homogenous, and the splenic capsule is smooth with no irregularities. The blood flow through the hilus and splenic parenchyma appears normal. No focal parenchymal abnormalities are visualized.


Liver

The liver is subjectively normal in size, and echogenicity with smooth peripheral margins. The parenchyma is homogenous echotexture. The visible portions of the vasculature and biliary tract appear normal. No focal nodules or cystic lesions are observed.

The gallbladder lumen is moderately distended. The wall of the gall bladder is not thickened and has a smooth mucosal surface. Luminal contents are primarily anechoic. The cystic and common bile ducts are normal/not visible.

IMAGING PERFORMED BY

SVS Mobile Imaging MI 734-637-7711
svsimagingmi@gmail.com

**PATIENT**

Chip Jennings

SPECIES

Canine

BREED

Bichon Frise

SEX

Neutered Male

AGE

14 Years

WEIGHT

28 Pounds

INTERPRETED BY

Kathleen Sennello DVM,
MS, Diplomate ACVIM
(Small Animal Internal
Medicine)

IMAGING PERFORMED BY

Amy Mayhew, LVT

HOSPITAL NAME

SVS Imaging MI

REFERRING VET

Wixom Family Pet
Practice

INVOICE

36381

DATE

3/23/22

Gastrointestinal

The stomach contains minimal luminal contents. It measures at a normal thickness of <0.7cm with some variability due to the presence of rugal folds. The distinction of the gastric wall layers is adequate and there is no impression of reduced peristaltic activity. No masses or focal lesions were observed.

The visualized areas of duodenum, jejunum and ileum have a relatively uniform diameter with minimal fluid distension. Wall thickness is normal. Bowel loops follow a curvilinear path with distinct wall layering maintaining the typical 1:3 muscularis:mucosa layer ratio. Duodenum wall measured 0.42 cm. Jejunum wall measured 0.29 cm. Visualized peristalsis appears appropriate. There were no focal lesions consistent with obstruction or a mass effect observed.

The ileocecal junction was visualized and exhibited normal intact wall layering and is subjectively of normal thickness. Sections of colon are visualized with formed fecal material and gas shadowing distally. There is no observed focal or generalized colon wall thickening or loss of layering.

Pancreas

The pancreas is normal and isoechoic to surrounding mesentery. There is no evidence of nodules or cystic lesions. There is no evidence of regional mesenteric inflammation or fluid.

Free Abdomen

Evaluation of the peritoneal cavity did not reveal any evidence of effusion. There is no evidence of typical appearing lymph node enlargement in the abdomen. There is a somewhat irregular hypoechoic structure at the bifurcation measuring 1.8 cm x 0.79 cm. This lesion almost appears cystic, as it is very hypoechoic. An irregular lymph node is also possible.

Additionally, there are two hypoechoic, slightly cystic appearing ovoid structures in the area of the left and right ovary. The structure on the right side is 1.0 cm x 2.1 cm. The structure on the left is 0.79 cm x 2.1 cm. These structures could represent lymphoid tissue, cystic omental tissue, or ovarian tissue.

The omentum is of normal echogenicity.

ULTRASONOGRAPHIC FINDINGS


- Mild bilateral renal pyelectasia – Pyelectasia of the left/right kidney could be consistent with pyelonephritis, chronic renal disease, secondary to PU/PD or fluid therapy (if applicable), other.
- Mild gallbladder debris – There is mild gallbladder debris visualized with no apparent wall thickening or inflammation. This is likely an incidental finding.
- Cystic structure in the area of the iliac trifurcation – The significance of this is unclear, as it could represent a prominent lymph node or an incidental finding. Recommend continued monitoring and evaluation of the rectal and perianal areas.
- Questionable ovoid structures in the areas of the ovaries – Possible differentials include cystic omental tissue, ovarian tissue, lymphoid tissue, etc.

INTERPRETATION OF THE FINDINGS & FURTHER RECOMMENDATIONS

No focal lesions are visualized associated with the GI tract to explain the lethargy and vomiting reported. Hopefully this is an episode of acute gastroenteritis, as per the history, this patient is responding to symptomatic therapy. If symptoms persist, consider further evaluation for pancreatitis with a PLI test and workup for underlying gastrointestinal disease.

IMAGING PERFORMED BY

SVS Mobile Imaging MI SVS 734-637-7711
svsimagingmi@gmail.com



PATIENT

Chip Jennings

There is mild pyelectasia visualized in both kidneys. This could represent PU/PD, pyelonephritis, etc. Recommend urinalysis and culture.

SPECIES

Canine

There are a few questionable hypoechoic, ovoid structures within the abdomen. One is visualized at the iliac trifurcation, which could be a prominent lymph node. Recommend digital rectal exam to evaluate the anal glands, and continued monitoring of this structure, as a fine needle aspirate would be very difficult at this time.

BREED

Bichon Frise

Additionally, there are two somewhat cystic, hypoechoic appearing ovoid structures in the areas of what could be ovaries. Correlate these findings with history (what age was patient neutered, and is there normal male genitalia present?). Consider if there have been any signs of estrus. Most intersex dogs have some form of abnormal external genitalia (hypospadias). If additional concern exists, consider consulting with a veterinary reproductive specialist.

SEX

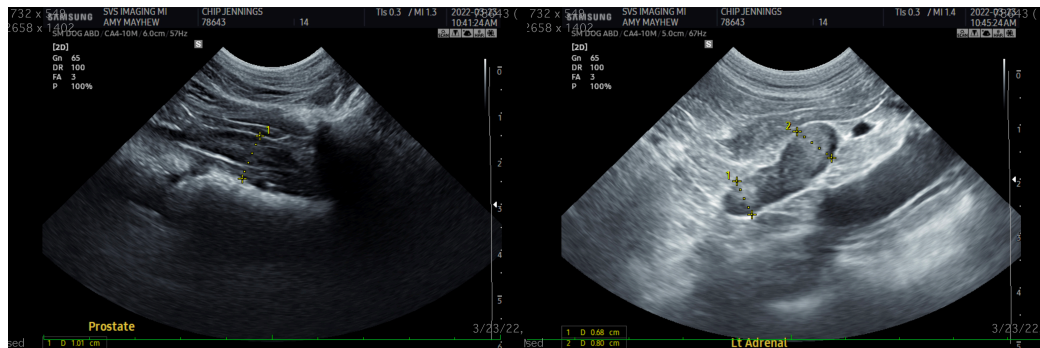
Neutered Male

AGE

14 Years

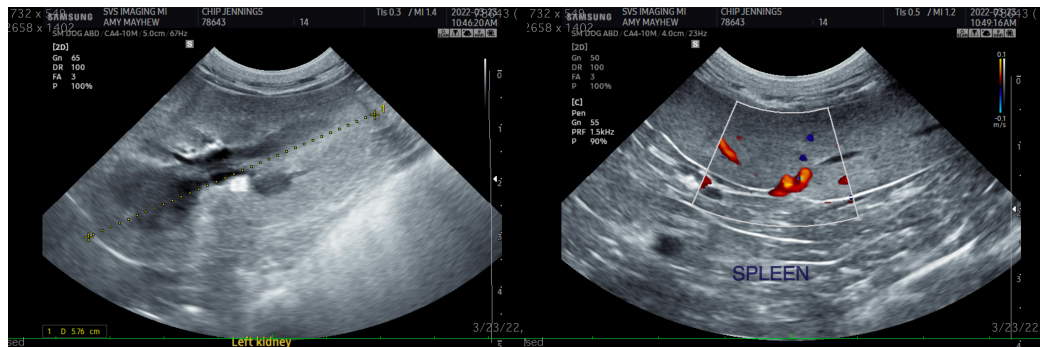
WEIGHT

28 Pounds



INTERPRETED BY

Kathleen Sennello DVM, MS, Diplomate ACVIM (Small Animal Internal Medicine)

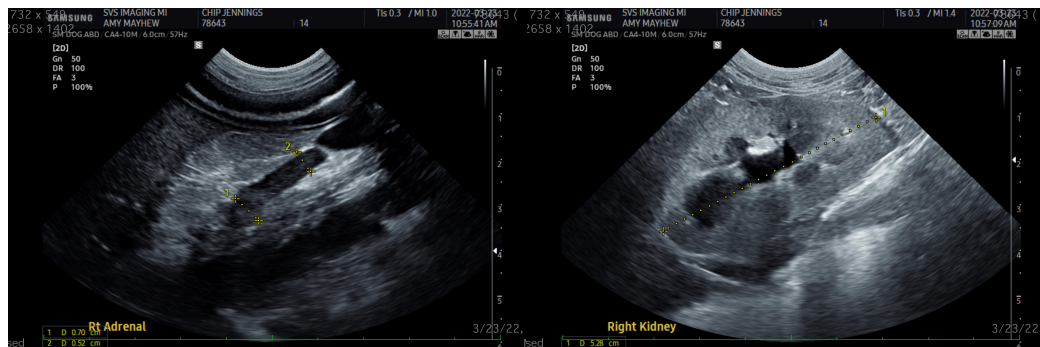


IMAGING PERFORMED BY

Amy Mayhew, LVT

HOSPITAL NAME

SVS Imaging MI



REFERRING VET

Wixom Family Pet Practice

INVOICE


36381

DATE

3/23/22

IMAGING PERFORMED BY

SVS Mobile Imaging MI 734-637-7711
svsimagingmi@gmail.com



PATIENT

Chip Jennings

SPECIES

Canine

BREED

Bichon Frise

SEX

Neutered Male

AGE

14 Years

WEIGHT

28 Pounds

INTERPRETED BY

Kathleen Sennello DVM,
MS, Diplomate ACVIM
(Small Animal Internal
Medicine)

**IMAGING
PERFORMED BY**

Amy Mayhew, LVT

HOSPITAL NAME

SVS Imaging MI

REFERRING VET

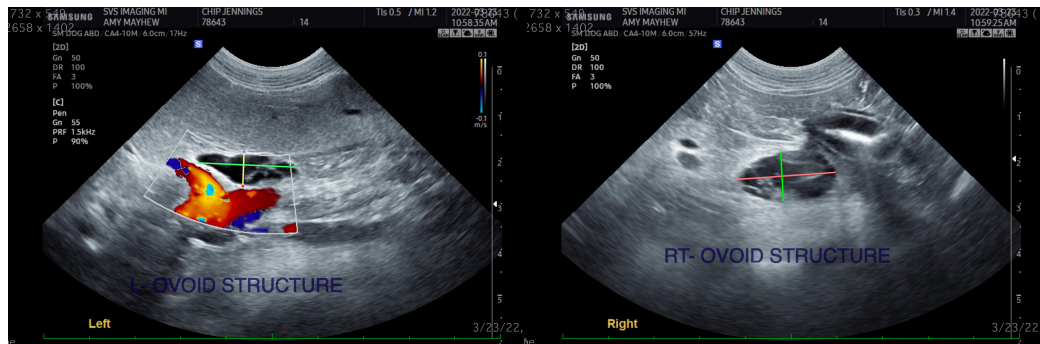
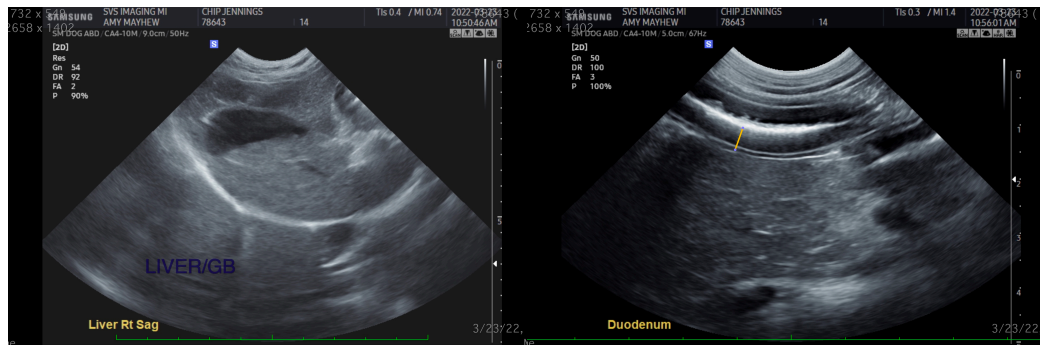
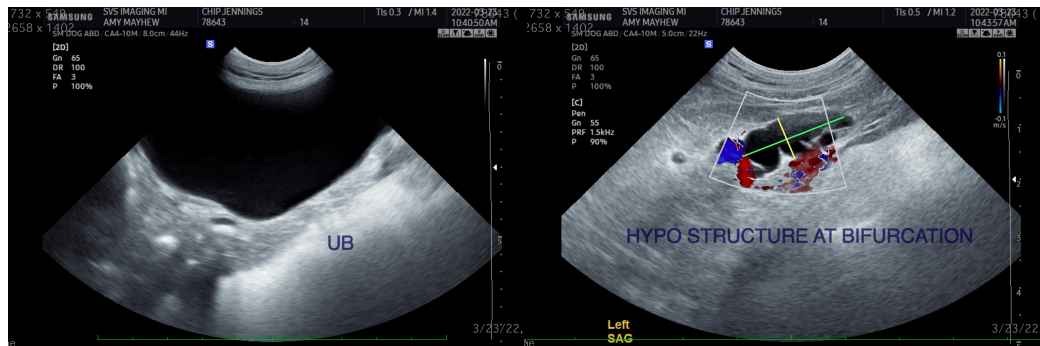
Wixom Family Pet
Practice

INVOICE

36381

DATE

3/23/22



The information and recommendations provided are based on the images presented by the referring veterinarian/sonographer. No evaluation can be communicated regarding pathology that was not visible in the image/video clips provided.

Thank you for this referral. If the clinical or image interpretation does not parallel your findings or if I can be of any further assistance please contact me.

Kathleen Sennello DVM,MS, Diplomate ACVIM (Small animal Internal Medicine)

kathleen.sennello@sonopath.com