

**DATE PRESENTING CLINICAL SIGNS**

3/22/23 Inappetence for three days, one episode of vomiting yesterday morning. Suspicion for foreign body on rads/rad consult.

PATIENT

Tala Cox Current Medications: None listed.
Radiographs: Gas in small intestines. Possible mineral opacity in small intestines.
Date of Previous IntraPet Ultrasound: No previous.

SPECIES

Feline Sedation: Not required to complete full diagnostic ultrasound.
Stat Report: Not requested.
Imaging Performed By: Rachel Brillhart, RDMS.

BREED

DSH

SEX

Spayed Female

AGE

8/5/22

WEIGHT

6 Pounds

INTERPRETED BY

Kathleen Sennello DVM,
MS, Diplomate ACVIM
(Small Animal Internal
Medicine)

HOSPITAL NAME

Northwind AH

REFERRING VET

Dr. Miller

INVOICE

46081

ULTRASONOGRAPHIC EXAMINATION OF THE ABDOMEN**Urinary System**

The urinary bladder is moderately distended with anechoic urine. The Bladder wall, trigone, ureteral papillae and visible urethra (to a depth of 2cm) appear normal with no evidence of wall thickening, mucosal irregularities, masses or cystic calculi.

The left kidney has a normal shape and size (2.97 cm). Overall echogenicity is normal with adequate corticomedullary distinction and a typical 1:3 cortex:medulla ratio. There is no evidence of focal perinephric inflammation or effusion. There is no evidence of pyelectasia, nephroliths, infarcts or hydroureter. Renal vasculature is normal.

The right kidney has a normal shape and size (3.12 cm). Overall echogenicity is normal with adequate corticomedullary distinction and a typical 1:3 cortex:medulla ratio. There is no evidence of focal perinephric inflammation or effusion. There is no evidence of pyelectasia, nephroliths, infarcts or hydroureter. Renal vasculature is normal.

Adrenal Glands

The region of left adrenal (Cranial to left renal artery) is unremarkable but the adrenal is not distinctly visualized. No evidence of a mass effect is visualized.

The right adrenal gland is normal in size measuring 0.40 cm at the caudal pole. It is observed in its normal position between the cranial aspect of the right kidney and the caudal vena cava. It is normal in appearance (uniformly hypoechoic) and shape with no evidence of a mass effect.

Spleen

The spleen is subjectively normal in size, echotexture is homogenous, and the splenic capsule is smooth with no irregularities. The blood flow through the hilus and splenic parenchyma appears normal. No focal parenchymal abnormalities are visualized.

Liver

The liver is subjectively normal in size, and echogenicity with smooth peripheral margins. The parenchyma is homogenous echotexture. The visible portions of the vasculature and biliary tract appear normal. No focal nodules or cystic lesions are observed.

The gallbladder lumen is moderately distended. The wall of the gall bladder is not thickened and has a smooth mucosal surface. Luminal contents are mild and primarily anechoic. The cystic and common bile ducts are normal/not visible.

Gastrointestinal

The stomach contains mild fluid. It measures at a normal thickness of <0.36cm with some variability due to the presence of rugal folds. The distinction of the gastric wall layers is adequate and there is no impression of reduced peristaltic activity. No masses or focal lesions were observed.

The visualized areas of duodenum, jejunum and ileum have a relatively uniform diameter with mild to moderate fluid distension. Wall thickness is normal. Bowel loops follow a curvilinear path with distinct wall layering maintaining the typical 1:3 muscularis:mucosa layer ratio. Jejunum wall measures 0.27 cm. Visualized peristalsis appears appropriate. There appears to be diffuse mild fluid distention in the small intestine with some areas of mildly shadowing ingesta and gas, but no point of obstruction is visualized.

The ileocecal junction was visualized and exhibited normal intact wall layering and is subjectively of normal thickness. Sections of colon are visualized with non-formed/liquid fecal material and gas shadowing distally. There is no observed focal or generalized colon wall thickening or loss of layering.

Pancreas

The pancreas is large and hypoechoic to surrounding mesentery. There is no evidence of nodules or cystic lesions. There is evidence of regional mesenteric inflammation. Consistent with mild pancreatitis.

Free Abdomen

Evaluation of the peritoneal cavity did not reveal any evidence of effusion. There are significantly prominent mesenteric lymph nodes visualized at the mesenteric root, measuring 0.63, 0.60, and 0.49 cm. The omentum is generally of normal echogenicity but is somewhat hyperechoic around the pancreas.

Other

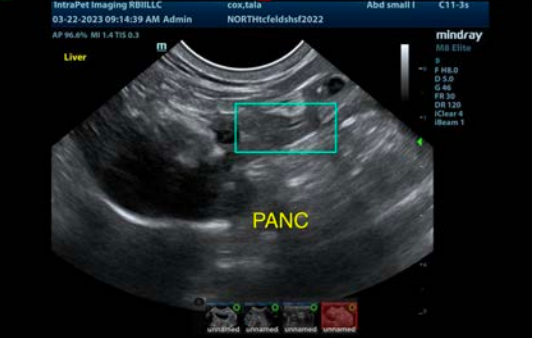
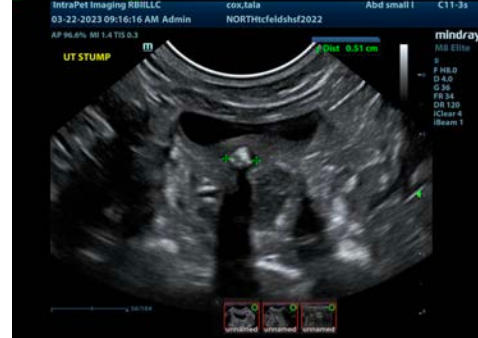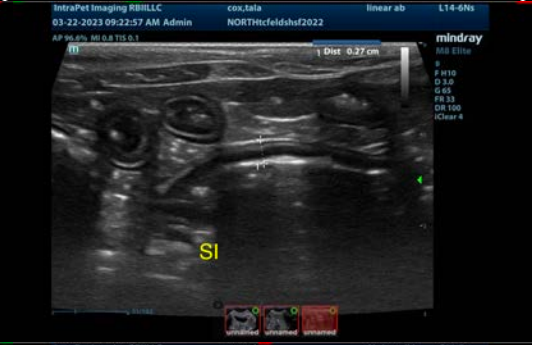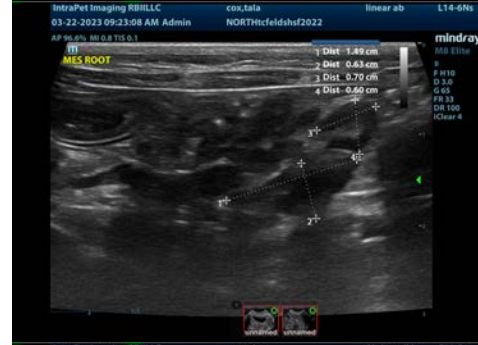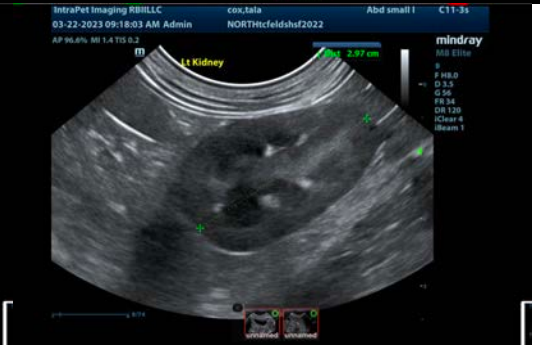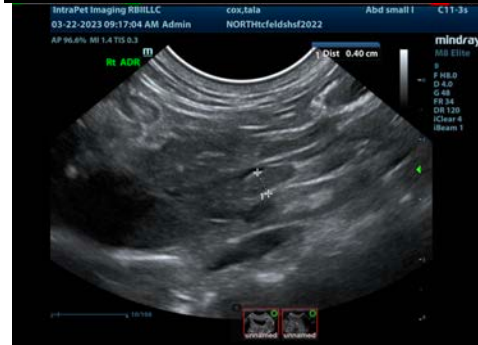
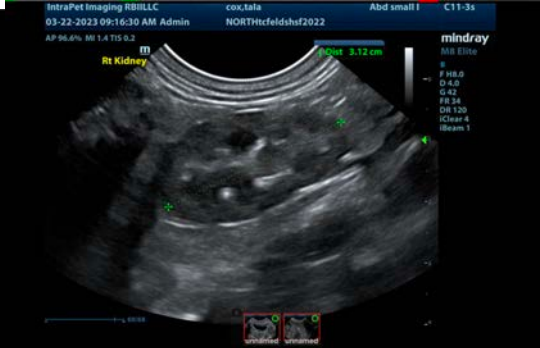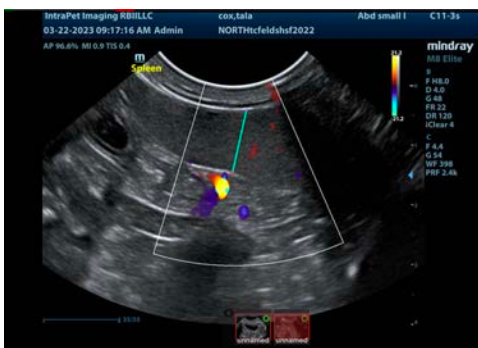The uterine stump is visualized and associated with hyperechoic shadowing material, most consistent with suture material. This is likely within normal limits.

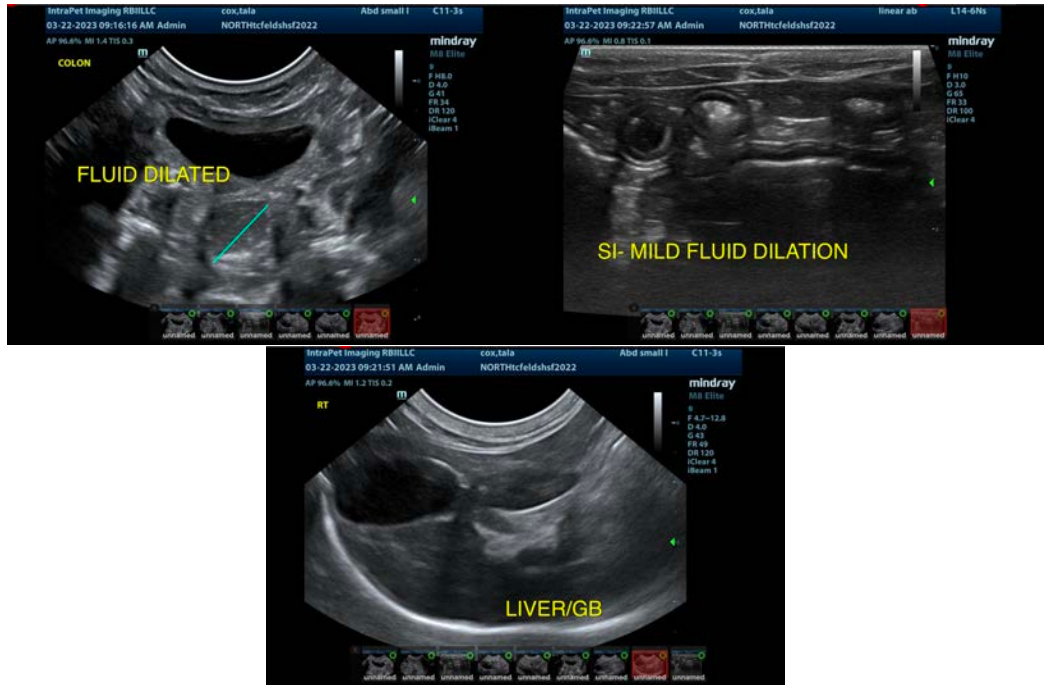
ULTRASONOGRAPHIC FINDINGS

- Hypoechoic, prominent pancreas with mild surrounding inflammation – The pancreatic changes are most consistent with mild pancreatitis/pancreatic inflammation. Recommend fPLI testing and continued monitoring for improvement or possible development of a pancreatic abscess. Consider fine needle aspirate if not improving.
- Diffuse mild fluid distention of the small intestine – Findings are most consistent with diffuse enteritis, although ingested foreign material cannot be definitively ruled out.
- Fluid distended colon – Findings are concerning for impending diarrhea.
- Mild mesenteric lymphadenopathy – The prominent abdominal lymph nodes are most consistent with reactive lymphadenitis or lymphoid hyperplasia. Neoplastic infiltration is considered less likely. This can be a normal finding in a young cat.

INTERPRETATION OF THE FINDINGS & FURTHER RECOMMENDATIONS

No focal obstruction is visualized on today's exam, but there is some fluid distention of the small bowel, so ingested foreign material could be possible. Recommend continued monitoring and treatment for diffuse enteritis/pancreatitis. The pancreas is somewhat prominent and has some mild inflammation surrounding. Correlate these findings with a quantitative fPLI level. Additionally, there is the impression of a fluid distended colon, which could indicate impending diarrhea, which is less likely for an obstructive process. Recommend close monitoring and serial imaging. If the patient is not improving or an obstructive pattern develops, then consider either exploratory or repeat ultrasound.





The information and recommendations provided are based on the images presented by the referring veterinarian/sonographer. No evaluation can be communicated regarding pathology that was not visible in the image/video clips provided.

Thank you for this referral. If the clinical or image interpretation does not parallel your findings or if I can be of any further assistance please contact me.

Kathleen Sennello DVM,MS, Diplomate ACVIM (Small animal Internal Medicine)
kathleen.sennello@sonopath.com