

**DATE PRESENTING CLINICAL SIGNS**

3/22/22 Hx of pancreatitis.

PATIENT Current Medications: None listed. Gave buprenorphine prior to US.
Date of Previous IntraPet Ultrasound: 1/18/22. See attached.
Olive Matteo Sedation: Not required to complete full diagnostic ultrasound.
Stat Report: Declined.

SPECIES ULTRASONOGRAPHIC EXAMINATION OF THE ABDOMEN

Canine

Urinary System**BREED**

The urinary bladder is moderately distended with anechoic urine. The Bladder wall, trigone, ureteral papillae and visible urethra (to a depth of 2cm) appear normal with no evidence of wall thickening, mucosal irregularities, masses or cystic calculi.

Terrier X

SEX

The left kidney has a normal shape and size (4.77 cm). Overall echogenicity is slightly hyperechoic with slightly decreased corticomedullary distinction and a typical 1:3 cortex:medulla ratio. There is no evidence of perinephric inflammation or effusion. There is no evidence of pyelectasia, nephroliths, infarcts or hydroureter. Renal vasculature is normal.

Spayed Female

AGE

The right kidney has a normal shape and size (4.29 cm). Overall echogenicity is slightly hyperechoic with slightly decreased corticomedullary distinction and a typical 1:3 cortex:medulla ratio. There is no evidence of perinephric inflammation or effusion. There is no evidence of pyelectasia, nephroliths, infarcts or hydroureter. Renal vasculature is normal.

6/14/09

WEIGHT

25 Pounds

Adrenal Glands**INTERPRETED BY**

The left adrenal gland is normal in size measuring 0.53 cm at the caudal pole. It is observed in its normal position cranial to the left renal artery. It is normal in appearance (uniformly hypoechoic) and shape with no evidence of a mass effect.

Kathleen Sennello DVM,
MS, Diplomate ACVIM
(Small Animal Internal
Medicine)

The right adrenal gland is normal in size measuring 0.49 cm at the caudal pole. It is observed in its normal position between the cranial aspect of the right kidney and the caudal vena cava. It is normal in appearance (uniformly hypoechoic) and shape with no evidence of a mass effect.

IMAGING PERFORMED BY

Stephanie Pearce
RDMS, RVT

Spleen

The spleen is subjectively normal in size, echotexture is homogenous, and the splenic capsule is smooth with no irregularities. The blood flow through the hilus and splenic parenchyma appears normal. No focal parenchymal abnormalities are visualized.

HOSPITAL NAME**Liver**

The liver is subjectively normal in size and irregular in shape. The parenchyma is heterogenous in echotexture with subtle, indistinct focal mottling. The visible portions of the vasculature and biliary tract appear normal. There is a generalized mottling with ill-defined hypoechoic areas bordering on nodules. The right lobe of the liver appears to have a slightly smoother echotexture and rounded margins. Findings could be normal with normal anatomic variation or with an ill-defined right liver mass.

Homeward Bound Vet

REFERRING VET

Dr. Vance

INVOICE

36343

The gall bladder lumen is moderately distended. The wall of the gall bladder is not thickened and has a smooth mucosal surface. There is a mild amount of non-organized echogenic debris. The cystic and common bile ducts are normal/not visible. The proximal bile duct is not visualized, but at the level of the duodenal papilla there is a fluid filled anechoic structure, most consistent with a dilated distal bile duct measuring 0.80 cm in diameter. There is some sludgy mucoid material visualized, and no obvious mass effect.

Gastrointestinal

The stomach is mildly dilated with fluid and irregular shadowing material most consistent with normal ingesta and gas. It measures at a normal thickness of <0.7cm with some variability due to the presence of rugal folds. The distinction of the gastric wall layering is adequate and there is no impression of reduced peristaltic activity. No masses or focal lesions were observed.

The visualized areas of duodenum, jejunum and ileum have a relatively uniform diameter with minimal fluid distension. Wall thickness is normal. Bowel loops follow a curvilinear path with distinct wall layering maintaining the typical 1:3 muscularis:mucosa layer ratio. Duodenum wall measured 0.43 cm. Jejunum wall measured 0.38 cm. Visualized peristalsis appears appropriate. There were no focal lesions consistent with obstruction or a mass effect observed.

The ileocecal junction was visualized and exhibited normal intact wall layering and is subjectively of normal thickness. Sections of colon are visualized with formed fecal material and gas shadowing distally. There is no observed focal or generalized colon wall thickening or loss of layering.

Pancreas

The pancreas is large and hypoechoic to surrounding mesentery. The right limb of the pancreas appears hypoechoic and discrete, particularly adjacent to the duodenum. The left limb appears more mottled with ill-defined hypoechoic nodules and some cystic regions. There is evidence of regional mesenteric inflammation. Consistent with moderate pancreatitis.

Free Abdomen

Evaluation of the peritoneal cavity did not reveal any evidence of effusion, or subjective lymphadenomegaly. The Medial iliac nodes appear normal and there was no evidence of a caudal aortic thrombus at the bifurcation. The omentum is of increased echogenicity around the pancreas.

ULTRASONOGRAPHIC FINDINGS

- Prominent hypoechoic left limb of the pancreas with surrounding hyperechoic mesentery – The left limb of the pancreas appears irregular with occasional cystic/nodular areas. The pancreatic changes are most consistent with moderate pancreatitis/pancreatic inflammation. Recommend fPLI testing and continued monitoring for improvement or possible development of a pancreatic abscess. Consider fine needle aspirate if not improving. The pancreas appears more prominent than when last imaged 1/2022.
- Heterogeneous liver with rounded right liver lobe – The diffuse hepatic changes are non-specific and could be consistent with vacuolar hepatopathy, nodular hyperplasia, inflammatory/immune-mediated disease, fibrosis, extramedullary hematopoiesis, toxic hepatopathy (e.g., copper), infiltrative neoplasia (less likely) or other hepatopathy. The significance of the rounded right liver lobe is uncertain. This could represent normal anatomic variation or may be consistent with a subtle right liver mass. Consider fine needle aspirate.
- Dilated distal common bile duct – Dilation of the common bile duct could be consistent with a functional obstruction (i.e. primary hepatic disease resulting in hepatocellular swelling) or with an extrahepatic bile duct obstruction (ie. choledocholith, bile duct tumor, pancreatic disease, other). This could be consistent with the surrounding pancreatic inflammation.

SECONDARY FINDINGS

- Slightly decreased corticomedullary distinction in both kidneys – The bilateral renal findings are consistent with age-related change.

INTERPRETATION OF THE FINDINGS & FURTHER RECOMMENDATIONS

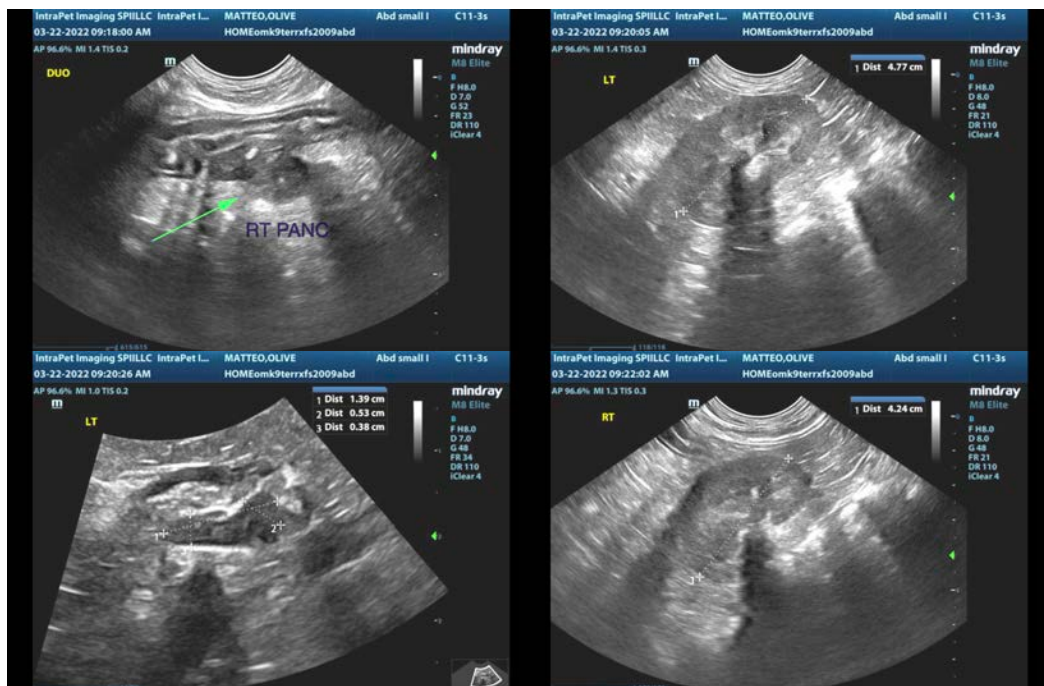
In today's scan, the pancreas appears more prominent and inflamed then in the scan performed 1/2022. The right lobe is discrete and hypoechoic, while the left lobe is mildly cystic and mottled. At this point, consider a fine needle aspirate of the left lobe of the pancreas due to the chronicity. Additionally, if not already done, recommend a GI panel with qualitative PLi, TLI, cobalamin and folate to further evaluate for the pancreatitis and for concurrent GI disease. If not already done, this patient should be on an ultra low-fat diet, chronic probiotic therapy, and medical treatment for pancreatitis. If any fluid is obtained from the fine needle aspirate, recommend fluid analysis, cytology, and possible culture (aerobic and anaerobic).

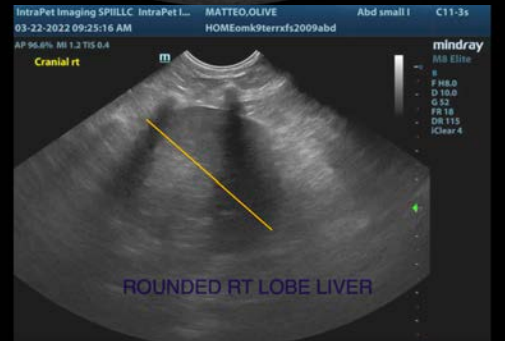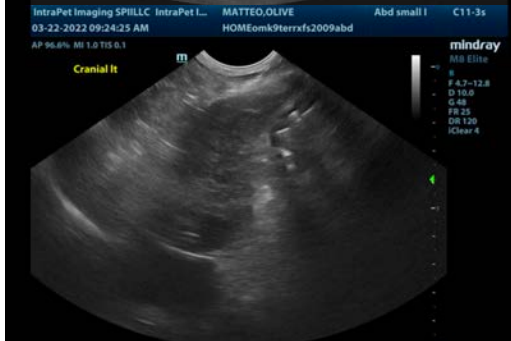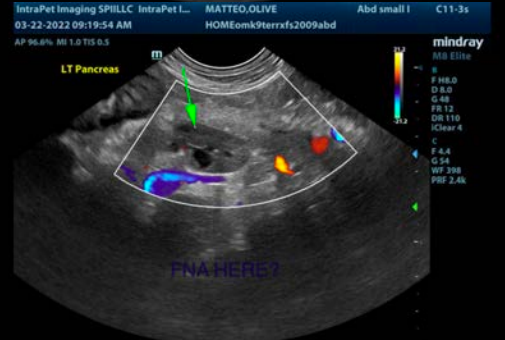
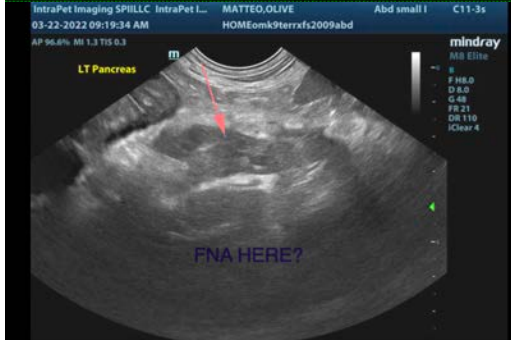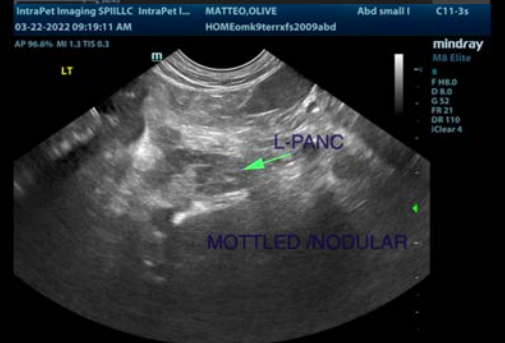
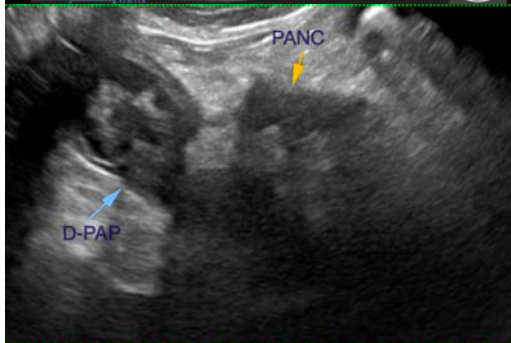
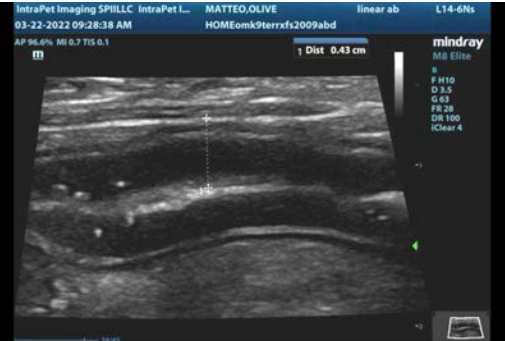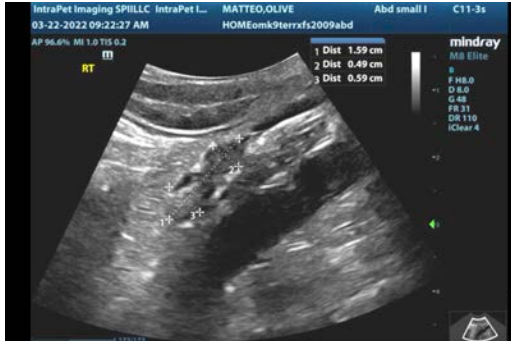The liver is persistently heterogeneous. Correlate this finding with liver values. Additionally, the right lobe appears rounded, almost creating a mass effect. Consider a fine needle aspirate of the liver, both the more heterogeneous left area, and the right rounded region for possible comparison.

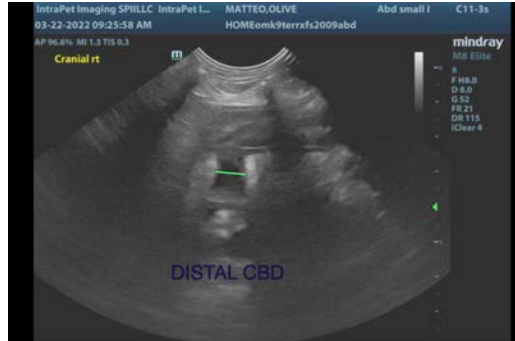The gallbladder and proximal common bile duct are difficult to visualize between rib spaces, but the distal bile duct adjacent to the duodenal papilla appears dilated and has some mucoid material. If liver enzyme elevations are present, consider treatment for cholecystitis, as well as starting Ursodiol therapy in the chance that this contributing to the development of pancreatitis.

If there is the suspicion that there is concurrent GI disease, consider obtaining GI biopsies to further evaluate.

If there is concern for a possible liver mass based on liver enzyme elevations, cytology, and radiographs, a contrast CT scan could be performed to better evaluate the liver as a whole to try to determine if this is an anatomic variation or a true mass effect.







The information and recommendations provided are based on the images presented by the referring veterinarian/sonographer. No evaluation can be communicated regarding pathology that was not visible in the image/video clips provided.

Thank you for this referral. If the clinical or image interpretation does not parallel your findings or if I can be of any further assistance please contact me.

Kathleen Sennello DVM,MS, Diplomate ACVIM (Small animal Internal Medicine)
kathleen.sennello@sonopath.com