

IMAGING PERFORMED BY

IntraPet.com



SonoPath

Clinical Sonography & Telecytology

EDUCATIONAL TELECONSULTATION SERVICES™

1-800-838-4268 info@sonopath.com SonoPath.com

DATE PRESENTING CLINICAL SIGNS

3/22/22

Referral from pet wellness center for jaundice, dehydration, inappetence, muscle wasting Hx of vomiting and diarrhea P had brief exam at rDVM, vitals not taken, diagnostics not performed, referred over for more extensive care – possible ultrasound ____ ATO: Rescued as a small kitten, bottle fed her and sister Indoor/outdoor Feb housemate missing, eating intermittently tried changing food- then stopped eating hard food 2 weeks after- wt loss noticeable, unsure if dental disease, drinking less water not obviously lethargic- still playing, not obviously painful This am vomited 2x wet cat food- no blood, urinated normally, runny stool this am (previously Normal) O has had increase stress in life- hospitalized october, november, late jan.

PATIENT

Luna Woods

SPECIES

Feline

Current Medications: None yet.
Date of Previous IntraPet Ultrasound: No previous.
Sedation: Not required to complete full diagnostic ultrasound.
Stat Report: Not requested.

BREED

DSH

ULTRASONOGRAPHIC EXAMINATION OF THE ABDOMEN

SEX

Spayed Female

Urinary System

The urinary bladder is moderately distended with anechoic urine. The Bladder wall, trigone, ureteral papillae and visible urethra (to a depth of 2cm) appear normal with no evidence of wall thickening, mucosal irregularities, masses or cystic calculi.

AGE

3/22/16

The left kidney has a normal shape and size (3.86 cm). Overall echogenicity is normal with adequate corticomedullary distinction and a typical 1:3 cortex:medulla ratio. There is no evidence of perinephric inflammation or effusion. There is no evidence of pyelectasia, nephroliths, infarcts or hydroureter. Renal vasculature is normal.

WEIGHT

10.8 Pounds

The right kidney has a normal shape and size (3.92 cm). Overall echogenicity is normal with adequate corticomedullary distinction and a typical 1:3 cortex:medulla ratio. There is no evidence of perinephric inflammation or effusion. There is no evidence of pyelectasia, nephroliths, infarcts or hydroureter. Renal vasculature is normal.

INTERPRETED BY

Kathleen Sennello DVM,
MS, Diplomate ACVIM
(Small Animal Internal
Medicine)

Adrenal Glands

The left adrenal gland is normal in size measuring 0.38 cm at the caudal pole. It is observed in its normal position cranial to the left renal artery. It is normal in appearance (uniformly hypoechoic) and shape with no evidence of a mass effect.

IMAGING PERFORMED BY

Rachel Brilhart RDMS

The region of the right adrenal (between right cranial kidney and vena cava) is unremarkable, but the adrenal is not distinctly visualized. No evidence of a mass effect.

HOSPITAL NAME

Animal Emergency
Hospital

Spleen

The spleen is subjectively normal in size, echotexture is homogenous, and the splenic capsule is smooth with no irregularities. The blood flow through the hilus and splenic parenchyma appears normal. No focal parenchymal abnormalities are visualized.

REFERRING VET

Dr. Kalwa

Liver

The liver is subjectively normal in size, and echogenicity with smooth peripheral margins. The parenchyma is heterogenous in echotexture with subtle, indistinct focal mottling. The visible portions of the vasculature and biliary tract appear normal. No focal nodules or cystic lesions are observed.

INVOICE

36360

The gallbladder lumen is moderately distended. The wall of the gall bladder is not thickened and has a smooth mucosal surface. Luminal contents are primarily anechoic. The cystic and common bile ducts are normal/not visible.

Gastrointestinal

The stomach contains minimal luminal contents. It measures at a normal thickness of <0.36cm with some variability due to the presence of rugal folds. The distinction of the gastric wall layers is adequate and there is no impression of reduced peristaltic activity. No masses or focal lesions were observed.

The visualized areas of duodenum, jejunum and ileum have a relatively uniform diameter with minimal fluid distension. Wall thickness is normal. Bowel loops follow a curvilinear path with distinct wall layering maintaining the typical 1:3 muscularis:mucosa layer ratio. Jejunum wall measured 0.30 cm. Visualized peristalsis appears appropriate. There were no focal lesions consistent with obstruction or a mass effect observed.

The ileocecal junction was visualized and exhibited normal intact wall layering and is subjectively of normal thickness. Sections of colon are visualized with formed fecal material and gas shadowing distally. There is no observed focal or generalized colon wall thickening or loss of layering.

Pancreas

The pancreas is prominent and mottled compared to the surrounding isoechoic mesentery. There is no evidence of nodules or cystic lesions. There is no evidence of regional mesenteric inflammation or fluid. Prominent pancreatic duct noted at 0.14 cm.

Free Abdomen

Evaluation of the peritoneal cavity did not reveal any evidence of effusion. Occasional prominent mesenteric lymph nodes are noted around the ileocecal junction, measuring 0.35, 0.34, and 0.37 cm. The omentum is of normal echogenicity.

ULTRASONOGRAPHIC FINDINGS

- Prominent, mottled pancreas – The pancreatic changes are most consistent with mild pancreatitis or a recent episode of pancreatic inflammation.
- Heterogeneous liver – The diffuse hepatic changes are non-specific and could be consistent with vacuolar hepatopathy, nodular hyperplasia, inflammatory/immune-mediated disease, fibrosis, extramedullary hematopoiesis, toxic hepatopathy (e.g., copper), infiltrative neoplasia (less likely) or other hepatopathy.

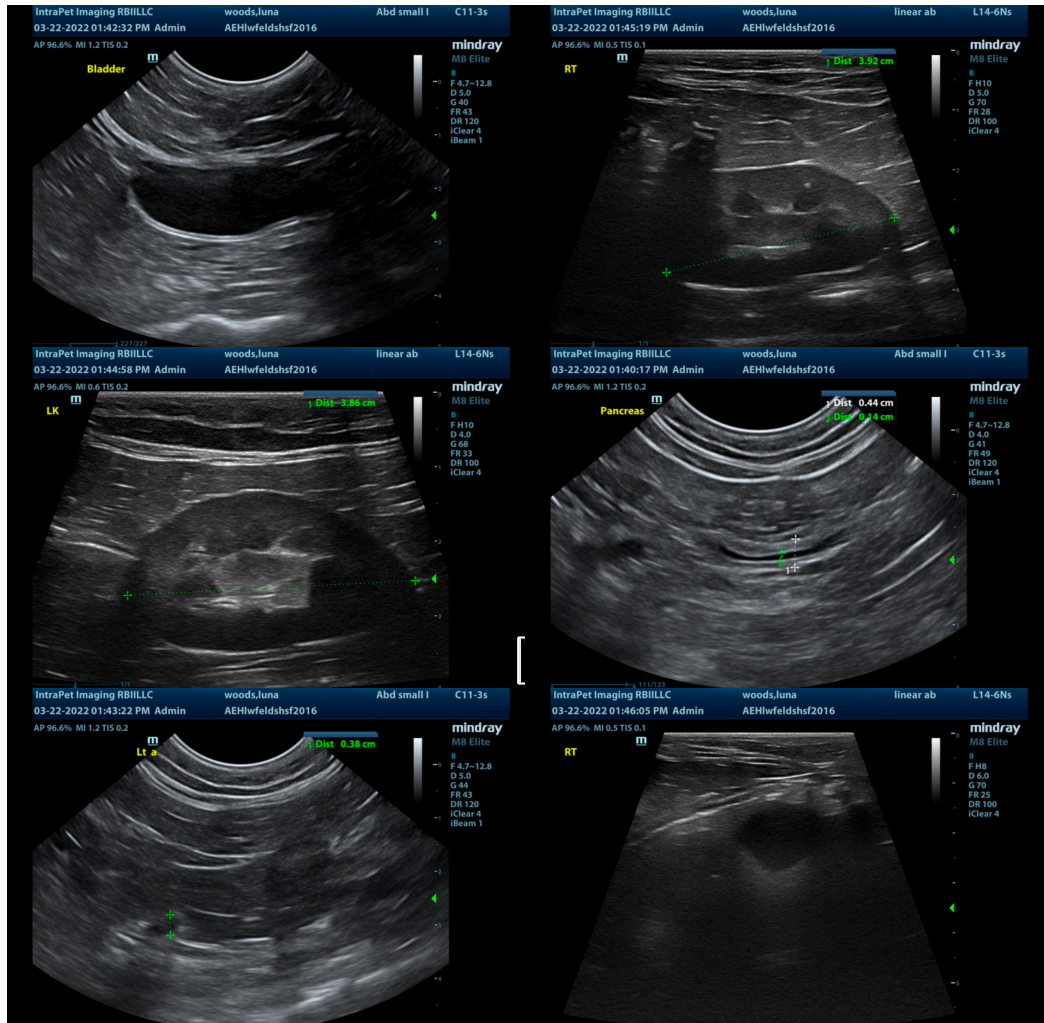
INTERPRETATION OF THE FINDINGS & FURTHER RECOMMENDATIONS

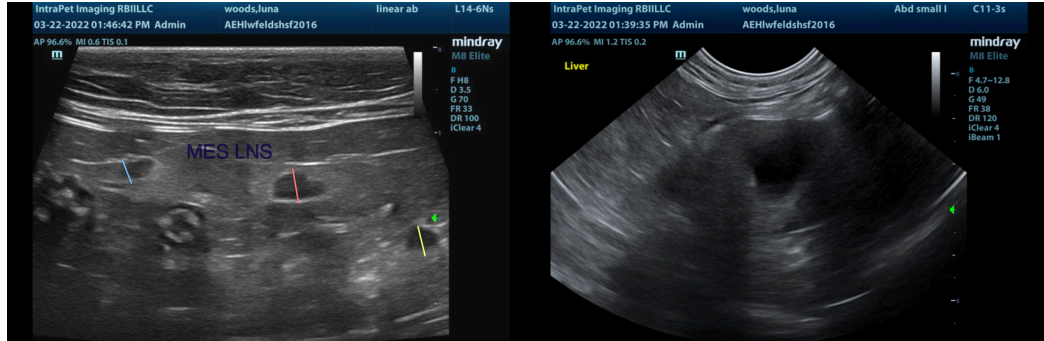
No focal lesions are observed associated with the liver, although the parenchyma appears slightly heterogeneous. There are no obvious lesions associated with the gallbladder. The gallbladder is primarily visualized intercostally, and there appears to be an irregular shape on some images, but no evidence of overt disease at this time.

The ultrasonographic changes in the liver were relatively non-specific. Unfortunately, there were also some mild changes to the biliary tract making it difficult to differentiate between a primary hepatopathy and a partial post hepatic biliary obstruction combined with a hepatopathy. Potential systemic causes for cats with elevated liver enzymes include hyperthyroidism, DM, sepsis, toxicity (meds etc...), FIP, etc..) If these conditions are unlikely then a hepatic/post hepatic issue (infectious, inflammatory, lipidosis, neoplasia) is suspected.

- Consider close evaluation of history for possible toxic changes examine medications, diet, dietary indiscretion etc..

- Recommend thyroid evaluation (if not already done)
- If not already done, consider pre and post prandial bile acids to evaluate liver function (can skip if bilirubin is elevated)
- Consider fine needle aspirate if round cell neoplasia is on your differential list (25 g needle, normal coags)
- If cytology is not helpful and there is no response to therapy, consider liver biopsy with samples obtained for histopathology and culture.
- Recheck gall bladder and bile duct in 48-72 hours to look for progressive distension.
- If triaditis is suspected consider therapy for cholangiohepatitis (fluids, antibiotics +/- steroids), testing for pancreatitis and evaluation for IBD (GI panel to Texas A&M GI lab)
- Consider a feeding tube if patient is not eating for a prolonged period of time





The information and recommendations provided are based on the images presented by the referring veterinarian/sonographer. No evaluation can be communicated regarding pathology that was not visible in the image/video clips provided.

Thank you for this referral. If the clinical or image interpretation does not parallel your findings or if I can be of any further assistance please contact me.

Kathleen Sennello DVM,MS, Diplomate ACVIM (Small animal Internal Medicine)
kathleen.sennello@sonopath.com