

Portable Animal Western Sonography, Inc.

IMAGING PERFORMED BY
pawsonography@gmail.com 530-786-8340

PATIENT

Eris Oconnor

PRESENTING CLINICAL SIGNS

SPECIES

Canine

weight loss- appetite decreased- 3 seizures in the last few months. Hindlimb paresis and mild ataxia, Hx of pancreatitis
Abnormal PE/Chem/CBC/UA Results: ALT remains elevated (217), basically unchanged despite being on SamE. Mild dec albumin (2.3).

BREED

German Shepherd

ULTRASONOGRAPHIC EXAMINATION OF THE ABDOMEN

Urinary System

The urinary bladder is moderately distended with anechoic urine. The Bladder wall, trigone, ureteral papillae and visible urethra (to a depth of 2cm) appear normal with no evidence of wall thickening, mucosal irregularities, masses or cystic calculi.

SEX

Spayed Female

The left kidney has a normal shape and size (7.5 cm). Overall echogenicity is normal with adequate corticomedullary distinction and a typical 1:3 cortex:medulla ratio. There is no evidence of perinephric inflammation or effusion. There is no evidence of pyelectasia, nephroliths, infarcts or hydronephrosis. Renal vasculature is normal.

AGE

11 Years 8 Months

The right kidney has a normal shape and size (7.8 cm). Overall echogenicity is normal with adequate corticomedullary distinction and a typical 1:3 cortex:medulla ratio. There is no evidence of perinephric inflammation or effusion. There is no evidence of pyelectasia, nephroliths, infarcts or hydronephrosis. Renal vasculature is normal.

WEIGHT

66 Pounds

Adrenal Glands

The left adrenal gland is normal in size measuring 0.64 cm at the caudal pole. It is observed in its normal position cranial to the left renal artery. It is normal in appearance (uniformly hypoechoic) and shape with no evidence of a mass effect.

INTERPRETED BY

Kathleen Sennello DVM,
MS, Diplomate ACVIM
(Small Animal Internal
Medicine)

The right adrenal gland is normal in size measuring 0.64 cm at the caudal pole. It is observed in its normal position between the cranial aspect of the right kidney and the caudal vena cava. It is normal in appearance (uniformly hypoechoic) and shape with no evidence of a mass effect.

IMAGING BY

Loetitia Saint-Jacques,
LVT

Spleen

The spleen is subjectively normal in size. The spleen echotexture is heterogenous and mildly mottled, the splenic capsule is smooth with no irregularities. The blood flow through the hilus and splenic parenchyma appears normal. No focal parenchymal abnormalities are visualized.

HOSPITAL NAME

Fairgrounds AH

Liver

The liver is subjectively normal in size, and echogenicity with smooth peripheral margins. The parenchyma is heterogenous in echotexture with subtle, indistinct focal mottling. The visible portions of the vasculature and biliary tract appear normal. There are numerous large, poorly defined, hypoechoic nodules visualized, measuring 1.3 cm x 2.65 cm, 1.8 cm x 3.13 cm, and 1.45 cm x 2.62 cm. Additionally, there is a hyperechoic nodule measuring 1.7 cm x 2.13 cm. These lesions do not significantly deform the hepatic margins.

REFERRING VET

Dr. Johnson

INVOICE

36346

The gallbladder lumen is moderately distended. The wall of the gall bladder is not thickened and has a smooth mucosal surface. Luminal contents are primarily anechoic. The cystic and common bile ducts are normal/not visible.

DATE

3/22/22



PATIENT

Eris Oconnor

Gastrointestinal

The stomach contains minimal luminal contents. It measures at a normal thickness of <0.7cm with some variability due to the presence of rugal folds. The distinction of the gastric wall layers is adequate and there is no impression of reduced peristaltic activity. No masses or focal lesions were observed.

SPECIES

Canine

BREED

German Shepherd

The visualized areas of duodenum, jejunum and ileum have a relatively uniform diameter with minimal fluid distension. Wall thickness is normal. Bowel loops follow a curvilinear path with distinct wall layering maintaining the typical 1:3 muscularis:mucosa layer ratio. The duodenum measured as normal (between 0.3-0.5cm in wall thickness) and the jejunum measured as normal (between 0.2-0.47cm.) Visualized peristalsis appears appropriate. There were no focal lesions consistent with obstruction or a mass effect observed.

SEX

Spayed Female

The ileocecal junction was visualized and exhibited normal intact wall layering and is subjectively of normal thickness. Sections of colon are visualized with formed fecal material and gas shadowing distally. There is no observed focal or generalized colon wall thickening or loss of layering.

AGE

11 Years 8 Months

Pancreas

The pancreas is normal and isoechoic to surrounding mesentery. There is no evidence of nodules or cystic lesions. There is no evidence of regional mesenteric inflammation or fluid.

WEIGHT

66 Pounds

Free Abdomen

Evaluation of the peritoneal cavity did not reveal any evidence of effusion, or subjective lymphadenomegaly. The Medial iliac nodes appear normal and there was no evidence of a caudal aortic thrombus at the bifurcation. The omentum is of normal uniform echogenicity.

INTERPRETED BY

Kathleen Sennello DVM,
MS, Diplomate ACVIM
(Small Animal Internal
Medicine)

Other

A brief view of the heart was submitted. No significant pericardial effusion was seen.

ULTRASONOGRAPHIC FINDINGS

- Mildly mottled spleen – The diffuse splenic changes are non-specific and could be consistent with lymphoid hyperplasia, extramedullary hematopoiesis, infiltrative neoplasia, inflammation, other. Cytology or histopathology would be necessary to get a definitive diagnosis.
- Heterogeneous liver with hypoechoic nodules and rare hyperechoic nodules – The diffuse hepatic changes are non-specific and could be consistent with vacuolar hepatopathy, nodular hyperplasia, inflammatory/immune-mediated disease, fibrosis, extramedullary hematopoiesis, toxic hepatopathy (e.g., copper), infiltrative neoplasia (less likely) or other hepatopathy.

IMAGING BY

Loetitia Saint-Jacques,
LVT

HOSPITAL NAME

Fairgrounds AH

REFERRING VET

Dr. Johnson

INTERPRETATION OF THE FINDINGS & FURTHER RECOMMENDATIONS

The liver is heterogeneous and there are hypoechoic lesions visible. These lesions could represent a benign or neoplastic process.

INVOICE

36346

DATE

3/22/22



PATIENT

Eris Oconnor

- Consider close evaluation of history for possible toxic changes examine medications, diet, dietary indiscretion etc...

SPECIES

Canine

- Consider PCR on urine/serum for leptospirosis (if not on antibiotics)/serology if recent antibiotic history

BREED

German Shepherd

- If not already done, consider pre and post prandial bile acids to evaluate liver function
- Recommend fine needle aspirate of both "normal appearing" heterogeneous liver and a hypochoic nodule.

SEX

Spayed Female

- Consider three view thoracic radiographs to rule out concurrent thoracic disease/involvement.

AGE

Additionally, the spleen is subtly mottled. consider a fine needle aspirate for cytology.

11 Years 8 Months

WEIGHT

66 Pounds

INTERPRETED BY

Kathleen Sennello DVM,
MS, Diplomate ACVIM
(Small Animal Internal
Medicine)

IMAGING BY

Loetitia Saint-Jacques,
LVT

HOSPITAL NAME

Fairgrounds AH

REFERRING VET

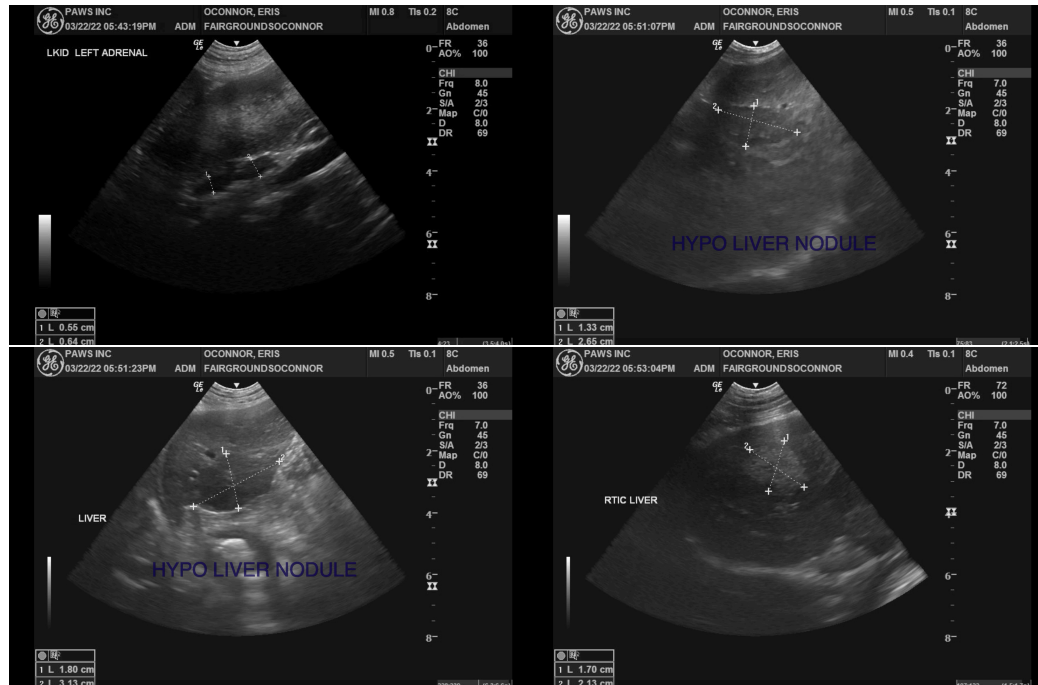
Dr. Johnson

INVOICE

36346

DATE

3/22/22





PATIENT

Eris Oconnor

SPECIES

Canine

BREED

German Shepherd

SEX

Spayed Female

AGE

11 Years 8 Months

WEIGHT

66 Pounds

INTERPRETED BY

Kathleen Sennello DVM,
MS, Diplomate ACVIM
(Small Animal Internal
Medicine)

IMAGING BY

Loetitia Saint-Jacques,
LVT

HOSPITAL NAME

Fairgrounds AH

REFERRING VET

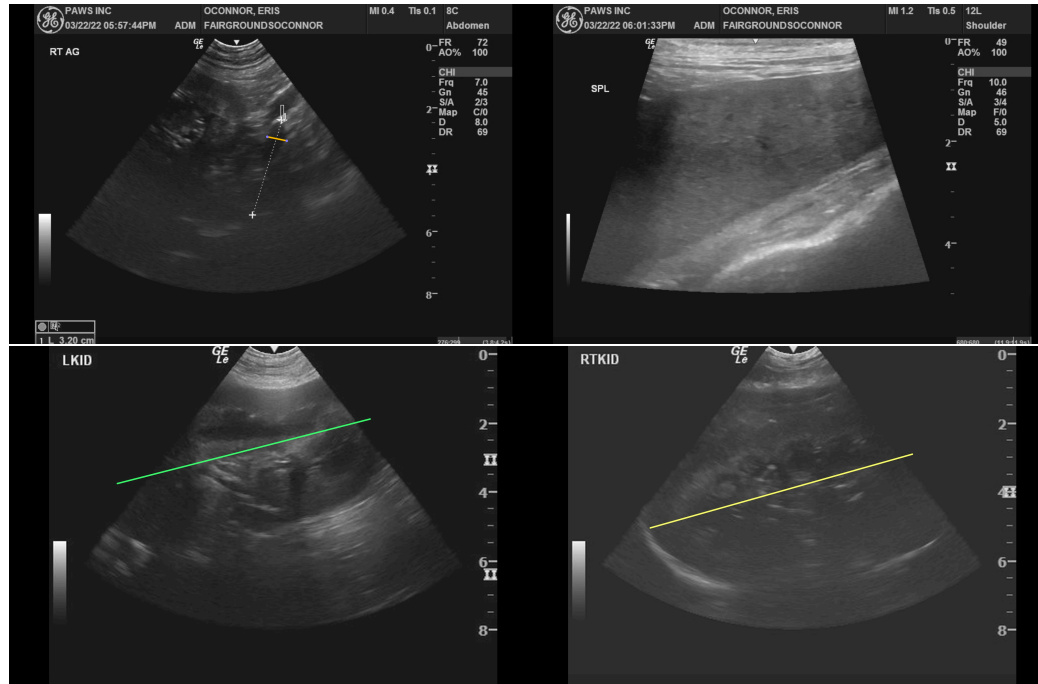
Dr. Johnson

INVOICE

36346

DATE

3/22/22



The information and recommendations provided are based on the images presented by the referring veterinarian/sonographer. No evaluation can be communicated regarding pathology that was not visible in the image/video clips provided.

Thank you for this referral. If the clinical or image interpretation does not parallel your findings or if I can be of any further assistance please contact me.

Kathleen Sennello DVM,MS, Diplomate ACVIM (Small animal Internal Medicine)
kathleen.sennello@sonopath.com