

**DATE PRESENTING CLINICAL SIGNS**

3/21/23 Second UTI- check for bladder/kidney dz.

PATIENT

Maggie Mae Denning

Current Medications: None listed.
Date of Previous IntraPet Ultrasound: No previous.
Sedation: Not required to complete full diagnostic ultrasound.
Stat Report: Not requested.
Imaging Performed By: Andi Parkinson, BS, RDMS.

SPECIES

Canine

BREED

Dachshund

SEX

Spayed Female

AGE

2/1/17

WEIGHT

29.8 Pounds

INTERPRETED BY

Kathleen Sennello DVM,
MS, Diplomate ACVIM
(Small Animal Internal
Medicine)

HOSPITAL NAME

Eastern AH

REFERRING VET

Dr. Kaufman

INVOICE

46045

LIMITED ULTRASONOGRAPHIC EXAMINATION

The urinary bladder is moderately to mildly distended with echogenic urine. The dorsal urinary bladder wall appears relatively normal, measuring 0.19 cm. The ventral urinary bladder wall and apical portion of the urinary bladder appear severely thickened and irregular, measuring approximately 0.81 cm, with hyperechoic sandy debris along the bladder wall. This thickening extends to the level of the trigone. There are no focal mass effects and no large calculi observed. Findings are most consistent with cystitis, but underlying neoplastic disease cannot be definitively ruled out.

The left kidney has a normal shape and size (5.15 cm) with small non-obstructive nephroliths, one of which measures 0.77 cm. Overall echogenicity is slightly hyperechoic with poor corticomedullary distinction and a typical 1:3 cortex:medulla ratio. There is no evidence of focal perinephric inflammation or effusion. There is no evidence of pyelectasia, infarcts or hydroureter. Renal vasculature is normal.

The right kidney has a normal shape and size (5.68 cm). Overall echogenicity is slightly hyperechoic with poor corticomedullary distinction and a typical 1:3 cortex:medulla ratio. There is no evidence of focal perinephric inflammation or effusion. There is no evidence of pyelectasia, nephroliths, infarcts or hydroureter. Renal vasculature is normal.

There is a prominent sublumbar lymph node visualized measuring 0.44 cm in width.

ULTRASONOGRAPHIC FINDINGS

- Thickened dependent portion of the urinary bladder with hyperechoic sandy debris – Findings are most consistent with cystitis.
- Decreased corticomedullary distinction in both kidneys with left-sided nephroliths – Mild loss of corticomedullary distinction in both kidneys could be consistent with chronic degenerative disease or interstitial nephrosis.
- Mild sublumbar lymphadenopathy – The prominent abdominal lymph nodes are most consistent with reactive lymphadenitis or lymphoid hyperplasia. Neoplastic infiltration is considered less likely.

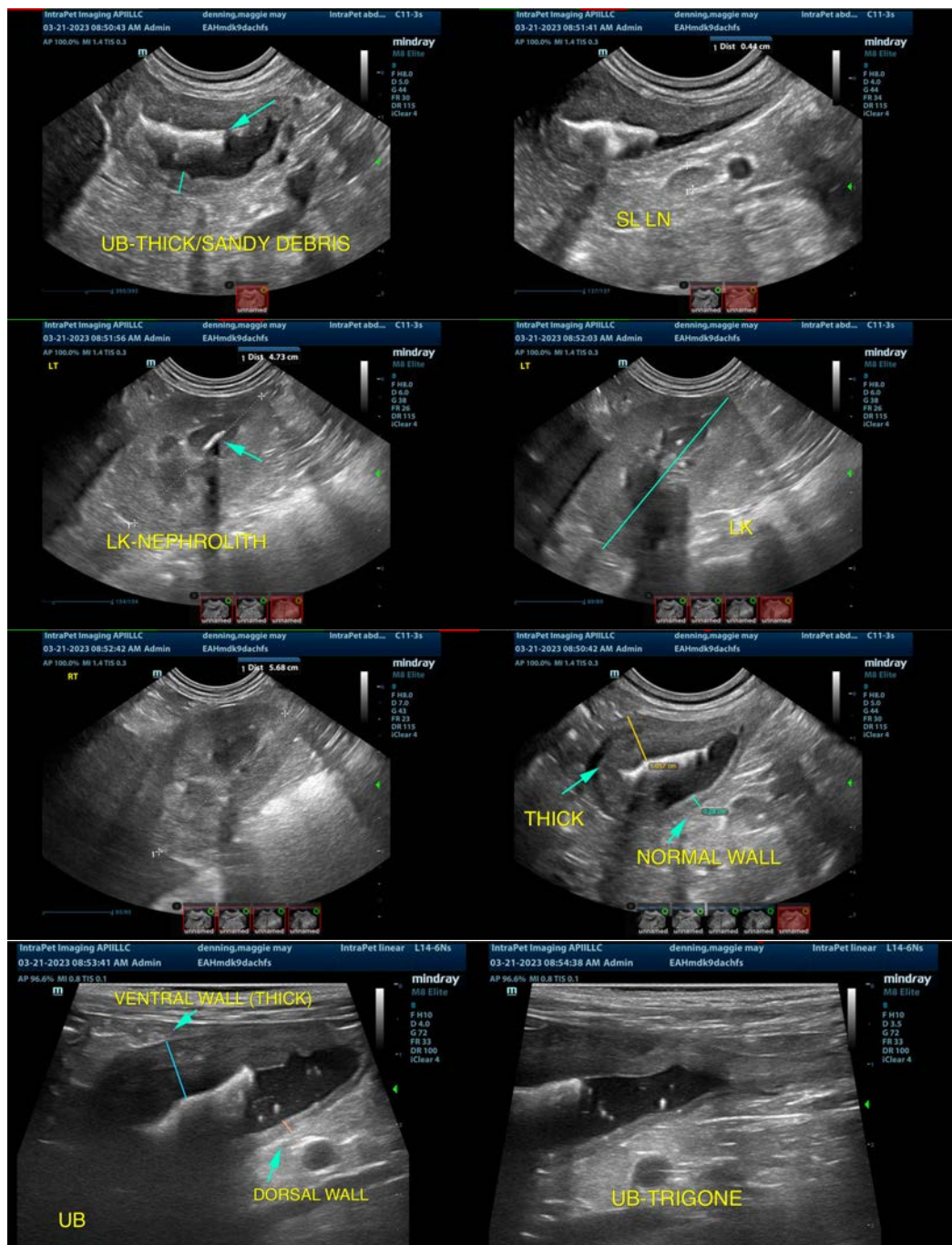
INTERPRETATION OF THE FINDINGS & FURTHER RECOMMENDATIONS

The dependent portion of the urinary bladder appears thickened with adherent sandy debris. These findings are most consistent with cystitis. Recommend urinalysis and culture and reevaluation of the urinary bladder after treatment for cystitis to ensure that the bladder wall thickening resolves. If this does not resolve, or there is not an infection present, then consider the less likely possibility of underlying neoplastic change, and consider a traumatic catheterization or cystoscopy to further evaluate the bladder wall and obtain biopsies.

There are mild to moderate age related changes associated with both kidneys and small non-obstructive nephroliths visualized associated with the left kidney. Correlate this with renal values and blood pressure

evaluation.

The prominent sublumbar lymph node is likely reactive, but continued monitoring is warranted.



The information and recommendations provided are based on the images presented by the referring veterinarian/sonographer. No evaluation can be communicated regarding pathology that was not visible in the image/video clips provided.

Thank you for this referral. If the clinical or image interpretation does not parallel your findings or if I can be of any further assistance please contact me.

Kathleen Sennello DVM,MS, Diplomate ACVIM (Small animal Internal Medicine)
kathleen.sennello@sonopath.com