

**DATE PRESENTING CLINICAL SIGNS**

3/21/23 Historical hyperthyroidism controlled with methimazole. Presented 03/14/2023 for polyuria, unknown polydipsia. PE Findings: Periodontal disease (Grade I), weight gain of 0.5lbs, no other abnormalities.

**PATIENT**

Jonesy Sapp Current Medications: Denamarin 90mg PO q24hrs, Methimazole 5mg PO q12hrs.  
Lab Results: 03/14/2023: SDMA 15 (H), ALT 1,030 (H), AST 275 (H), ALP 469 (H), T. Bil 1.8 (H), Unconj Bil 0.8 (H), Conj Bil 1.0 (H), ProBNP 122 (H), USG 1.016, Total T4 3.4 (N).

**SPECIES**

Feline Date of Previous IntraPet Ultrasound: No previous.  
Sedation: Not required to complete full diagnostic ultrasound.  
Stat Report: Not requested.  
Imaging Performed By: Andi Parkinson, BS, RDMS.

**BREED**

DLH

**ULTRASONOGRAPHIC EXAMINATION OF THE ABDOMEN****Urinary System**

The urinary bladder is moderately distended with anechoic urine. The Bladder wall, trigone, ureteral papillae and visible urethra (to a depth of 2cm) appear normal with no evidence of wall thickening, mucosal irregularities, masses or cystic calculi.

**AGE**

No left kidney visualized, suspect aplasia.

2/12/08

**WEIGHT**

6.3 Pounds

The right kidney has a normal shape and size (3.93 cm) with mild pyelectasia at 0.11 cm and a small non-obstructive nephrolith measuring 0.28 cm. Overall echogenicity is normal with adequate corticomedullary distinction and a typical 1:3 cortex:medulla ratio. There is no evidence of focal perinephric inflammation or effusion. There is no evidence of infarcts or hydroureter. Renal vasculature is normal.

**INTERPRETED BY**

Kathleen Sennello DVM,  
MS, Diplomate ACVIM  
(Small Animal Internal  
Medicine)

**Adrenal Glands**

The region of left adrenal (Cranial to left renal artery) is unremarkable but the adrenal is not distinctly visualized. No evidence of a mass effect is visualized.

The region of the right adrenal (between right cranial kidney and vena cava) is unremarkable, but the adrenal is not distinctly visualized. No evidence of a mass effect is visualized.

**HOSPITAL NAME**

Essex Middle River VC

**Spleen**

The spleen is large in size (0.95 cm in width at the level of the hilus). The spleen echotexture is heterogenous and mottled, the splenic capsule is smooth with no irregularities. The blood flow through the hilus and splenic parenchyma appears normal. No focal parenchymal abnormalities are visualized.

**REFERRING VET**

Dr. Stoll

**Liver**

The liver is large in size, and hypoechoic with smooth peripheral margins. The parenchyma is heterogenous in echotexture with subtle, indistinct focal mottling. The visible portions of the vasculature and biliary tract appear normal. No focal nodules or cystic lesions are observed.

**INVOICE**

46043

The gallbladder lumen is moderately distended. The wall of the gall bladder appears hyperechoic and thickened, measuring 0.27 cm. contents are mild and primarily anechoic. The cystic and common bile ducts are normal/not visible.

**Gastrointestinal**

The stomach contains minimal luminal contents. It measures at a normal thickness of <0.36cm with some variability due to the presence of rugal folds. The distinction of the gastric wall layers is adequate and there is no impression of reduced peristaltic activity. No masses or focal lesions were observed.

The visualized areas of duodenum, jejunum and ileum have a uniform diameter with minimal fluid distension. Wall thickness is normal to slightly increased. Bowel loops follow a typical curvilinear path with distinct wall layering, but some areas display a prominent muscularis layer which does not display the typical 1:3 muscularis:mucosa layer ratio. Jejunum wall measures 0.18 cm. Visualized peristalsis appears appropriate. There were no focal lesions consistent with obstruction or a mass effect observed.

The ileocecal junction was visualized and exhibited normal intact wall layering and is subjectively of normal thickness. Sections of colon are visualized with formed fecal material and gas shadowing distally. There is no observed focal or generalized colon wall thickening or loss of layering.

### ***Pancreas***

The pancreas is normal and isoechoic to surrounding mesentery. There is no evidence of nodules or cystic lesions. There is no evidence of regional mesenteric inflammation or fluid.

### ***Free Abdomen***

Evaluation of the peritoneal cavity did not reveal any evidence of effusion, or subjective lymphadenomegaly. The Medial iliac nodes appear normal and there was no evidence of a caudal aortic thrombus at the bifurcation. The omentum is of normal uniform echogenicity.

## **PRIMARY FINDINGS**

- Large, mottled spleen – The diffuse splenic changes are non-specific and could be consistent with lymphoid hyperplasia, extramedullary hematopoiesis, infiltrative neoplasia, inflammation, other. Cytology or histopathology would be necessary to get a definitive diagnosis.
- Large, hypoechoic, heterogeneous liver – Hepatic changes are non-specific and could be consistent with inflammation/infection (cholangiohepatitis), infiltrative neoplasia, lipidosis or other hepatopathy.
- Thickened gallbladder wall – This can be seen with chronic inflammation/cholecystitis.
- Prominent muscularis layer to the small intestine – The small intestinal wall changes could be consistent with an underlying inflammatory process. These types of changes can sometimes be seen in normal older cats. Correlate with clinical signs.

## **SECONDARY FINDINGS**

- Absent left kidney – This is likely due to aplasia.
- Non-obstructive nephrolith visualized associated with the right kidney – The hyperechoic mineralized focus observed at the corticomedullary junction of the right kidney is consistent with a small, non-obstructive nephrolith.

## **INTERPRETATION OF THE FINDINGS & FURTHER RECOMMENDATIONS**

The liver is large and heterogeneous. These findings are concerning for a primary hepatopathy. Additionally, the gallbladder has a somewhat thickened wall, which could be consistent with concurrent cholecystitis. There is no significant evidence of a significant biliary obstruction. Consider the following for further evaluation:

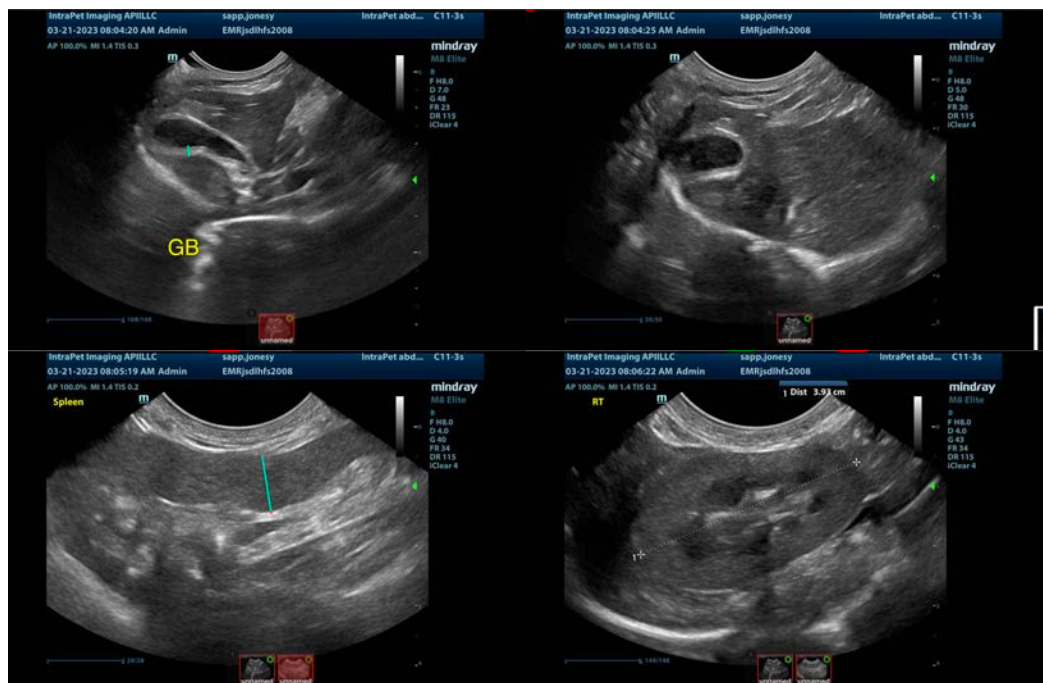
- Consider close evaluation of history for possible toxic changes examine medications, diet, dietary indiscretion etc.

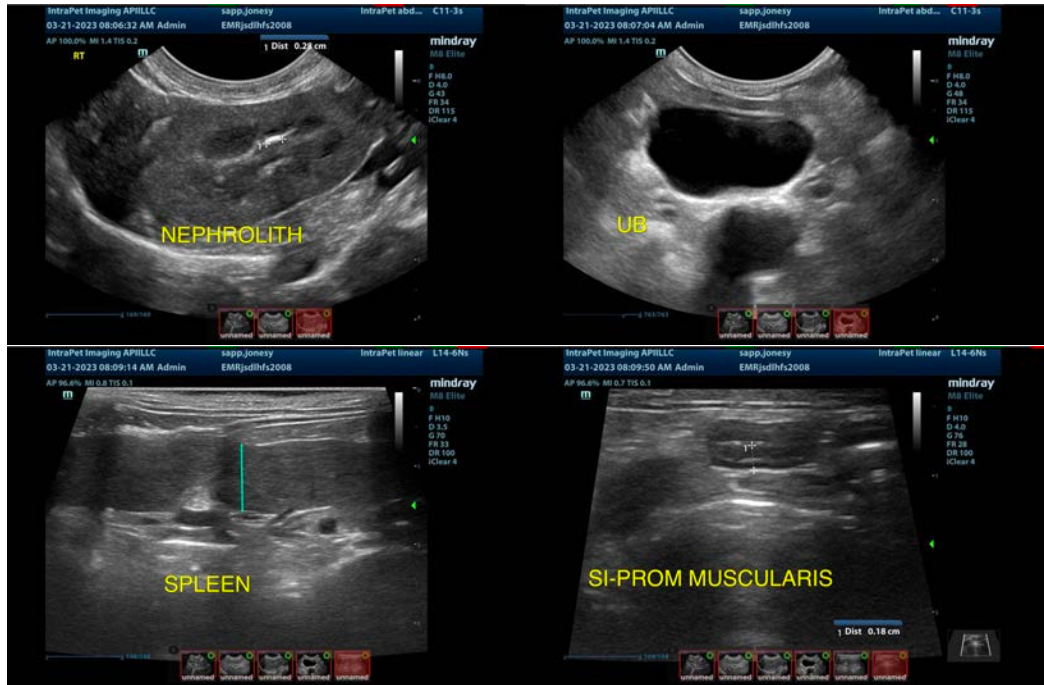
- Recommend thyroid evaluation (if not already done)
- Consider screening for toxoplasmosis.
- Consider Fine needle aspirate if round cell neoplasia is on your differential list (25 g needle, normal coags)
- Consider liver biopsy with samples obtained for histopathology and culture
- If triaditis is suspected consider therapy for cholangiohepatitis, testing for pancreatitis and evaluation for IBD (GI panel to Texas A&M GI lab)

The spleen is large and mottled. Recommend a fine needle aspirate of the spleen, looking for possible evidence of round cell neoplasia, systemic inflammation, etc.

The muscularis layer of the small intestine is somewhat prominent. This can be a normal finding in some older cats. If there is a chronic history of GI signs in this individual, this could be associated with concurrent underlying gastrointestinal disease.

Recommend three view thoracic radiographs to evaluate for possible concurrent thoracic disease/involvement.





The information and recommendations provided are based on the images presented by the referring veterinarian/sonographer. No evaluation can be communicated regarding pathology that was not visible in the image/video clips provided.

Thank you for this referral. If the clinical or image interpretation does not parallel your findings or if I can be of any further assistance please contact me.

Kathleen Sennello DVM,MS, Diplomate ACVIM (Small animal Internal Medicine)  
kathleen.sennello@sonopath.com