



PATIENT PRESENTING CLINICAL SIGNS

PATIENT Spooky Pace Patient with history of IBD; patient is currently long-term Budesonide, presents for vomiting and weight loss.

SPECIES Feline Abnormal PE/Chem/CBC/UA Results: MCHC 38.4, lymphocytes 0.72, ALP 13, T4 WNL 3.8.

Feline

ULTRASONOGRAPHIC EXAMINATION OF THE ABDOMEN

BREED *Urinary System*

DSH The urinary bladder is moderately distended with anechoic urine. The Bladder wall, trigone, ureteral papillae, and visible urethra (to a depth of 2cm) appear normal with no evidence of wall thickening, mucosal irregularities, masses, or cystic calculi.

SEX

Neutered Male The left kidney has a normal shape and size (3.89 cm). Overall echogenicity is normal with adequate corticomedullary distinction and a typical 1:3 cortex: medulla ratio. There is no evidence of focal perinephric inflammation or effusion. There is no evidence of pyelectasia, nephroliths, infarcts or hydroureter. Renal vasculature is normal.

AGE

14-year-old

The right kidney has a normal shape and size (3.71 cm). Overall echogenicity is normal with adequate corticomedullary distinction and a typical 1:3 cortex: medulla ratio. There is no evidence of focal perinephric inflammation or effusion. There is no evidence of pyelectasia, nephroliths, infarcts or hydroureter. Renal vasculature is normal.

WEIGHT

10.5 lbs

INTERPRETED BY *Adrenal Glands*

Kathleen Sennello DVM, MS, Diplomate ACVIM (Small Animal Internal Medicine) The region of left adrenal (Cranial to left renal artery) is unremarkable but the adrenal is not distinctly visualized. No evidence of a mass effect.

The right adrenal gland is normal in size measuring 0.27 cm at the caudal pole. It is observed in its normal position between the cranial aspect of the right kidney and the caudal vena cava. It is normal in appearance (uniformly hypoechoic) and shape with no evidence of a mass effect.

IMAGING PERFORMED BY

Kelly Vazquez

Spleen

The spleen is subjectively normal in size (0.66 cm), echotexture is homogenous, and the splenic capsule is smooth with no irregularities. The blood flow through the hilus and splenic parenchyma appears normal. No focal parenchymal abnormalities are visualized.

HOSPITAL NAME

Animal Paradise Hospital

Liver

The liver is subjectively normal in size, and echogenicity with smooth peripheral margins. The parenchyma is homogenous echotexture. The visible portions of the vasculature and biliary tract appear normal. No focal nodules or cystic lesions are observed.

REFERRING VET

Dr. Elshafie

INVOICE

10127

The gallbladder lumen is moderately distended. The wall of the gall bladder is not thickened and has a smooth mucosal surface. Luminal contents are mild and primarily anechoic. The cystic and common bile ducts are normal/not visible.

DATE

3/20/2023

Gastrointestinal

The stomach contains minimal luminal contents. It measures at a normal thickness of <0.36cm with some variability due to the presence of rugal folds. The distinction of the gastric wall layers is adequate and there is no impression of reduced peristaltic activity. No masses or focal lesions were observed.



PATIENT

Spooky Pace

SPECIES

Feline

BREED

DSH

SEX

Neutered Male

AGE

14-year-old

WEIGHT

10.5 lbs

INTERPRETED BY

Kathleen Sennello DVM,
MS, Diplomate ACVIM
(Small Animal Internal
Medicine)

IMAGING PERFORMED BY

Kelly Vazquez

HOSPITAL NAME

Animal Paradise
Hospital

REFERRING VET

Dr. Elshafie

INVOICE

10127

DATE

3/20/2023

The visualized areas of duodenum, jejunum and ileum have a relatively uniform diameter with minimal fluid distension. Wall thickness is normal. Bowel loops follow a curvilinear path with distinct wall layering maintaining the typical 1:3 muscularis: mucosa layer ratio. The jejunum measured as normal (0.22 cm.) Visualized peristalsis appears appropriate. There were no focal lesions consistent with obstruction or a mass effect observed.

The ileocecal junction was visualized and exhibited normal intact wall layering and is subjectively of normal thickness. Sections of colon are visualized with formed fecal material and gas shadowing distally. There is no observed focal or generalized colon wall thickening or loss of layering.

Pancreas

The pancreas is prominent and hypoechoic in the right limb as compared to the surrounding isoechoic mesentery. There is no evidence of nodules or cystic lesions. There is no evidence of regional mesenteric inflammation or fluid.

Free Abdomen

Evaluation of the peritoneal cavity did not reveal any evidence of effusion. There are occasional clusters of hypoechoic irregular lymph nodes, surrounded by hyperechoic mesentery. Examples of these lymph nodes measure at 1.26 cm x 0.67 cm and 0.50 cm x 1.88 cm. There is an additional lymph node measured at 0.98 cm in diameter. The omentum is of normal uniform echogenicity.

ULTRASONOGRAPHIC FINDINGS

- Prominent hypoechoic right limb of the pancreas. The pancreatic changes are most consistent with age-related parenchymal remodeling, potentially secondary to a prior inflammatory episode, early fibrosis, or chronic pancreatitis.
- Mesenteric lymphadenopathy. Differentials include inflammation, infection, and neoplastic change. Given the current budesonide therapy this could be a more significant finding.

INTERPRETATION OF THE FINDINGS & FURTHER RECOMMENDATIONS

No focal or large mass lesions are observed and there are no focal lesions visualized associated with the GI tract. There are some clusters of irregular hypoechoic large mesenteric lymph nodes. This is likely more significant in the face of current budesonide therapy, as this should suppress inflammation. Recommend a fine needle aspirate of a mesenteric lymph node, as there could be concern for either neoplastic change of the previous IBD diagnosed or progression of the IBD to a more severe form. If a cytologic evaluation of the local lymph node is not diagnostic, then biopsies of the GI tract may be indicated.

Additionally, the right limb of the pancreas appears somewhat prominent. Correlate this with a quantitative fPLI measurement. If not already doing so, recommend empirical treatment for pancreatic inflammation and consider a hypoallergenic/novel protein diet, consider a GI panel to Texas A&M for a quantitative fPLI/TLI/Cobalamin/Folate and the use of probiotics. If symptoms persist and a cytologic evaluation is not diagnostic, then consider GI biopsies.

Recommend three view thoracic radiographs to evaluate for possible concurrent thoracic disease/involvement.



PATIENT

Spooky Pace

SPECIES

Feline

BREED

DSH

SEX

Neutered Male

AGE

14-year-old

WEIGHT

10.5 lbs

INTERPRETED BY

Kathleen Sennello DVM,
MS, Diplomate ACVIM
(Small Animal Internal
Medicine)

**IMAGING
PERFORMED BY**

Kelly Vazquez

HOSPITAL NAME

Animal Paradise
Hospital

REFERRING VET

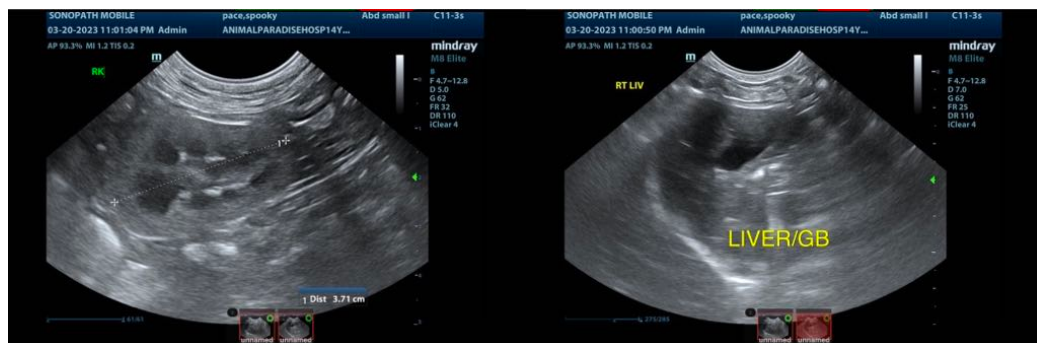
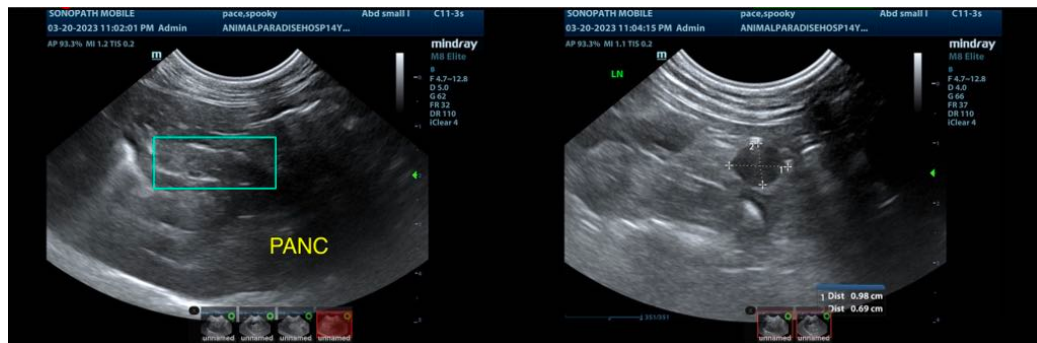
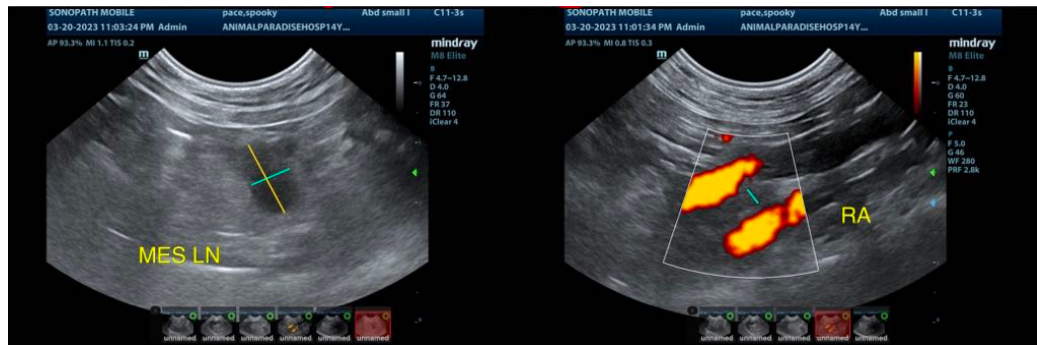
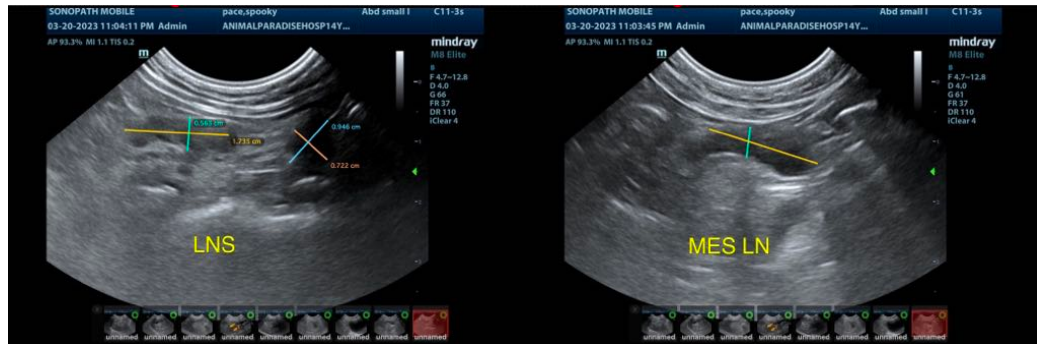
Dr. Elshafie

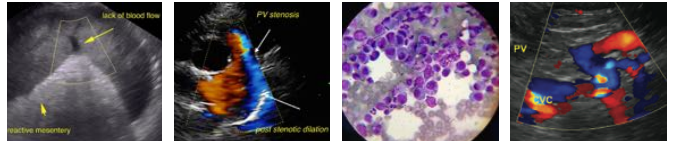
INVOICE

10127

DATE

3/20/2023





PATIENT

Spooky Pace

SPECIES

Feline

BREED

DSH

SEX

Neutered Male

AGE

14-year-old

WEIGHT

10.5 lbs

INTERPRETED BY

Kathleen Sennello DVM,
MS, Diplomate ACVIM
(Small Animal Internal
Medicine)

**IMAGING
PERFORMED BY**

Kelly Vazquez

HOSPITAL NAME

Animal Paradise
Hospital

REFERRING VET

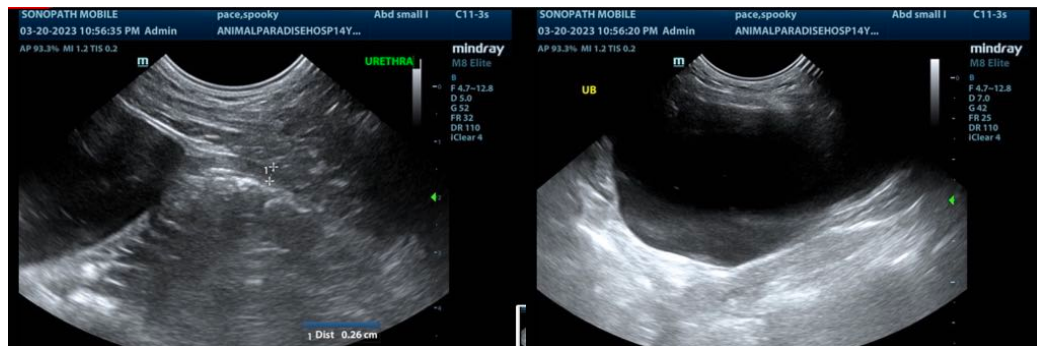
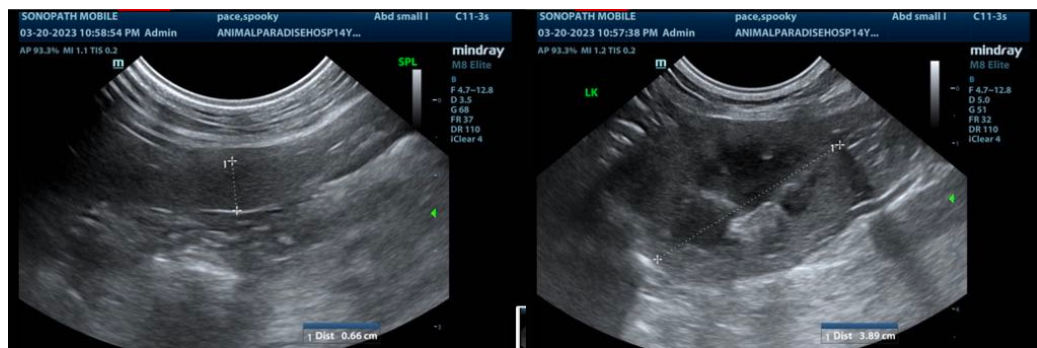
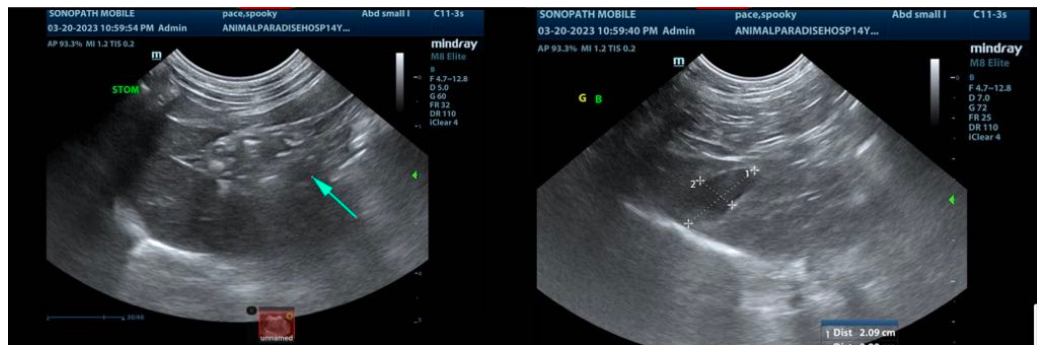
Dr. Elshafie

INVOICE

10127

DATE

3/20/2023



The information and recommendations provided are based on the images presented by the referring veterinarian/sonographer. No evaluation can be communicated regarding pathology that was not visible in the image/video clips provided.

Thank you for this referral. If the clinical or image interpretation does not parallel your findings or if I can be of any further assistance, please contact me.

Kathleen Sennello DVM, MS, Diplomate ACVIM (Small animal Internal Medicine)

kathleen.sennello@sonopath.com