**DATE PRESENTING CLINICAL SIGNS**

3/2/22 Splenic enlargement, concerning for neoplasia. Presented this morning as hemoabdomen.

PATIENT

Falko Sharp

Lab Results: Pending. Severe splenomegaly with irregular margination and heterogenous appearance (based on my inexpert AFAST)

SPECIES

Canine

Date of Previous IntraPet Ultrasound: No previous.

Sedation: Declined.

Stat Report: Declined / Not requested.

BREED

German Shepherd

ULTRASONOGRAPHIC EXAMINATION OF THE ABDOMEN**Urinary System**

The urinary bladder is moderately distended with anechoic urine. The Bladder wall, trigone, ureteral papillae and visible urethra (to a depth of 2cm) appear normal with no evidence of wall thickening, mucosal irregularities, masses or cystic calculi.

SEX

Intact Male

The prostate is large in size (4.33 cm in height when measured in the sagittal view) but has a regular shape with smooth external margins. The parenchyma is hyperechoic and heterogenous but no discrete focal lesions are present. The prostatic urethra appears normal with no evidence of irregularity, invasion, mass effect or calculi.

AGE

2009

The left kidney has a normal shape and size (7.27 cm). Overall echogenicity is normal with adequate corticomedullary distinction and a typical 1:3 cortex:medulla ratio. There is no evidence of perinephric inflammation or effusion. There is no evidence of pyelectasia, nephroliths, infarcts or hydroureter. Renal vasculature is normal.

WEIGHT

86 Pounds

INTERPRETED BY

Kathleen Sennello DVM,
MS, Diplomate ACVIM
(Small Animal Internal
Medicine)

The right kidney has a normal shape and size (8.46 cm). Overall echogenicity is normal with adequate corticomedullary distinction and a typical 1:3 cortex:medulla ratio. There is no evidence of perinephric inflammation or effusion. There is no evidence of pyelectasia, nephroliths, infarcts or hydroureter. Renal vasculature is normal.

IMAGING PERFORMED BY

Rachel Brillhart RDMS

Adrenal Glands

The region of left adrenal (Cranial to left renal artery) is unremarkable but the adrenal is not distinctly visualized. No evidence of a mass effect.

HOSPITAL NAME

Paradise AH

The region of the right adrenal (between right cranial kidney and vena cava) is unremarkable, but the adrenal is not distinctly visualized. No evidence of a mass effect.

REFERRING VET

Dr. Halpern

Spleen

The spleen is large, mottled and irregular. The blood flow through the hilus and splenic parenchyma appears normal. The spleen is severely abnormal with numerous heterogeneous to hypoechoic mass effects bulging from the capsule. A smaller heterogeneous mass is visualized measuring 4.49 cm x 1.64 cm. A second hypoechoic speckled lesion is visualized measuring 5.0 cm x 3.62 cm with lack of color flow suggestive of either a large clot or intraparenchymal hemorrhage. There is a very large mixed echogenicity mass effect towards the tail of the spleen measuring 11.04 cm x 10.74 cm, and numerous other cystic and cavitated regions with echogenic free fluid surrounding, suggestive of active hemorrhage.

INVOICE

35819

Liver

The liver is large in size, and normal in echogenicity with smooth peripheral margins. The parenchyma is heterogenous in echotexture with subtle, indistinct focal mottling. The visible portions of the vasculature and biliary tract appear normal. No focal nodules or cystic lesions are observed.

The gall bladder lumen is moderately distended. The wall of the gall bladder is not thickened and has a smooth mucosal surface. There is a moderate amount of non-organized echogenic debris. The cystic and common bile ducts are normal/not visible.

Gastrointestinal

The stomach is moderately dilated with fluid and irregular shadowing material most consistent with normal ingesta and gas. It measures at a normal thickness of <0.7cm with some variability due to the presence of rugal folds. The distinction of the gastric wall layering is adequate and there is no impression of reduced peristaltic activity. No masses or focal lesions were observed.

The visualized areas of duodenum, jejunum and ileum have a relatively uniform diameter with minimal fluid distension. Wall thickness is normal. Bowel loops follow a curvilinear path with distinct wall layering maintaining the typical 1:3 muscularis:mucosa layer ratio. The duodenum measured as normal (between 0.3-0.5cm in wall thickness) and the jejunum measured as normal (between 0.2-0.47cm.) Visualized peristalsis appears appropriate. There were no focal lesions consistent with obstruction or a mass effect observed.

The ileocecal junction was visualized and exhibited normal intact wall layering and is subjectively of normal thickness. Sections of colon are visualized with formed fecal material and gas shadowing distally. There is no observed focal or generalized colon wall thickening or loss of layering.

Pancreas

The pancreas is normal and isoechoic to surrounding mesentery. There is no evidence of nodules or cystic lesions. There is no evidence of regional mesenteric inflammation or fluid.

Free Abdomen

There is a large amount of echogenic free abdominal fluid. No lymphadenopathy is visualized and the omentum is of increased echogenicity around the spleen.

Other

Both testicles are imaged and appear within normal limits.

The heart is visualized with a small amount of pericardial effusion present. Additionally, there is evidence of mass lesions, likely at the heart base. One is visualized measuring 3.7 cm x 4.0 cm. Another lesion is either at the heart base or adjacent to the heart measuring 7.0 cm x 6.74 cm.

PRIMARY FINDINGS

- Large, mottled spleen with numerous cavitated heterogeneous mass effects and suspected active hemorrhage – Several large heterogenous mass effects with cavitations are present within the splenic parenchyma. The masses distort the splenic capsule. Differentials for the masses include neoplasia (e.g., hemangiosarcoma, hemangioma), hematoma, abscess, other. A neoplastic process is favored.
- Large, hyperechoic prostate – most consistent with benign prostatic hypertrophy +/- prostatitis.
- Large, heterogeneous liver – The diffuse hepatic changes are non-specific and could be consistent with vacuolar hepatopathy, nodular hyperplasia, inflammatory/immune-mediated disease, fibrosis, extramedullary hematopoiesis, toxic hepatopathy (e.g., copper), infiltrative neoplasia (less likely) or

other hepatopathy.

- Small volume pericardial effusion and suspect heart base mass – Recommend cardiac ultrasound and 3-view thoracic radiographs.

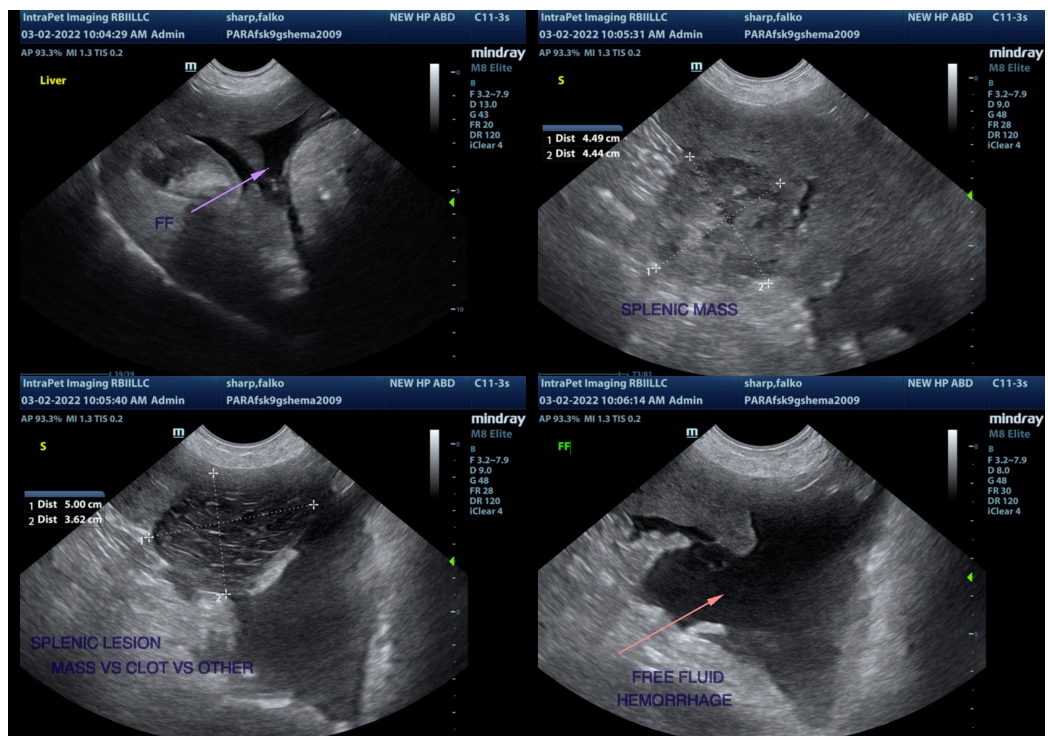
SECONDARY FINDINGS

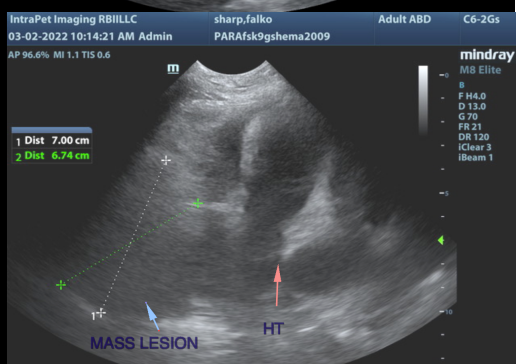
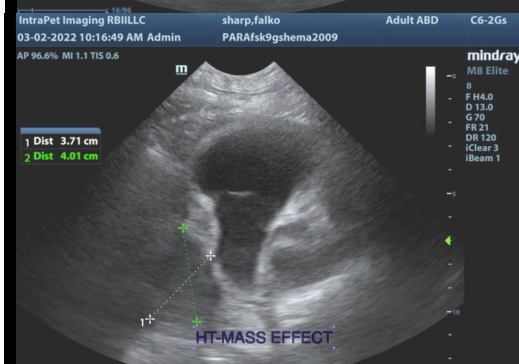
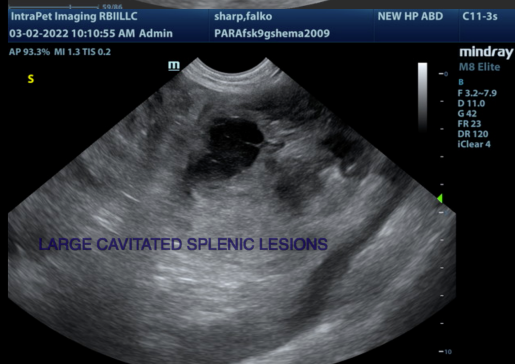
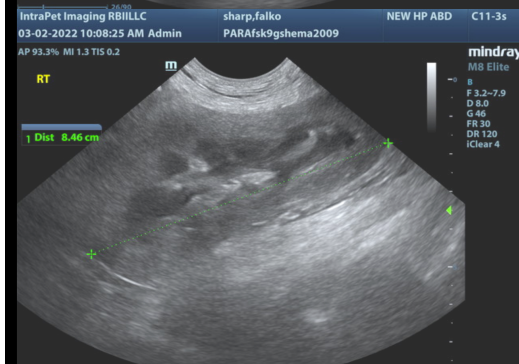
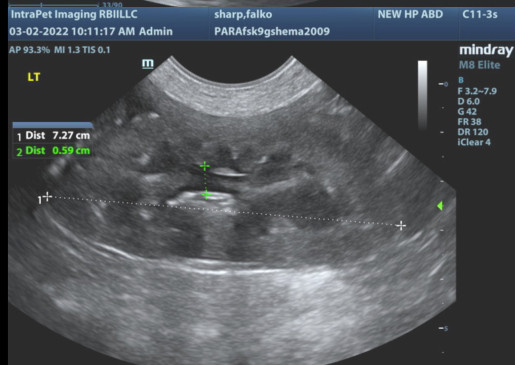
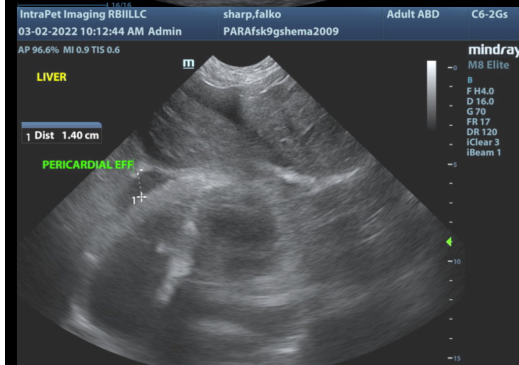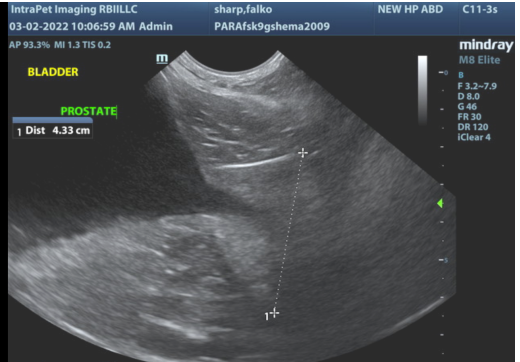
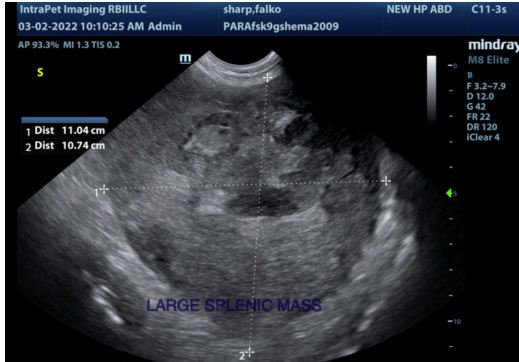
- Moderate gallbladder debris – The gastric distension and hypomotility could be consistent with focal ileus or a proximal duodenal obstruction.
- Moderate gastric ingesta – Moderate amount of shadowing material in gastric lumen - Correlate with feedings history and abdominal radiographs. If adequately fasted then consider such differentials as delayed gastric emptying or a partial outflow tract obstruction (none visualized).

INTERPRETATION OF THE FINDINGS & FURTHER RECOMMENDATIONS

Today's ultrasound reveals a severely diseased spleen with large cavitated lesions, suggestive of active hemorrhage. No definitive metastasis is noted in the abdomen outside of the spleen, but the liver does appear heterogeneous.

Additionally, there is pericardial effusion present and abnormal tissue adjacent to the heart, which is suspicious for a heart base mass and possibly pulmonary masses or multiple heart base masses. Recommend 3-view thoracic radiographs and cardiac ultrasound. Unfortunately, at this time, surgery is recommended for therapeutic purposes, but prognosis is extremely guarded to grave.





The information and recommendations provided are based on the images presented by the referring veterinarian/sonographer. No evaluation can be communicated regarding pathology that was not visible in the image/video clips provided.

Thank you for this referral. If the clinical or image interpretation does not parallel your findings or if I can be of any further assistance please contact me.

Kathleen Sennello DVM,MS, Diplomate ACVIM (Small animal Internal Medicine)
kathleen.sennello@sonopath.com