



## PATIENT

Fern Sweeney

## SPECIES

Canine

## BREED

Border Collie

## SEX

Spayed Female

## AGE

1 Year 4 Months

## WEIGHT

43.8 lbs

## INTERPRETED BY

Kathleen Sennello DVM,  
MS, Diplomate ACVIM  
(Small Animal Internal  
Medicine)

## IMAGING PERFORMED BY

Dr. Brittany Wolfe

## HOSPITAL NAME

HomeVets

## REFERRING VET

Dr. Brittany Wolfe

## INVOICE

73817

## DATE

3/19/26

## PRESENTING CLINICAL SIGNS

P presents for AUS for increasing SDMA. P has no clinical signs. She was adopted from a rescue and spayed around 2 - 4 months of age. She has some swelling/sq suture reaction but otherwise her spay was supposedly unremarkable.

Abnormal PE/Chem/CBC/UA Results: 1/13/26 SDMA = 16 2/17/26 SDMA = 18 3/13/26 SDMA = 10. Urine culture grew enterococcus 50-100k cfu/ml. leptospirosis elisa and pcr negative.

## ULTRASONOGRAPHIC EXAMINATION OF THE ABDOMEN

### Urinary System

The urinary bladder is mildly distended with anechoic urine. The visible areas of bladder wall appear normal with no focal lesions observed. No mass lesions or calculi observed. Visible regions of the trigone appear within normal limits. Evaluation of the urinary bladder is impaired by lack of urine distention.

The left kidney has a normal shape and size (5.39 cm). Overall echogenicity is normal with adequate corticomedullary distinction and a typical 1:3 cortex:medulla ratio. There is no evidence of focal perinephric inflammation or effusion. There is no evidence of pyelectasia, nephroliths, infarcts or hydronephrosis. Renal vasculature is normal.

The right kidney has a normal shape and size (5.1 cm). Overall echogenicity is normal with adequate corticomedullary distinction and a typical 1:3 cortex:medulla ratio. There is no evidence of focal perinephric inflammation or effusion. There is no evidence of pyelectasia, nephroliths, infarcts or hydronephrosis. Renal vasculature is normal.

### Adrenal Glands

The left adrenal gland is normal in size measuring 0.48 cm at the cranial pole and 0.56 cm at the caudal pole. It is observed in its normal position cranial to the left renal artery. It is normal in appearance (uniformly hypoechoic) and shape with no evidence of a mass effect.

The right adrenal gland is normal in size measuring 0.62 cm at the cranial pole and 0.75 cm at the caudal pole. It is observed in its normal position between the cranial aspect of the right kidney and the caudal vena cava. It is normal in appearance (uniformly hypoechoic) and shape with no evidence of a mass effect.

### Spleen

The spleen is subjectively normal in size (1.6 cm), echotexture is homogenous, and the splenic capsule is smooth with no irregularities. The blood flow through the hilus and splenic parenchyma appears normal. No focal parenchymal abnormalities are visualized.

### Liver

The liver is subjectively normal in size, and echogenicity with smooth peripheral margins. The parenchyma is homogenous echotexture. The visible portions of the vasculature and biliary tract appear normal. No focal nodules or cystic lesions are observed.

The gall bladder lumen is moderately distended. The wall of the gall bladder is not thickened and has a smooth mucosal surface. Luminal contents are mild and likely incidental at this time. The cystic and common bile ducts are normal/not visible.



## PATIENT

Fern Sweeney

## SPECIES

Canine

## BREED

Border Collie

## SEX

Spayed Female

## AGE

1 Year 4 Months

## WEIGHT

43.8 lbs

## INTERPRETED BY

Kathleen Sennello DVM,  
MS, Diplomate ACVIM  
(Small Animal Internal  
Medicine)

## IMAGING PERFORMED BY

Dr. Brittany Wolfe

## HOSPITAL NAME

HomeVets

## REFERRING VET

Dr. Brittany Wolfe

## INVOICE

73817

## DATE

3/19/26

## *Gastrointestinal*

The stomach contains a large amount of shadowing ingesta. It measures at a normal thickness of <0.7cm with some variability due to the presence of rugal folds. The distinction of the gastric wall layers is adequate and there is no impression of reduced peristaltic activity. Shadowing ingesta interferes with full evaluation of the stomach and some areas of the cranial abdomen.

The visualized areas of duodenum, jejunum and ileum have a relatively uniform diameter with minimal to moderate fluid/chyme distension. Wall thickness is normal. Bowel loops follow a curvilinear path with distinct wall layering maintaining the typical 1:3 muscularis:mucosa layer ratio. Duodenum wall measures 0.40 cm. Jejunum wall measures 0.25 cm. Visualized peristalsis appears appropriate. There were no focal lesions consistent with obstruction or a mass effect observed.

Sections of colon are visualized with formed fecal material and gas shadowing distally. The descending colon wall is slightly prominent, measuring 0.20 cm with intact wall layering.

## *Pancreas*

The area of the pancreas is normal and isoechoic to surrounding mesentery. There is no evidence of nodules or cystic lesions. There is no evidence of regional mesenteric inflammation or fluid.

## *Free Abdomen*

There is scant free fluid noted. No significant lymphadenopathy. Occasional prominent isoechoic mesenteric lymph nodes are visualized, examples measure 0.56 cm and 0.50 cm. The omentum is of normal echogenicity.

## ULTRASONOGRAPHIC FINDINGS

- No significant ultrasonographic lesions visualized.

## INTERPRETATION OF THE FINDINGS & FURTHER RECOMMENDATIONS

No significant abnormalities are visualized associated with the kidneys. Unfortunately, the appearance of the kidneys does not always correlate with renal function. Recommend continued monitoring of SDMA levels and urine concentrating ability as well as urine cultures.

Further workup for recurrent urinary tract infections could be considered if this is documented. This would include evaluation for anatomic causes (external genitalia, congenital issues such as ectopic ureters, etc.), or physiologic issues such as lack of urine concentrating ability, diabetes, Cushing's, etc. (many of these do not apply for this individual at this time).

The urinary bladder could not be definitively evaluated due to lack of urine. The appearance of the ureteral jets does not definitively rule out an ectopic ureter. This would likely require a contrast CT scan but is less likely in a patient that does not have issues with urinary incontinence.



**PATIENT**

Fern Sweeney

**SPECIES**

Canine

**BREED**

Border Collie

**SEX**

Spayed Female

**AGE**

1 Year 4 Months

**WEIGHT**

43.8 lbs

**INTERPRETED BY**

Kathleen Sennello DVM,  
MS, Diplomate ACVIM  
(Small Animal Internal  
Medicine)

**IMAGING  
PERFORMED BY**

Dr. Brittany Wolfe

**HOSPITAL NAME**

HomeVets

**REFERRING VET**

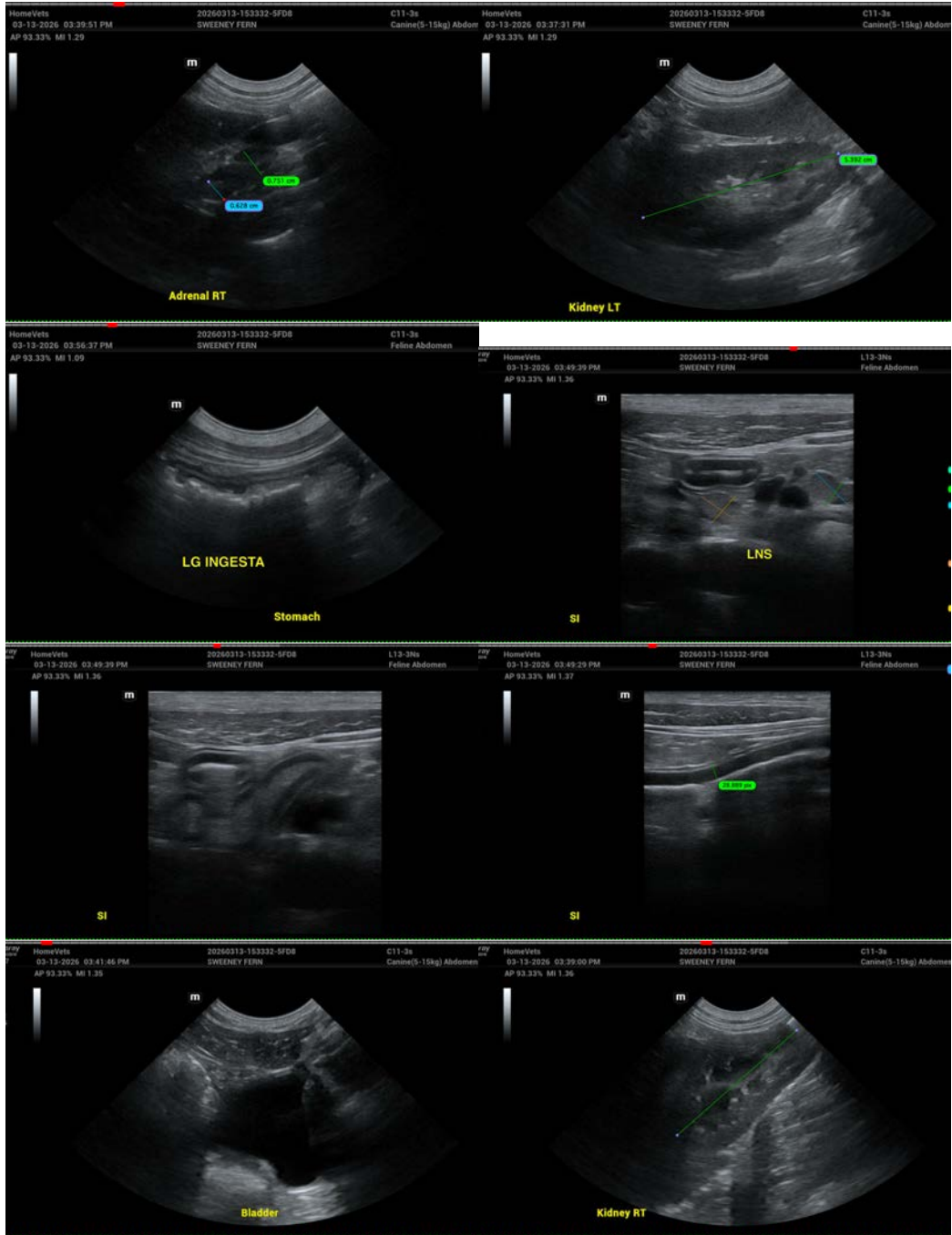
Dr. Brittany Wolfe

**INVOICE**

73817

**DATE**

3/19/26





## PATIENT

Fern Sweeney

## SPECIES

Canine

## BREED

Border Collie

## SEX

Spayed Female

## AGE

1 Year 4 Months

## WEIGHT

43.8 lbs

## INTERPRETED BY

Kathleen Sennello DVM,  
MS, Diplomate ACVIM  
(Small Animal Internal  
Medicine)

## IMAGING PERFORMED BY

Dr. Brittany Wolfe

## HOSPITAL NAME

HomeVets

## REFERRING VET

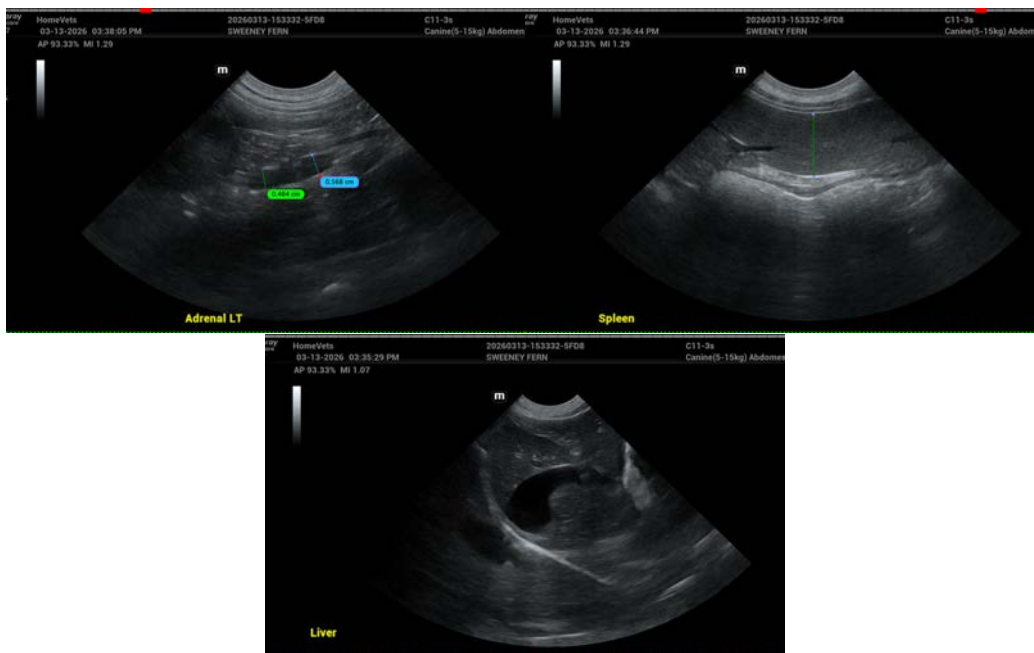
Dr. Brittany Wolfe

## INVOICE

73817

## DATE

3/19/26



The information and recommendations provided are based on the images presented by the referring veterinarian/sonographer. No evaluation can be communicated regarding pathology that was not visible in the image/video clips provided.

Thank you for this referral. If the clinical or image interpretation does not parallel your findings or if I can be of any further assistance please contact me.

Kathleen Sennello DVM,MS, Diplomate ACVIM (Small animal Internal Medicine)

info@sonopath.com