



PATIENT

Princess Someillan

SPECIES

Canine

BREED

Chihuahua

SEX

FS

AGE

10 years

WEIGHT

5.1 lbs

INTERPRETED BY

Kathleen Sennello DVM,
MS, Diplomate ACVIM
(Small Animal Internal
Medicine)

IMAGING PERFORMED BY

Dr. Gabriel Ferrer

HOSPITAL NAME

Pulse Pet Ultrasound
Services

REFERRING VET

Dr. Mario Roman

INVOICE

11503

DATE

3/18/2026

PRESENTING CLINICAL SIGNS

- Px presented as a referral for an abdominal ultrasound due to Pancreatitis Dx
- Px has been having episodes of vomiting and diarrhea since Saturday
- Px is currently hospitalized due to already elevated Lipase values continuing to increase (>1,000 first BW and now >2,000)
- Px is not vomiting at the moment, but the diarrhea persists

Abnormal PE/Chem/CBC/UA Results: rDVM records attached below for your reference.

ULTRASONOGRAPHIC EXAMINATION OF THE ABDOMEN

Urinary System

The urinary bladder is moderately distended with anechoic urine. The Bladder wall, trigone, ureteral papillae and visible urethra (to a depth of 2cm) appear normal with no evidence of wall thickening, mucosal irregularities, masses or cystic calculi.

The left kidney has a normal shape and is small in size (2.23 cm). Overall echogenicity is slightly hyperechoic with poor corticomedullary distinction and a typical 1:3 cortex:medulla ratio. There is no evidence of focal perinephric inflammation or effusion. Occasional pinpoint mineralizations noted. There is no evidence of pyelectasia, infarcts or hydroureter. Renal vasculature is normal.

The right kidney has a normal shape and size (3.51 cm). Overall echogenicity is slightly hyperechoic with poor corticomedullary distinction and a typical 1:3 cortex:medulla ratio. There is no evidence of focal perinephric inflammation or effusion. There is no evidence of pyelectasia, nephroliths, infarcts or hydroureter. Renal vasculature is normal.

Adrenal Glands

The left adrenal gland is normal in size measuring 0.48 cm at the cranial pole and 0.56 cm at the caudal pole. It is observed in its normal position cranial to the left renal artery. It is normal in appearance (uniformly hypoechoic) and shape with no evidence of a mass effect.

The right adrenal gland is normal in size measuring 0.48 cm at the cranial pole and 0.49 cm at the caudal pole. It is observed in its normal position between the cranial aspect of the right kidney and the caudal vena cava. It is normal in appearance (uniformly hypoechoic) and shape with no evidence of a mass effect.

Spleen

The spleen is subjectively normal in size (0.76 cm in width at the level of the hilus) and the echotexture is homogenous. The splenic capsule is smooth with no visible irregularities. The blood flow through the hilus and splenic parenchyma appears normal. There's a hypoechoic nodule in the spleen measuring 0.62 cm x 0.57 cm.

Liver

The liver is large in size, and normal in echogenicity with smooth peripheral margins. The parenchyma is heterogenous in echotexture with subtle, indistinct focal mottling. The visible portions of the



PATIENT

Princess Someillan

SPECIES

Canine

BREED

Chihuahua

SEX

FS

AGE

10 years

WEIGHT

5.1 lbs

INTERPRETED BY

Kathleen Sennello DVM,
MS, Diplomate ACVIM
(Small Animal Internal
Medicine)

IMAGING PERFORMED BY

Dr. Gabriel Ferrer

HOSPITAL NAME

Pulse Pet Ultrasound
Services

REFERRING VET

Dr. Mario Roman

INVOICE

11503

DATE

3/18/2026

vasculature and biliary tract appear normal. There are numerous somewhat poorly defined hypoechoic nodules visualized in the parenchyma. Examples measure 0.28 cm, 0.4 cm, and 0.39 cm.

The gall bladder lumen is moderately distended. The wall of the gall bladder is not thickened and has a smooth mucosal surface. There is a moderate amount of non-organized echogenic debris. The cystic and common bile ducts are normal/not visible.

Gastrointestinal

The stomach is moderately dilated with fluid and irregular shadowing material most consistent with normal ingesta and gas. It measures at a normal thickness of 0.27 cm with some variability due to the presence of rugal folds. The distinction of the gastric wall layering is adequate and there is no impression of reduced peristaltic activity. No masses or focal lesions were observed.

The visualized areas of duodenum, jejunum and ileum have a relatively uniform diameter with minimal to mild fluid and gas distension. Wall thickness is normal. Bowel loops follow a curvilinear path with distinct wall layering maintaining the typical 1:3 muscularis:mucosa layer ratio. The duodenum measured as normal (0.41 in wall thickness) and the jejunum measured as normal (0.31 cm.) Visualized peristalsis appears appropriate. Some sections of small intestine have mild fluid and gas distension, most consistent with mild enteritis.

Sections of colon are visualized with non-formed fecal material and gas shadowing distally. Descending colon wall measures 0.16 cm with intact wall layering.

Pancreas

The pancreas is large and hypoechoic to surrounding mesentery. There is no evidence of nodules or cystic lesions. There is evidence of regional mesenteric inflammation. Consistent with mild pancreatitis in the body of the pancreas.

Free Abdomen

Evaluation of the peritoneal cavity did not reveal any evidence of effusion. There's no significant lymphadenopathy. There is some reactive mesentery visualized around the body of the pancreas.

ULTRASONOGRAPHIC FINDINGS

- Decreased corticomedullary distinction with a smaller left kidney, and occasional cortical mineralizations. Mild loss of corticomedullary distinction in both kidneys could be consistent with chronic degenerative disease or interstitial nephrosis.
- Hypoechoic splenic nodules. There is a non-cavitated, hypoechoic splenic nodule visualized. Differentials include lymphoid hyperplasia, extramedullary hematopoiesis, infiltrative neoplasia, inflammation, other. Cytology or histopathology would be necessary to get a definitive diagnosis.
- Pancreatic changes most consistent with mild/moderate pancreatitis in the body of the pancreas. The pancreatic changes are most consistent with (mild/mod/severe) pancreatitis/pancreatic inflammation. Recommend fPLI testing and continued monitoring for improvement or possible development of a pancreatic abscess. Consider fine needle aspirate if not improving.



PATIENT

Princess Someillan

SPECIES

Canine

BREED

Chihuahua

SEX

FS

AGE

10 years

WEIGHT

5.1 lbs

INTERPRETED BY

Kathleen Sennello DVM,
MS, Diplomate ACVIM
(Small Animal Internal
Medicine)

IMAGING PERFORMED BY

Dr. Gabriel Ferrer

HOSPITAL NAME

Pulse Pet Ultrasound
Services

REFERRING VET

Dr. Mario Roman

INVOICE

11503

DATE

3/18/2026

- Heterogenous liver with ill-defined hypoechoic nodules. The diffuse hepatic changes are non-specific and could be consistent with vacuolar hepatopathy, nodular hyperplasia, inflammatory/immune-mediated disease, fibrosis, extramedullary hematopoiesis, toxic hepatopathy (e.g., copper), infiltrative neoplasia (less likely) or other hepatopathy. The nodules observed trend toward a more benign process, but underlying neoplasia cannot be ruled out.
- Moderate gallbladder debris. The significance of the aggregated gallbladder debris is unclear. This could represent an early mucocele, cholestasis, or may be secondary to fasting but seems unlikely to be causing a current issue. Recommend continued monitoring.
- Fluid/ingesta distended stomach and some sections of small intestine. Correlate with the feeding history. If the patient was adequately fasted, this could represent delayed gastric emptying, or a partial outflow tract obstruction (none visualized.)

INTERPRETATION OF THE FINDINGS & FURTHER RECOMMENDATIONS

The pancreas is prominent in the body of the pancreas with some reactive mesentery in the region. Findings are most consistent with mild to moderate pancreatitis. Additionally, the stomach is distended with fluid and ingesta and some sections of small intestine are mildly fluid distended. Possibly consistent with ileus and gastroenteritis (depending on feeding history.) The descending colon is somewhat prominent with intact wall layering and distension with non-formed fecal material, suggestive of colitis. No focal lesions are visualized associated with the GI tract to explain the symptoms reported. Consider the following:

- Consider a bland, ultra low fat diet.
- Consider screening for infectious causes of diarrhea.
- Recommend non-specific treatment for gastroenteritis.

If symptoms are persistent despite aggressive therapy, you could consider repeat imaging in the future looking for the progression of today's lesions or the development of new lesions. A small unseen focal lesion in the GI tract cannot be definitively ruled out.

Both kidneys have changes consistent with chronic renal disease. If lab work has not been rechecked since anesthesia, recommend reevaluation to confirm that no significant changes have occurred.

There's a hypoechoic nodule in the spleen. Options moving forward include continued monitoring with ultrasound +/- fine needle aspirate.

The liver is subjectively heterogenous with some ill-defined hypoechoic nodules. Generally, these have the appearance most consistent with benign regenerative nodules, but early neoplastic lesions cannot be definitively ruled out. If there's concern for significant liver disease or metastatic nodules, a fine needle aspirate could be considered.



PATIENT

Princess Someillan

SPECIES

Canine

BREED

Chihuahua

SEX

FS

AGE

10 years

WEIGHT

5.1 lbs

INTERPRETED BY

Kathleen Sennello DVM,
MS, Diplomate ACVIM
(Small Animal Internal
Medicine)

IMAGING PERFORMED BY

Dr. Gabriel Ferrer

HOSPITAL NAME

Pulse Pet Ultrasound
Services

REFERRING VET

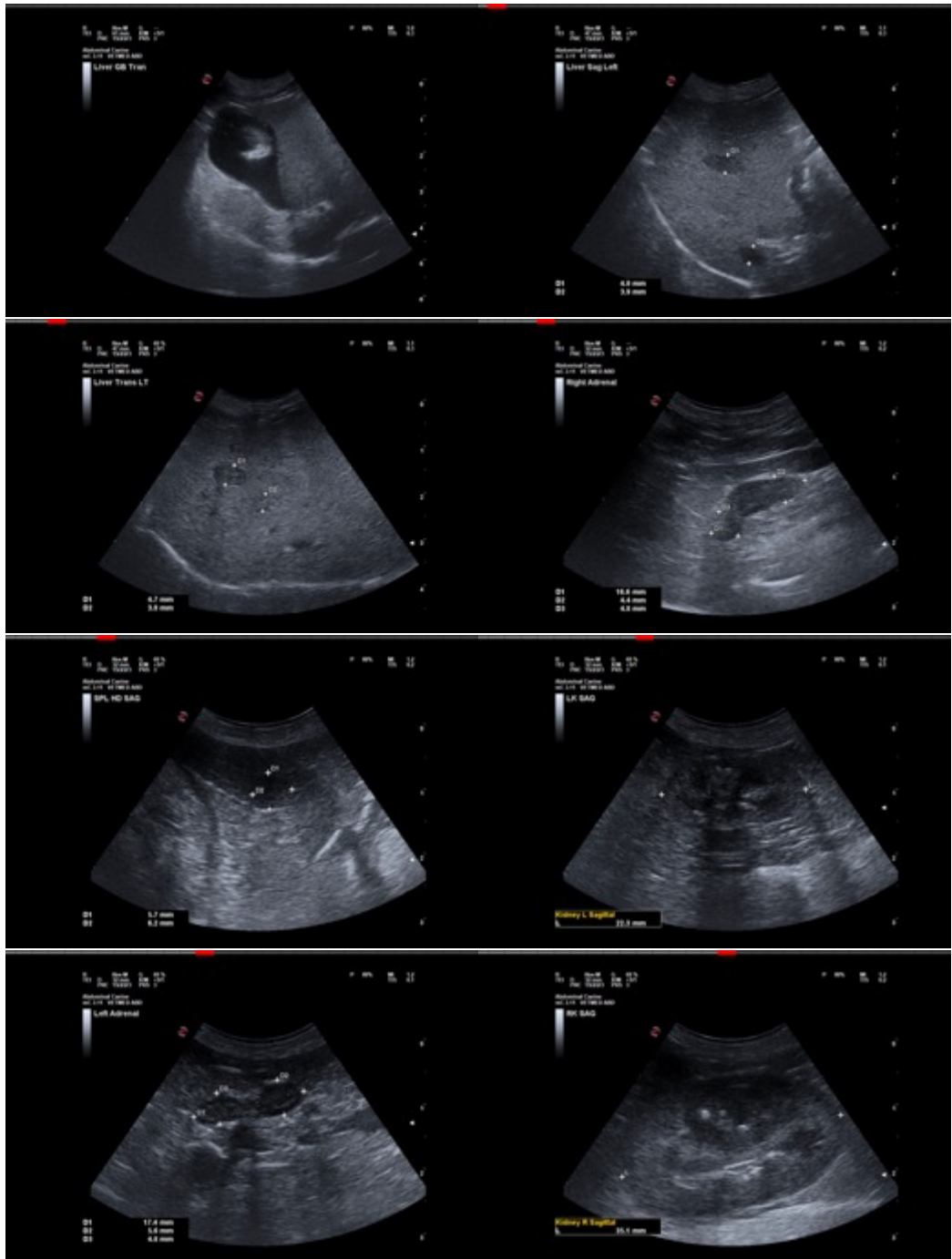
Dr. Mario Roman

INVOICE

11503

DATE

3/18/2026





PATIENT

Princess Someillan

SPECIES

Canine

BREED

Chihuahua

SEX

FS

AGE

10 years

WEIGHT

5.1 lbs

INTERPRETED BY

Kathleen Sennello DVM,
MS, Diplomate ACVIM
(Small Animal Internal
Medicine)

IMAGING PERFORMED BY

Dr. Gabriel Ferrer

HOSPITAL NAME

Pulse Pet Ultrasound
Services

REFERRING VET

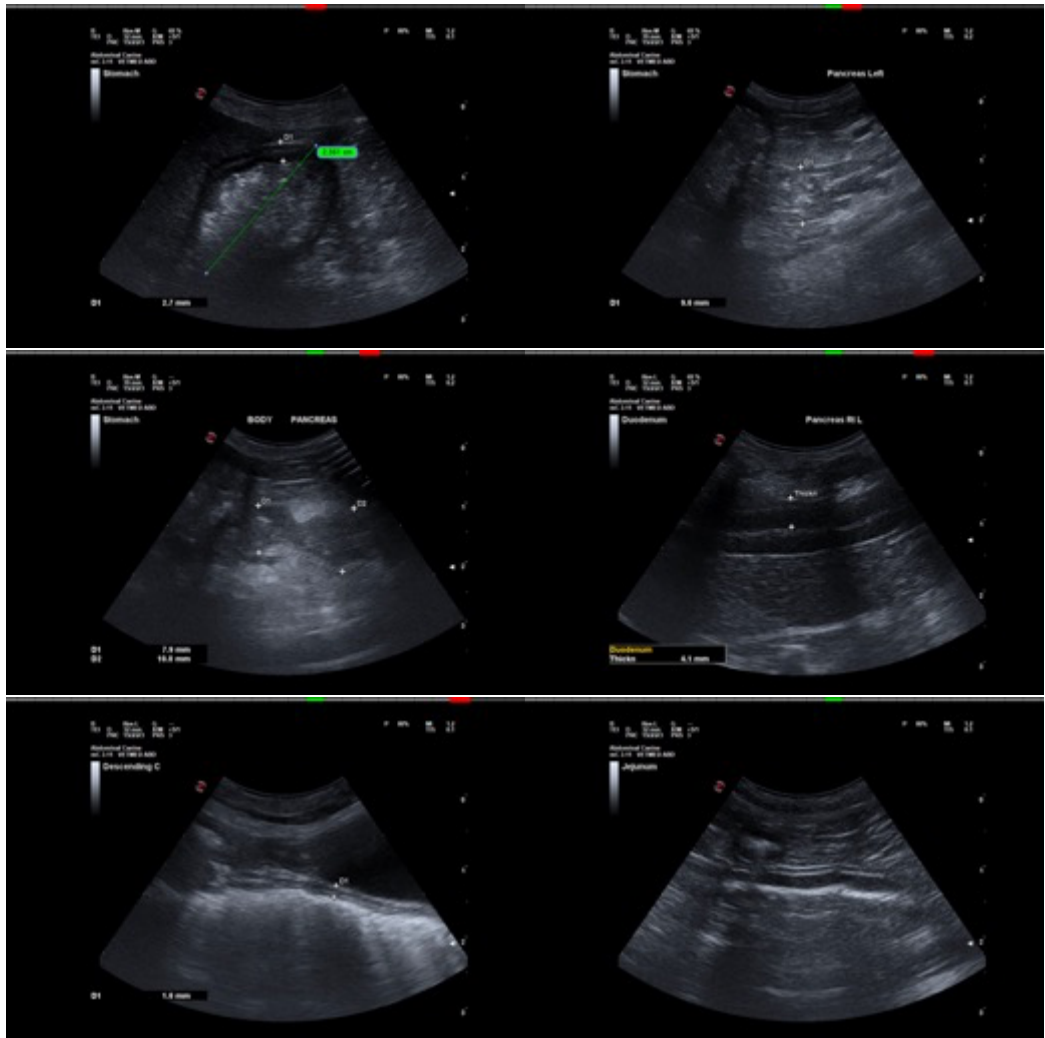
Dr. Mario Roman

INVOICE

11503

DATE

3/18/2026



The information and recommendations provided are based on the images presented by the referring veterinarian/sonographer. No evaluation can be communicated regarding pathology that was not visible in the image/video clips provided.

Thank you for this referral. If the clinical or image interpretation does not parallel your findings or if I can be of any further assistance please contact me.

Kathleen Sennello DVM,MS, Diplomate ACVIM (Small animal Internal Medicine)

info@sonopath.com