

PATIENT PRESENTING CLINICAL SIGNS

Amanda Ranahan
anorexia, hepatitis, pancreatitis meds: metacam, mirtazapine
Abnormal PE/Chem/CBC/UA Results: please see attached BW

SPECIES ULTRASONOGRAPHIC EXAMINATION OF THE ABDOMEN

Feline

Urinary System

BREED

Himalayan

The urinary bladder is moderately distended with mild primarily suspended echogenic debris present. The Bladder wall, trigone, ureteral papillae and visible urethra (to a depth of 2cm) appear normal with no evidence of wall thickening, mucosal irregularities, masses or calculi. Echogenic debris of this type can be associated with small crystals, cellular debris and proteinaceous debris.

SEX

Spayed Female

The left kidney has a normal shape and size (3.28 cm). Overall echogenicity is normal with adequate corticomedullary distinction and a typical 1:3 cortex:medulla ratio. There is no evidence of perinephric inflammation or effusion. There is no evidence of pyelectasia, nephroliths, infarcts or hydroureter. Renal vasculature is normal.

AGE

10 Years

The right kidney has a normal shape and size (3.63 cm). Overall echogenicity is normal with adequate corticomedullary distinction and a typical 1:3 cortex:medulla ratio. There is no evidence of perinephric inflammation or effusion. There is no evidence of pyelectasia, nephroliths, infarcts or hydroureter. Renal vasculature is normal.

WEIGHT

3.2 kg

Adrenal Glands

The left adrenal gland is normal in size measuring 0.28 cm at the caudal pole. It is observed in its normal position cranial to the left renal artery. It is normal in appearance (uniformly hypoechoic) and shape with no evidence of a mass effect.

INTERPRETED BY

Kathleen Sennello DVM,
MS, Diplomate ACVIM
(Small Animal Internal
Medicine)

The right adrenal gland is normal in size measuring 0.32 cm at the caudal pole. It is observed in its normal position between the cranial aspect of the right kidney and the caudal vena cava. It is normal in appearance (uniformly hypoechoic) and shape with no evidence of a mass effect.

IMAGING PERFORMED BY

Kelly Reschny

Spleen

The spleen is subjectively normal in size (0.91 cm in thickness at the level of the hilus), echotexture is homogenous, and the splenic capsule is smooth with no irregularities. The blood flow through the hilus and splenic parenchyma appears normal. No focal parenchymal abnormalities are visualized.

HOSPITAL NAME

Cat Hospital of
Burlington

Liver

The liver is large in size with smooth peripheral margins. The parenchyma is heterogenous in echotexture with subtle, indistinct focal mottling. The visible portions of the vasculature and biliary tract appear normal. No focal nodules or cystic lesions are observed.

REFERRING VET

Dr. O'Connor

The gallbladder lumen is moderately distended. The wall of the gall bladder is not thickened and has a smooth mucosal surface. Luminal contents are primarily anechoic. The cystic and common bile ducts are normal/not visible.

INVOICE

36291

Gastrointestinal

The stomach contains minimal luminal contents. It measures at a normal thickness of <0.36cm with some variability due to the presence of rugal folds. The distinction of the gastric wall layers is adequate and there is no impression of reduced peristaltic activity. No masses or focal lesions were observed.

DATE

3/17/22



PATIENT

Amanda Ranahan

The visualized areas of duodenum, jejunum and ileum have a relatively uniform diameter with minimal fluid distension. Wall thickness is normal. Bowel loops follow a curvilinear path with distinct wall layering maintaining the typical 1:3 muscularis:mucosa layer ratio. The duodenum measured as normal (between 0.13-0.38cm in wall thickness) and the jejunum measured as normal (between 0.15-0.36cm.) Visualized peristalsis appears appropriate. There were no focal lesions consistent with obstruction or a mass effect observed.

SPECIES

Feline

The ileocecal junction was visualized and exhibited normal intact wall layering and is subjectively of normal thickness. Sections of colon are visualized with formed fecal material and gas shadowing distally. There is no observed focal or generalized colon wall thickening or loss of layering.

BREED

Himalayan

Pancreas

The pancreas is prominent and hypoechoic as compared to the surrounding isoechoic mesentery. There is no evidence of nodules or cystic lesions. There is no evidence of regional mesenteric inflammation or fluid.

SEX

Spayed Female

Free Abdomen

Evaluation of the peritoneal cavity did not reveal any evidence of effusion, or subjective lymphadenomegaly. The Medial iliac nodes appear normal and there was no evidence of a caudal aortic thrombus at the bifurcation. The omentum is of normal uniform echogenicity.

AGE

10 Years

ULTRASONOGRAPHIC FINDINGS

WEIGHT

3.2 kg

- Hypoechoic prominent pancreas – The pancreatic changes are most consistent with mild pancreatitis or a recent episode of pancreatic inflammation.
- Large, heterogeneous liver – Hepatic changes are non-specific and could be consistent with inflammation/infection (cholangiohepatitis), infiltrative neoplasia, lipidosis or other hepatopathy.
- Echogenic debris in the urinary bladder – The echogenic debris in the bladder lumen could be consistent with cells, crystals, and/or mucus.

INTERPRETED BY

Kathleen Sennello DVM,
MS, Diplomate ACVIM
(Small Animal Internal
Medicine)

INTERPRETATION OF THE FINDINGS & FURTHER RECOMMENDATIONS

No focal lesions are visualized associated with the liver. The gallbladder appears relatively normal with a very mildly dilated proximal bile duct, which I was unable to follow beyond approximately 2.0 cm. No obstruction was noted. Findings would likely be most consistent with a primary hepatopathy. Additionally, there is a mildly prominent pancreas. These changes could be consistent with mild chronic pancreatitis, or a previous episode of pancreatitis.

IMAGING PERFORMED BY

Kelly Reschny

HOSPITAL NAME

Cat Hospital of
Burlington

REFERRING VET

Dr. O'Connor

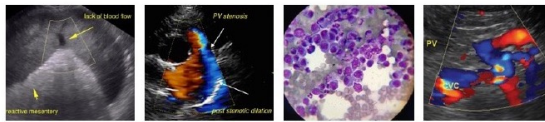
- Consider close evaluation of history for possible toxic changes examine medications, diet, dietary indiscretion etc..
- Recommend thyroid evaluation (if not already done)
- If not already done consider pre and post prandial bile acids to evaluate liver function
- Consider fine needle aspirate if round cell neoplasia is on your differential list (25 g needle, normal coags)
- If cytology is not helpful and there is no response to therapy, consider liver biopsy with samples obtained for histopathology and culture.

INVOICE

36291

DATE

3/17/22



PATIENT

Amanda Ranahan

- If triaditis is suspected consider therapy for cholangiohepatitis (fluids, antibiotics, +/- ursodiol, +/- steroids), testing for pancreatitis and evaluation for IBD (GI panel to Texas A&M GI lab)

SPECIES

Feline

In the lab work submitted, there is a neutropenia and thrombocytopenia evident as well as hypoglycemia. These could be artifact due to lab error, but if not, there could be concern for sepsis.

BREED

Himalayan

Consider three view thoracic radiographs to rule out concurrent thoracic disease/involvement.

SEX

Spayed Female

AGE

10 Years

WEIGHT

3.2 kg

INTERPRETED BY

Kathleen Sennello DVM,
MS, Diplomate ACVIM
(Small Animal Internal
Medicine)

**IMAGING
PERFORMED BY**

Kelly Reschny

HOSPITAL NAME

Cat Hospital of
Burlington

REFERRING VET

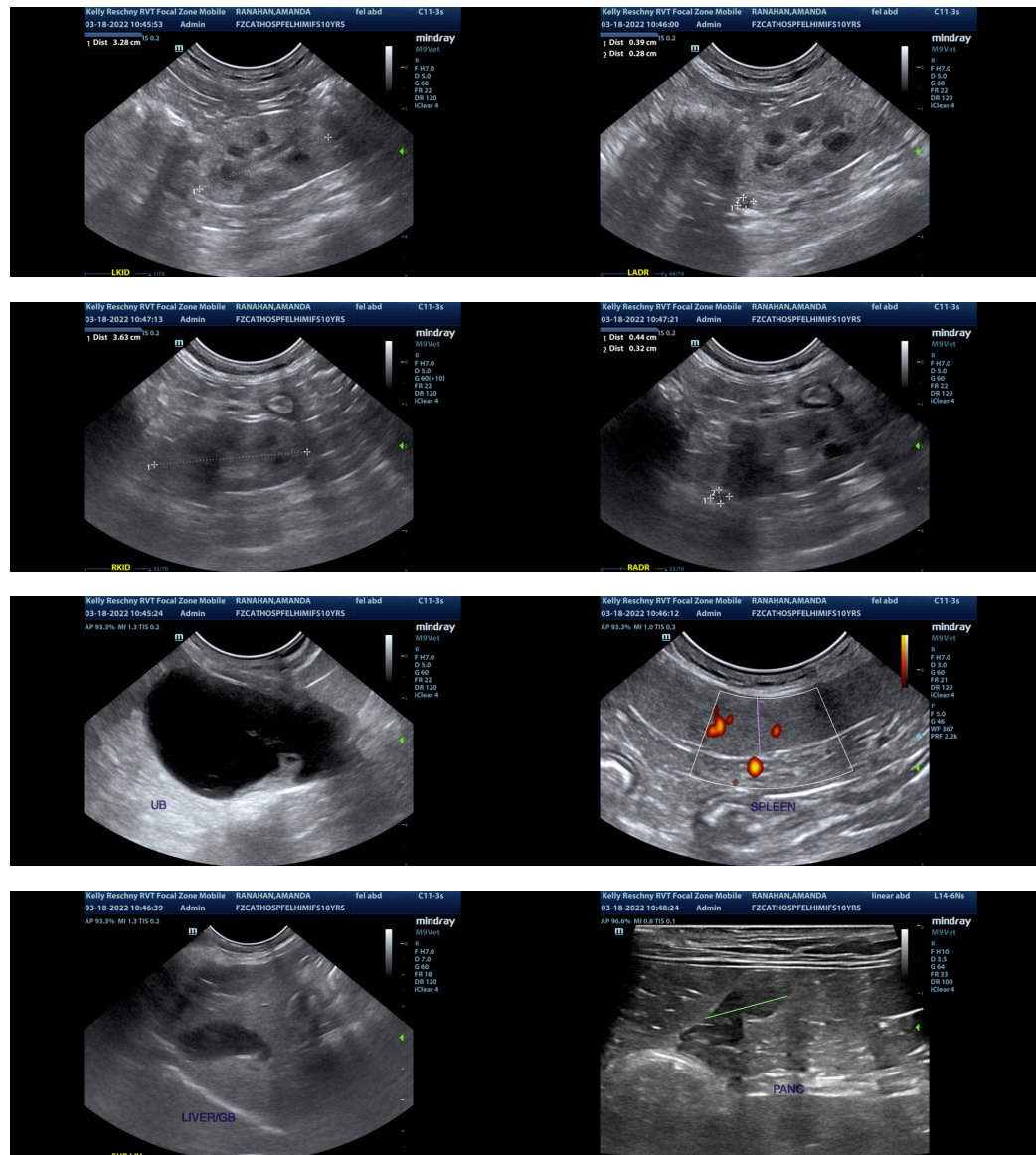
Dr. O'Connor

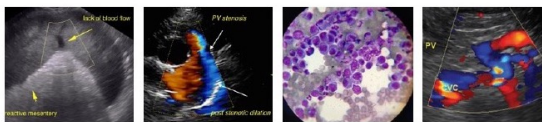
INVOICE

36291

DATE

3/17/22





PATIENT

Amanda Ranahan

The information and recommendations provided are based on the images presented by the referring veterinarian/sonographer. No evaluation can be communicated regarding pathology that was not visible in the image/video clips provided.

SPECIES

Feline

Thank you for this referral. If the clinical or image interpretation does not parallel your findings or if I can be of any further assistance please contact me.

Kathleen Sennello DVM,MS, Diplomate ACVIM (Small animal Internal Medicine)

kathleen.sennello@sonopath.com

BREED

Himalayan

SEX

Spayed Female

AGE

10 Years

WEIGHT

3.2 kg

INTERPRETED BY

Kathleen Sennello DVM,
MS, Diplomate ACVIM
(Small Animal Internal
Medicine)

**IMAGING
PERFORMED BY**

Kelly Reschny

HOSPITAL NAME

Cat Hospital of
Burlington

REFERRING VET

Dr. O'Connor

INVOICE

36291

DATE

3/17/22