



DATE PRESENTING CLINICAL SIGNS

3/17/26 **Patient History:** Bloody diarrhea. BW 1/6/26- monocytosis and eosinophilia. Fecal float 1/22/26 negative. Fecal PCR 3/2/26- clostridium perfringens alpha toxin positive, quantitative level 3.6×10^3 , this level is not likely to be contributing to diarrhea, no treatment recommended at this time.

PATIENT

Darryl Plunkett

Current Medications: NA, P will have gabapentin 100mg prior to the scan

SPECIES

Feline

Labwork Results: Labwork attached, reported as: Fecal PCR 3/2/26- clostridium perfringens alpha toxin positive, quantitative level 3.6×10^3 , this level is not likely to be contributing to diarrhea. Fasted GI panel pending day of AUS.

Date of Previous IntraPet Ultrasound: No previous.

Sedation: Not required to complete full diagnostic ultrasound.

Stat Report: Not requested.

BREED

DSH

Imaging Performed by: Rachel Brillhart, RDMS.

SEX

Neutered Male

ULTRASONOGRAPHIC EXAMINATION OF THE ABDOMEN

Urinary System

The urinary bladder is moderately distended with anechoic urine. The Bladder wall, trigone, ureteral papillae and visible urethra (to a depth of 2cm) appear normal with no evidence of wall thickening, mucosal irregularities, masses or cystic calculi.

AGE

8/19/15

The left kidney has a normal shape and size (4.28 cm) with mild pyelectasia at 0.23 cm. Overall echogenicity is normal with adequate corticomedullary distinction and a typical 1:3 cortex:medulla ratio. There is no evidence of focal perinephric inflammation or effusion. There is no evidence of nephroliths, infarcts or hydroureter. Renal vasculature is normal.

WEIGHT

16 lbs

The right kidney has a normal shape and size (4.19 cm) with mild pyelectasia at 0.22 cm. Overall echogenicity is normal with adequate corticomedullary distinction and a typical 1:3 cortex:medulla ratio. There is no evidence of focal perinephric inflammation or effusion. There is no evidence of nephroliths, infarcts or hydroureter. Renal vasculature is normal.

INTERPRETED BY

Kathleen Sennello DVM,
MS, Diplomate ACVIM
(Small Animal Internal
Medicine)

Adrenal Glands

The left adrenal gland is normal in size measuring 0.49 cm at the caudal pole. It is observed in its normal position cranial to the left renal artery. It is normal in appearance (uniformly hypoechoic) and shape with no evidence of a mass effect.

HOSPITAL NAME

Fallston Veterinary
Clinic

The right adrenal gland is normal in size measuring XX cm at the caudal pole. It is observed in its normal position between the cranial aspect of the right kidney and the caudal vena cava. It is normal in appearance (uniformly hypoechoic) and shape with no evidence of a mass effect.

REFERRING VET

Dr. Harvey

Spleen

The spleen is subjectively normal in size (0.76 cm), echotexture is homogenous, and the splenic capsule is smooth with no irregularities. The blood flow through the hilus and splenic parenchyma appears normal. No focal parenchymal abnormalities are visualized.

INVOICE

73749

Liver

The liver is subjectively normal in size, and echogenicity with smooth peripheral margins. The parenchyma is homogenous echotexture. The visible portions of the vasculature and biliary tract appear normal. No focal nodules or cystic lesions are observed.

The gall bladder lumen is moderately distended. The wall of the gall bladder is hyperechoic and slightly prominent but not overtly thickened. Luminal contents are mild and likely incidental at this time. The cystic and common bile ducts appear dilated and tortuous. The common bile duct is visualized measuring 0.44 cm and tapering to 0.23 cm distally.

Gastrointestinal

The stomach contains minimal luminal contents. It measures at a normal thickness of <0.36cm with some variability due to the presence of rugal folds. The distinction of the gastric wall layers is adequate and there is no impression of reduced peristaltic activity. No masses or focal lesions were observed.

The visualized areas of duodenum, jejunum and ileum have a uniform diameter with minimal fluid distension. Wall thickness is normal to slightly increased. Bowel loops follow a typical curvilinear path with distinct wall layering, but some areas display a prominent muscularis layer which does not display the typical 1:3 muscularis:mucosa layer ratio. Duodenum wall measures 0.27 cm. Jejunum wall measures 0.21 cm. Visualized peristalsis appears appropriate. There were no focal lesions consistent with obstruction or a mass effect observed.

The ileocecal junction was visualized and exhibited normal intact wall layering and is subjectively of normal thickness. Sections of colon are visualized with formed fecal material and gas shadowing distally. The proximal descending colon wall appears of normal thickness with intact wall layering, measuring at 0.14 cm. Distally there is focal thickening of the colon wall with loss of layering, creating a mass effect measuring approximately 0.93 cm x 1.59 cm.

Pancreas

The pancreas is visible/mildly mottled with prominent pancreatic duct. There is no evidence of nodules or cystic lesions. There is no evidence of regional mesenteric inflammation or fluid.

Free Abdomen

Evaluation of the peritoneal cavity did not reveal any evidence of effusion. There is no significant lymphadenopathy. A prominent colic lymph node is visualized measuring 0.21 cm. The omentum is generally normal in echogenicity.

ULTRASONOGRAPHIC FINDINGS

- Mild pyelectasia visualized associated with both kidneys – Pyelectasia of the kidney(s) could be consistent with pyelonephritis, chronic renal disease, secondary to PU/PD or fluid therapy (if applicable), other.
- Pancreatic changes most consistent with chronic pancreatic remodeling.
- Mildly/moderately dilated/tortuous bile duct – Dilation of the common bile duct could be consistent with a functional obstruction (i.e. primary hepatic disease resulting in hepatocellular swelling) or with an extrahepatic bile duct obstruction (ie. choledocholith, bile duct tumor, pancreatic disease, other).
- Focal thickening and loss of layering in the distal colon – Findings are concerning for a focal mass lesion/neoplasia. Severe focal inflammation or a benign lesion/granuloma, etc. is possible.

- Diffusely ropey small intestine with a prominent muscularis layer – The small intestinal wall changes are most consistent with an inflammatory process (i.e., inflammatory bowel disease) with a low possibility of emerging lymphoma.

INTERPRETATION OF THE FINDINGS & FURTHER RECOMMENDATIONS

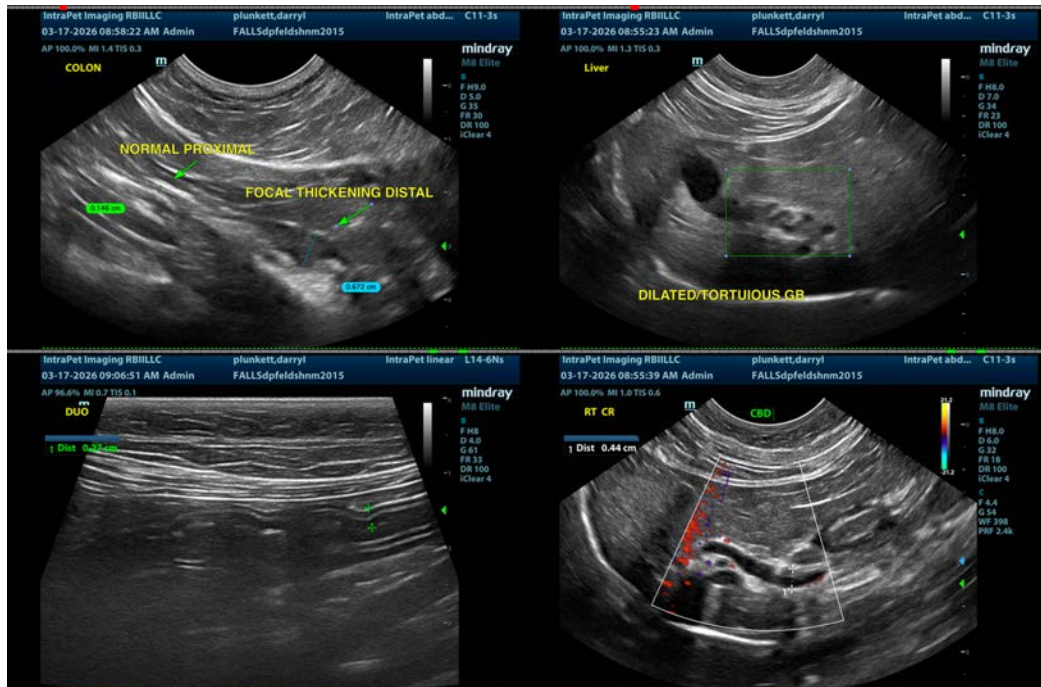
There is focal thickening and loss of layering in the distal colon. The appearance is concerning for a possible neoplastic process, although other inflammatory or infectious processes are possible. If a safe window for sampling is available, consider a fine needle aspirate. Otherwise, recommend colonoscopy to further evaluate and obtain biopsies.

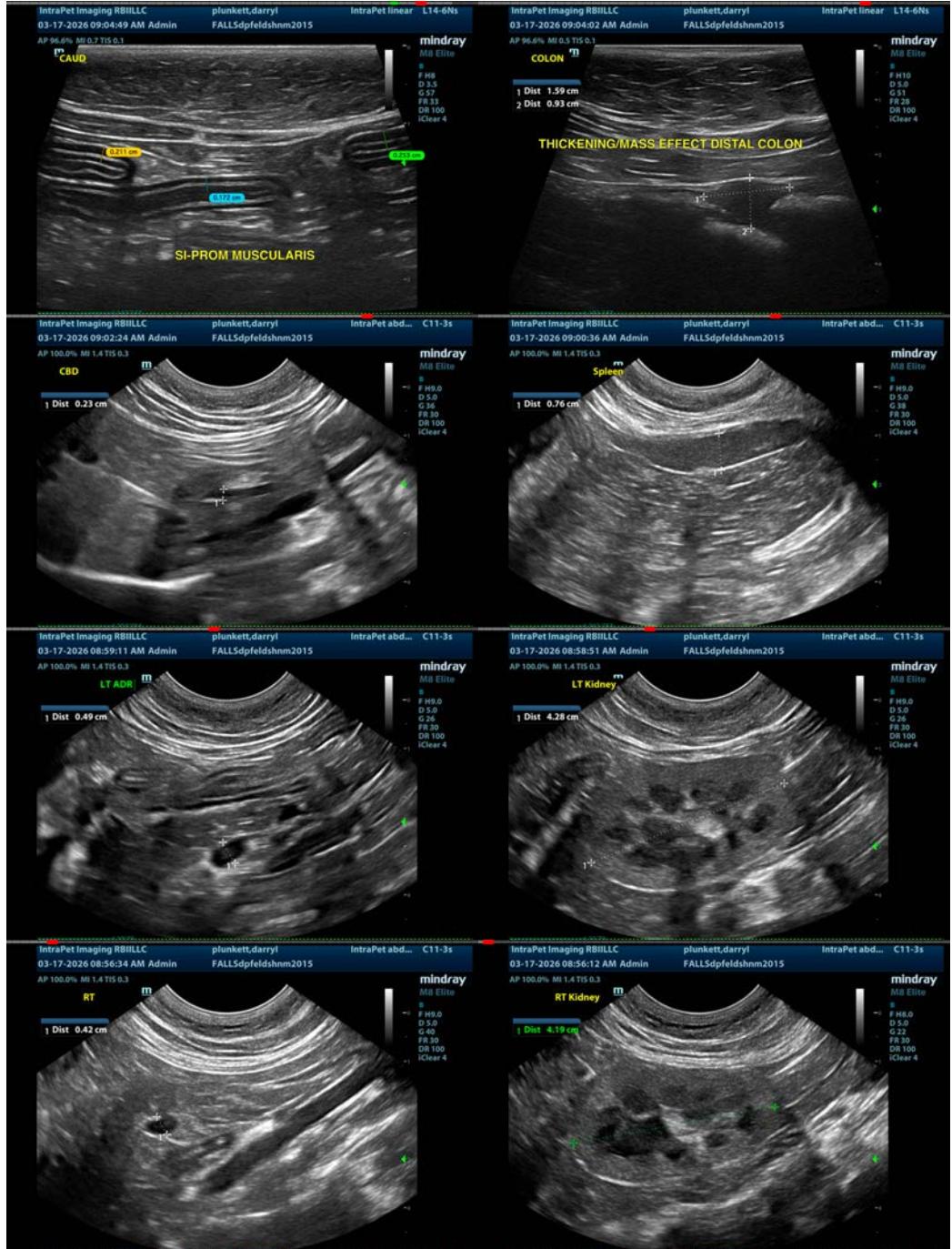
The small intestine appears diffusely “ropey” with a prominent muscularis layer. At this time, this has the appearance most consistent with an inflammatory type change, but early neoplastic change cannot be ruled out.

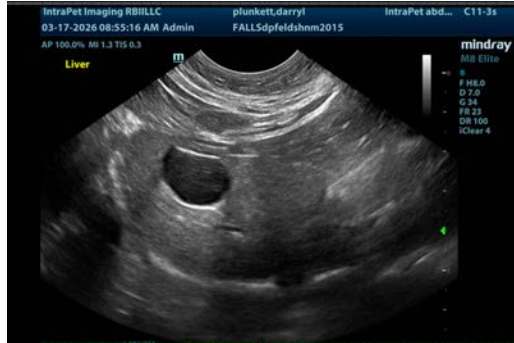Recommend urinalysis, culture and current bloodwork to further assess the renal changes described.

The significance of the biliary changes is uncertain. Correlate with current lab work. Empirical treatment for cholecystitis could be considered.

Recommend three view thoracic radiographs to evaluate for possible concurrent thoracic disease/involvement (disregard if this has already been done).







The information and recommendations provided are based on the images presented by the referring veterinarian/sonographer. No evaluation can be communicated regarding pathology that was not visible in the image/video clips provided.

Thank you for this referral. If the clinical or image interpretation does not parallel your findings or if I can be of any further assistance please contact me.

Kathleen Sennello DVM,MS, Diplomate ACVIM (Small animal Internal Medicine)
info@sonopath.com