



PATIENT

Stella Wingard

SPECIES

Canine

BREED

Golden Doodle

SEX

Spayed Female

AGE

5 Years

WEIGHT

64.2 Pounds

INTERPRETED BY

Kathleen Sennello DVM,
MS, Diplomate ACVIM
(Small Animal Internal
Medicine)

**IMAGING
PERFORMED BY**

Dr. Jessica Bailes

HOSPITAL NAME

All Creatures Great &
Small Corvallis

REFERRING VET

Dr. Chantal Litalian

INVOICE

36290

DATE

3/17/22

PRESENTING CLINICAL SIGNS

Recheck AUS after being diagnosed w/ severe pancreatitis and elevated liver values. Currently on denamarin, cerenia, metronidazole, amoxicillin and cerenia Patient doing well @ home.
Abnormal PE/Chem/CBC/UA Results: Possibly mildly icteric sclera, weight gain noted. Abdomen mildly tense cranial abdomen - butorphanol given IV to facilitate scanning; no obvious abdominal pain noted Recheck labs/urinalysis pending. - JLB

ULTRASONOGRAPHIC EXAMINATION OF THE ABDOMEN

Urinary System

The urinary bladder is moderately distended with anechoic urine. The Bladder wall, trigone, ureteral papillae and visible urethra (to a depth of 2cm) appear normal with no evidence of wall thickening, mucosal irregularities, masses or cystic calculi.

The left kidney has a normal shape and size (5.42 cm). Overall echogenicity is normal with adequate corticomedullary distinction and a typical 1:3 cortex:medulla ratio. There is no evidence of perinephric inflammation or effusion. There is no evidence of pyelectasia, nephroliths, infarcts or hydroureter. Renal vasculature is normal.

The right kidney has a normal shape and size (5.7 cm). Overall echogenicity is normal with adequate corticomedullary distinction and a typical 1:3 cortex:medulla ratio. There is no evidence of perinephric inflammation or effusion. There is no evidence of pyelectasia, nephroliths, infarcts or hydroureter. Renal vasculature is normal.

Adrenal Glands

The left adrenal gland is normal in size measuring 0.50 cm at the caudal pole. It is observed in its normal position cranial to the left renal artery. It is normal in appearance (uniformly hypoechoic) and shape with no evidence of a mass effect.

The right adrenal gland is normal in size measuring 0.44 cm at the caudal pole. It is observed in its normal position between the cranial aspect of the right kidney and the caudal vena cava. It is normal in appearance (uniformly hypoechoic) and shape with no evidence of a mass effect.

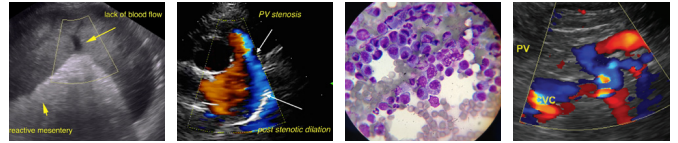
Spleen

The spleen is subjectively normal in size, echotexture is homogenous, and the splenic capsule is smooth with no irregularities. The blood flow through the hilus and splenic parenchyma appears normal. No focal parenchymal abnormalities are visualized.

Liver

The liver is large in size with smooth peripheral margins. The parenchyma is heterogenous in echotexture with subtle, indistinct focal mottling. The visible portions of the vasculature and biliary tract appear normal. No focal nodules or cystic lesions are observed.

The gallbladder lumen is distended, but normal. The wall of the gall bladder is not thickened and has a smooth mucosal surface. Luminal contents are primarily anechoic. The cystic and common bile ducts are normal/not visible.



PATIENT

Stella Wingard

Gastrointestinal

The stomach contains minimal luminal contents. It measures at a normal thickness of <0.7cm with some variability due to the presence of rugal folds. The distinction of the gastric wall layers is adequate and there is no impression of reduced peristaltic activity. No masses or focal lesions were observed.

SPECIES

Canine

The visualized areas of duodenum, jejunum and ileum have a relatively uniform diameter with minimal fluid distension. Wall thickness is normal. Bowel loops follow a curvilinear path with distinct wall layering maintaining the typical 1:3 muscularis:mucosa layer ratio. Duodenum wall measured 0.46 cm. Jejunum wall measured 0.31 cm. Visualized peristalsis appears appropriate. There were no focal lesions consistent with obstruction or a mass effect observed.

BREED

Golden Doodle

The ileocecal junction was visualized and exhibited normal intact wall layering and is subjectively of normal thickness. Sections of colon are visualized with formed fecal material and gas shadowing distally. There is no observed focal or generalized colon wall thickening or loss of layering.

SEX

Spayed Female

Pancreas

The pancreas is large and hypoechoic to surrounding mesentery. There is no evidence of nodules or cystic lesions. There is evidence of regional mesenteric inflammation. Consistent with moderate to severe pancreatitis. The pancreas appears stable to slightly improved.

AGE

5 Years

Free Abdomen

Evaluation of the peritoneal cavity did not reveal any evidence of effusion, or subjective lymphadenomegaly. The Medial iliac nodes appear normal and there was no evidence of a caudal aortic thrombus at the bifurcation. The omentum is of increased echogenicity around the pancreas.

WEIGHT

64.2 Pounds

ULTRASONOGRAPHIC FINDINGS

INTERPRETED BY

Kathleen Sennello DVM,
MS, Diplomate ACVIM
(Small Animal Internal
Medicine)

- Moderate/severe pancreatitis – The pancreatic changes are most consistent with moderate to severe pancreatitis/pancreatic inflammation. Recommend fPLI testing and continued monitoring for improvement or possible development of a pancreatic abscess. Consider fine needle aspirate if not improving. The pancreas appears stable to slightly improved from the previous scan on 3/10/22.

IMAGING PERFORMED BY

Dr. Jessica Bailes

- Large, heterogeneous liver – The diffuse hepatic changes are non-specific and could be consistent with vacuolar hepatopathy, nodular hyperplasia, inflammatory/immune-mediated disease, fibrosis, extramedullary hematopoiesis, toxic hepatopathy (e.g., copper), infiltrative neoplasia (less likely) or other hepatopathy.

HOSPITAL NAME

All Creatures Great &
Small Corvallis

- Distended gallbladder – The gallbladder is distended with no evidence of echogenic material. A dilated bile duct is not clearly visualized.

REFERRING VET

Dr. Chantal Litalian

- Focal hyperechoic mesentery surrounding the pancreatitis – Findings are most consistent with focal reactive pancreatitis.

INTERPRETATION OF THE FINDINGS & FURTHER RECOMMENDATIONS

INVOICE

36290

The pancreas is still very prominent and hypoechoic with surrounding hyperechoic mesentery, but the focal hypoechoic region that was concerning for development of an abscess is not clearly visualized, so I am hoping that it is slightly improved. Additionally, the surrounding mesentery might be slightly less prominent and less hazy. Visual improvement of the pancreas typically lags behind clinical improvement, but if the pancreatitis is progressing and getting worse, this is typically evident.

DATE

3/17/22



PATIENT

Stella Wingard

Correlate these findings with blood work findings (are the bilirubin and liver enzymes improving?). If not, then you may need to consider a fine needle aspirate of the liver +/- pancreas. If all areas are improving, then consider reevaluation in 2-3 weeks.

SPECIES

Canine

BREED

Golden Doodle

SEX

Spayed Female

AGE

5 Years

WEIGHT

64.2 Pounds

INTERPRETED BY

Kathleen Sennello DVM,
MS, Diplomate ACVIM
(Small Animal Internal
Medicine)

**IMAGING
PERFORMED BY**

Dr. Jessica Bailes

HOSPITAL NAME

All Creatures Great &
Small Corvallis

REFERRING VET

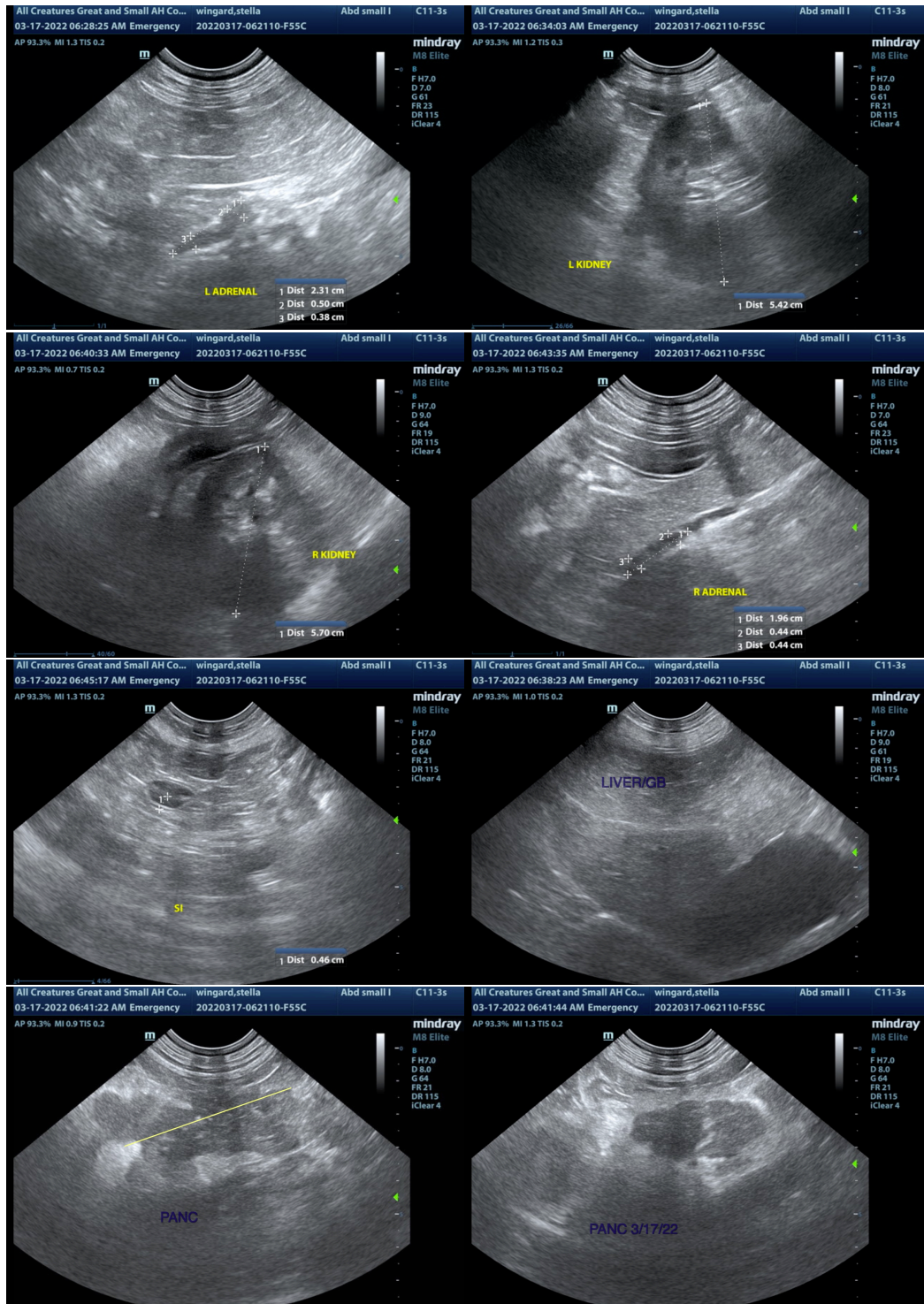
Dr. Chantal Litalian

INVOICE

36290

DATE

3/17/22





PATIENT

Stella Wingard

SPECIES

Canine

BREED

Golden Doodle

SEX

Spayed Female

AGE

5 Years

WEIGHT

64.2 Pounds

INTERPRETED BY

Kathleen Sennello DVM,
MS, Diplomate ACVIM
(Small Animal Internal
Medicine)

**IMAGING
PERFORMED BY**

Dr. Jessica Bailes

HOSPITAL NAME

All Creatures Great &
Small Corvallis

REFERRING VET

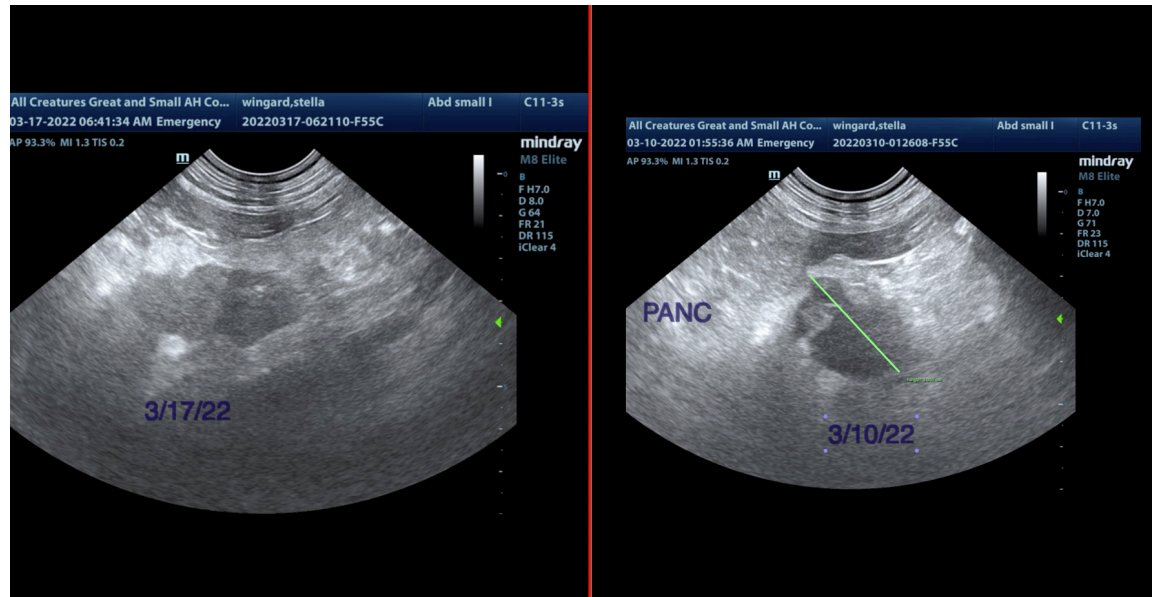
Dr. Chantal Litalian

INVOICE

36290

DATE

3/17/22



The information and recommendations provided are based on the images presented by the referring veterinarian/sonographer. No evaluation can be communicated regarding pathology that was not visible in the image/video clips provided.

Thank you for this referral. If the clinical or image interpretation does not parallel your findings or if I can be of any further assistance please contact me.

Kathleen Sennello DVM,MS, Diplomate ACVIM (Small animal Internal Medicine)

kathleen.sennello@sonopath.com