

**PATIENT PRESENTING CLINICAL SIGNS**

**PATIENT** Greg Greenhill  
Abdominal pain, was given Gabapentin for ultrasound but still quite tense and stressed. Fullness felt on palpation, decreased appetite and energy, salt seeking behaviour.

**SPECIES** Feline  
Abnormal PE/Chem/CBC/UA Results: From August mild elevation in Bilirubin, Amylase, regenerative anemia, leukopenia. Owner said previous U/A was done elsewhere and was normal. August bloodwork at previous clinic - T bili high 9.8, Amylase high 1953, Low WBCs 2.4, RBCs low 2.5, Hemoglobin Low 50, Low Hematocrit 13, MCHC high 389, Platelet count Low 70, Low Lymphs, Low Neuts, FIV negative, High retics, high absolute retics. Feline Hemoplasma PCR panel negative.

**BREED ULTRASONOGRAPHIC EXAMINATION OF THE ABDOMEN**

DSH

**Urinary System**

**SEX**

Neutered Male

The urinary bladder is moderately distended with anechoic urine. The Bladder wall, trigone, ureteral papillae and visible urethra (to a depth of 2cm) appear normal with no evidence of wall thickening, mucosal irregularities, masses or cystic calculi.

**AGE**

11 Years

The left kidney has a normal shape and size (3.85 cm). Overall echogenicity is normal with adequate corticomedullary distinction and a typical 1:3 cortex:medulla ratio. There is no evidence of perinephric inflammation or effusion. There is no evidence of pyelectasia, nephroliths, infarcts or hydroureter. Renal vasculature is normal.

**WEIGHT**

5.13 kg

The right kidney has a normal shape and size (4.37 cm). Overall echogenicity is normal with adequate corticomedullary distinction and a typical 1:3 cortex:medulla ratio. There is no evidence of perinephric inflammation or effusion. There is no evidence of pyelectasia, nephroliths, infarcts or hydroureter. Renal vasculature is normal.

**INTERPRETED BY**

Kathleen Sennello DVM,  
MS, Diplomate ACVIM  
(Small Animal Internal  
Medicine)

**Adrenal Glands**

The left adrenal gland is normal in size measuring 0.39 cm at the caudal pole. It is observed in its normal position cranial to the left renal artery. It is normal in appearance (uniformly hypoechoic) and shape with no evidence of a mass effect.

The right adrenal gland is normal in size measuring 0.38 cm at the caudal pole. It is observed in its normal position between the cranial aspect of the right kidney and the caudal vena cava. It is normal in appearance (uniformly hypoechoic) and shape with no evidence of a mass effect.

**IMAGING PERFORMED BY**

Crystal Hill

**Spleen**

**HOSPITAL NAME**

Sixteen Mile VC

The spleen is large in size (1.7 cm in width at the level of the hilus). The spleen echotexture is heterogenous and mildly mottled, the splenic capsule is smooth with no irregularities. The blood flow through the hilus and splenic parenchyma appears normal. No focal parenchymal abnormalities are visualized.

**REFERRING VET**

Dr. Gibbs

**Liver**

The liver is subjectively normal in size, and echogenicity with smooth peripheral margins. The parenchyma is homogenous echotexture. The visible portions of the vasculature and biliary tract appear normal. No focal nodules or cystic lesions are observed.

**INVOICE**

36288

The gallbladder lumen is moderately distended. The wall of the gall bladder is not thickened and has a smooth mucosal surface. Luminal contents are primarily anechoic. The bile duct is prominent, measuring 0.27 cm with no observable obstruction.

**DATE**

3/17/22



**PATIENT** *Gastrointestinal*

**Greg Greenhill**  
The stomach is moderately dilated with fluid and irregular shadowing material most consistent with normal ingesta and gas. It measures at a normal thickness of <0.36cm with some variability due to the presence of rugal folds. The distinction of the gastric wall layering is adequate and there is no impression of reduced peristaltic activity. No masses or focal lesions were observed.

**SPECIES**

**Feline**  
The visualized areas of duodenum, jejunum and ileum have a relatively uniform diameter with minimal fluid distension. Wall thickness is normal. Bowel loops follow a curvilinear path with distinct wall layering maintaining the typical 1:3 muscularis:mucosa layer ratio. The duodenum measured as normal (between 0.13-0.38cm in wall thickness) and the jejunum measured as normal (between 0.15-0.36cm.) Visualized peristalsis appears appropriate. There were no focal lesions consistent with obstruction or a mass effect observed.

**BREED**

DSH

**SEX**

Neutered Male

The ileocecal junction was visualized and exhibited normal intact wall layering and is subjectively of normal thickness. Sections of colon are visualized with formed fecal material and gas shadowing distally. There is no observed focal or generalized colon wall thickening or loss of layering.

**AGE**

11 Years

*Pancreas*

The pancreas is normal and isoechoic to surrounding mesentery. There is no evidence of nodules or cystic lesions. There is no evidence of regional mesenteric inflammation or fluid.

*Free Abdomen*

**WEIGHT**

5.13 kg

There is scant amount of free abdominal fluid. No lymphadenomegaly. The omentum is generally of normal echogenicity.

**ULTRASONOGRAPHIC FINDINGS**

**INTERPRETED BY**

Kathleen Sennello DVM,  
MS, Diplomate ACVIM  
(Small Animal Internal  
Medicine)

- Large, mottled spleen
- Moderate shadowing material within the gastric lumen - Correlate with feedings history and abdominal radiographs. If adequately fasted then consider such differentials as delayed gastric emptying or a partial outflow tract obstruction (none visualized).
- Scant free fluid

**IMAGING PERFORMED BY**

Crystal Hill

**INTERPRETATION OF THE FINDINGS & FURTHER RECOMMENDATIONS**

**HOSPITAL NAME**

Sixteen Mile VC

I suspect the abdominal pain reported is due to the large swollen spleen. Based on the history provided, there is a significant regenerative anemia and elevated bilirubin levels. I suspect the spleen is involved either in producing more red blood cells (extramedullary hematopoiesis) and/or in clearing cells (erythrophagocytosis, etc.). A full workup is recommended to try to determine the cause of the regenerative anemia and red blood cell destruction.

**REFERRING VET**

Dr. Gibbs

- Recommend a pathologist review of the CBC.
- Recommend a fine needle aspirate of the spleen.

**INVOICE**

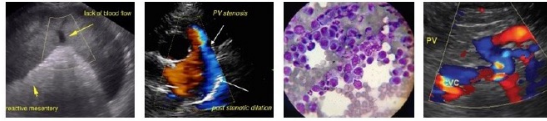
36288

- Recommend comprehensive infectious disease testing (I prefer the feline comprehensive panel through NC State's vector borne disease lab). Once diagnostic testing is submitted, consider starting Doxycycline therapy.

**DATE**

3/17/22

- Consider three view thoracic radiographs to rule out concurrent thoracic disease/involvement.



**PATIENT**

- Based on these test results, additional therapeutics and diagnostics can be considered.

Greg Greenhill

If this patient is not stable, recommend a blood transfusion, blood typing, etc.

**SPECIES**

Feline

**BREED**

DSH

**SEX**

Neutered Male

**AGE**

11 Years

**WEIGHT**

5.13 kg

**INTERPRETED BY**

Kathleen Sennello DVM,  
MS, Diplomate ACVIM  
(Small Animal Internal  
Medicine)

**IMAGING  
PERFORMED BY**

Crystal Hill

**HOSPITAL NAME**

Sixteen Mile VC

**REFERRING VET**

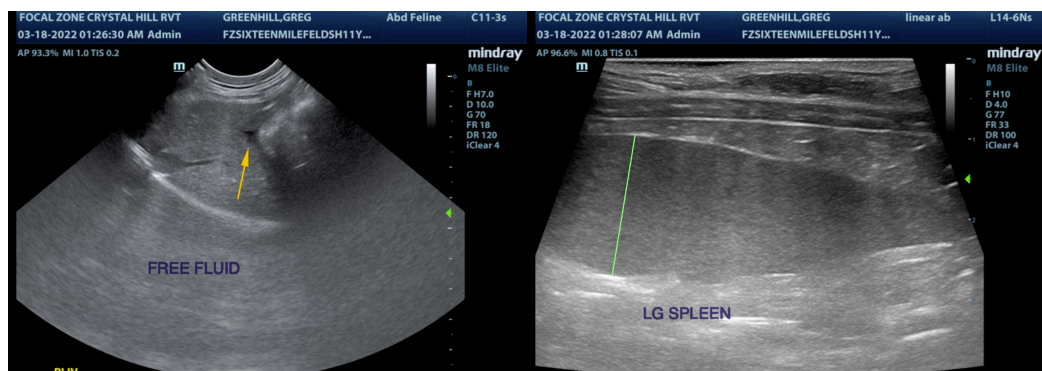
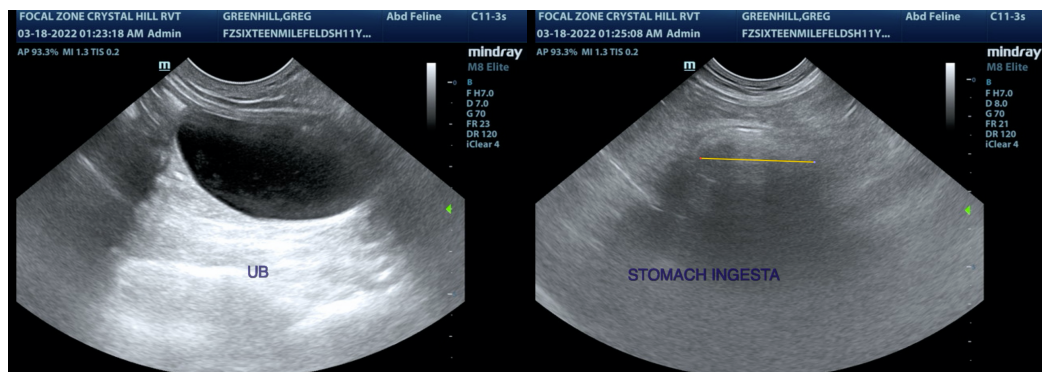
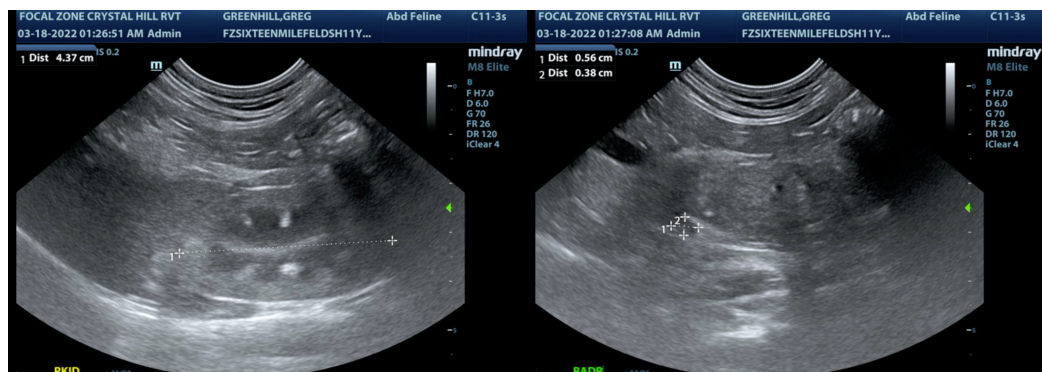
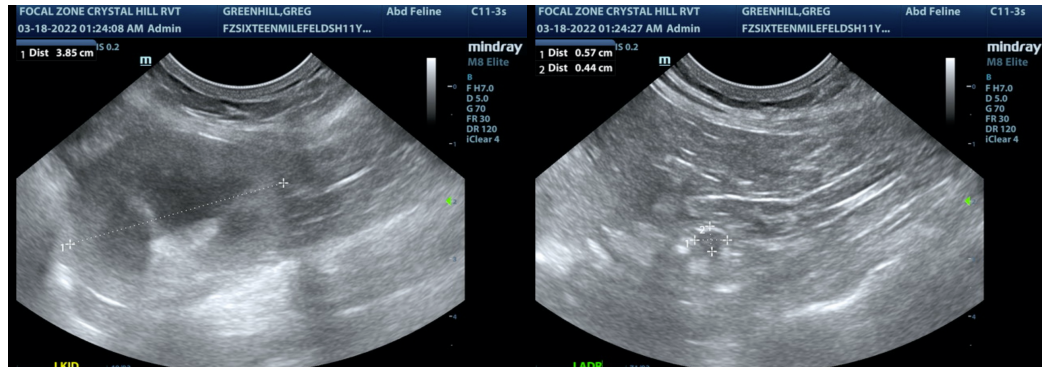
Dr. Gibbs

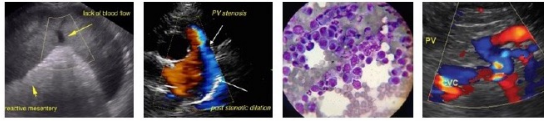
**INVOICE**

36288

**DATE**

3/17/22





## PATIENT

Greg Greenhill

## SPECIES

Feline

## BREED

DSH

## SEX

Neutered Male

## AGE

11 Years

## WEIGHT

5.13 kg

## INTERPRETED BY

Kathleen Sennello DVM,  
MS, Diplomate ACVIM  
(Small Animal Internal  
Medicine)

## IMAGING PERFORMED BY

Crystal Hill

## HOSPITAL NAME

Sixteen Mile VC

## REFERRING VET

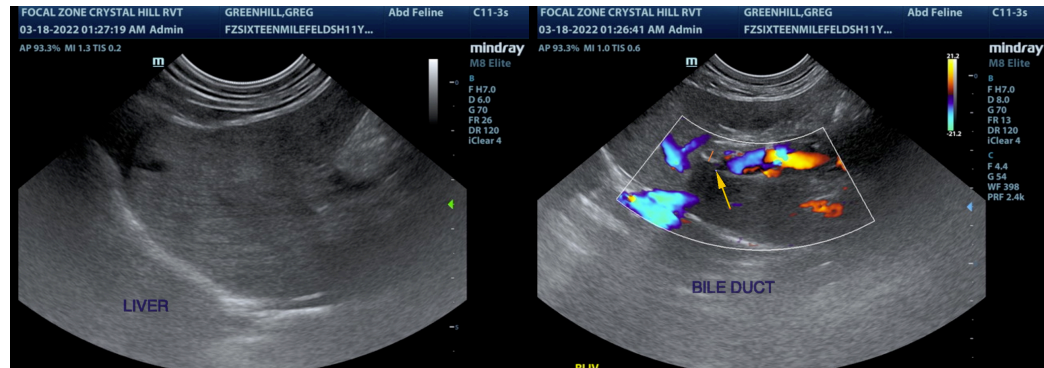
Dr. Gibbs

## INVOICE

36288

## DATE

3/17/22



The information and recommendations provided are based on the images presented by the referring veterinarian/sonographer. No evaluation can be communicated regarding pathology that was not visible in the image/video clips provided.

Thank you for this referral. If the clinical or image interpretation does not parallel your findings or if I can be of any further assistance please contact me.

Kathleen Sennello DVM,MS, Diplomate ACVIM (Small animal Internal Medicine)

kathleen.sennello@sonopath.com