



**PATIENT PRESENTING CLINICAL SIGNS**

**PATIENT**  
Risa Davis  
Lethargy and recent polydipsia. Lethargy has worsened and longer duration urinating, but not frequency. On IVF currently.

**SPECIES**  
Canine  
Abnormal PE/Chem/CBC/UA Results: Neutropenia with increased Bands. USG 1.003, sediment nonactive. Chem/CBC/CPL/electrolytes: WNL RADS (attached): mass or mineral/stone in stomach, subjective enlargement of L kidney and liver.

**ULTRASONOGRAPHIC EXAMINATION OF THE ABDOMEN**

**BREED**  
Mix  
*Urinary System*

The urinary bladder is moderately distended with anechoic urine. The Bladder wall, trigone, ureteral papillae and visible urethra (to a depth of 2cm) appear normal with no evidence of wall thickening, mucosal irregularities, masses or cystic calculi.

**SEX**

Spayed Female  
The left kidney has a normal shape and size (6.15 cm). Overall echogenicity is normal with adequate corticomedullary distinction and a typical 1:3 cortex:medulla ratio. There is no evidence of perinephric inflammation or effusion. There is no evidence of pyelectasia, nephroliths, infarcts or hydroureter. Renal vasculature is normal.

**AGE**

7 Years  
The right kidney has a normal shape and size (6.53 cm). Overall echogenicity is normal with adequate corticomedullary distinction and a typical 1:3 cortex:medulla ratio. There is no evidence of perinephric inflammation or effusion. There is no evidence of pyelectasia, nephroliths, infarcts or hydroureter. Renal vasculature is normal.

**WEIGHT**

72 Pounds

*Adrenal Glands*

The left adrenal gland is normal in size measuring 0.85 cm at the caudal pole. It is observed in its normal position cranial to the left renal artery. It is normal in appearance (uniformly hypoechoic) and shape with no evidence of a mass effect.

The region of the right adrenal (between right cranial kidney and vena cava) is unremarkable, but the adrenal is not distinctly visualized. No evidence of a mass effect.

*Spleen*

The spleen is subjectively normal in size. The spleen echotexture is heterogenous and mildly mottled. The blood flow through the hilus and splenic parenchyma appears normal. A small hypoechoic nodule is visualized towards the periphery measuring 1.54 cm. This does not deform the splenic capsule significantly.

*Liver*

The liver is subjectively normal/borderline small in size, and echogenicity with smooth peripheral margins. The parenchyma is mildly heterogenous in echotexture with subtle, indistinct focal mottling. The visible portions of the vasculature and biliary tract appear normal. No focal nodules or cystic lesions are observed.

The gall bladder lumen is moderately distended. The wall of the gall bladder is not thickened and has a smooth mucosal surface. There is a moderate amount of non-organized echogenic debris. The cystic and common bile ducts are normal/not visible.

**INTERPRETED BY**

Kathleen Sennello DVM,  
MS, Diplomate ACVIM  
(Small Animal Internal  
Medicine)

**IMAGING PERFORMED BY**

Dr. Ebersole

**HOSPITAL NAME**

Scanvet

**REFERRING VET**

Dr. Kaltsas

**INVOICE**

36230

**DATE**

3/16/22



**PATIENT**

***Gastrointestinal***

Risa Davis

The stomach contains minimal luminal contents. It measures at a normal thickness of <0.7cm with some variability due to the presence of rugal folds. The distinction of the gastric wall layers is adequate and there is no impression of reduced peristaltic activity. No masses or focal lesions were observed.

**SPECIES**

Canine

The visualized areas of duodenum, jejunum and ileum have a relatively uniform diameter with minimal fluid distension. Wall thickness is normal. Bowel loops follow a curvilinear path with distinct wall layering maintaining the typical 1:3 muscularis:mucosa layer ratio. The duodenum measured as normal (between 0.3-0.5cm in wall thickness) and the jejunum measured as normal (between 0.2-0.47cm.)

**BREED**

Mix

Visualized peristalsis appears appropriate. There were no focal lesions consistent with obstruction or a mass effect observed.

**SEX**

Spayed Female

The ileocecal junction was visualized and exhibited normal intact wall layering and is subjectively of normal thickness. Sections of colon are visualized with formed fecal material and gas shadowing distally. There is no observed focal or generalized colon wall thickening or loss of layering.

***Pancreas***

**AGE**

7 Years

The pancreas is normal and isoechoic to surrounding mesentery. There is no evidence of nodules or cystic lesions. There is no evidence of regional mesenteric inflammation or fluid.

***Free Abdomen***

**WEIGHT**

72 Pounds

Evaluation of the peritoneal cavity did not reveal any evidence of effusion, or subjective lymphadenomegaly. The Medial iliac nodes appear normal and there was no evidence of a caudal aortic thrombus at the bifurcation. The omentum is of normal uniform echogenicity.

**ULTRASONOGRAPHIC FINDINGS**

**INTERPRETED BY**

Kathleen Sennello DVM,  
MS, Diplomate ACVIM  
(Small Animal Internal  
Medicine)

- Mildly mottled spleen with hypoechoic nodule – There is a non-cavitated, hypoechoic splenic nodule visualized. Differentials include lymphoid hyperplasia, extramedullary hematopoiesis, infiltrative neoplasia, inflammation, other. Cytology or histopathology would be necessary to get a definitive diagnosis.
- Borderline heterogeneous/small liver – The diffuse hepatic changes are non-specific and could be consistent with vacuolar hepatopathy, nodular hyperplasia, inflammatory/immune-mediated disease, fibrosis, extramedullary hematopoiesis, toxic hepatopathy (e.g., copper), infiltrative neoplasia (less likely) or other hepatopathy.
- Moderate gallbladder sludge – The significance of the aggregated gallbladder sludge is unclear. This could represent an early mucocele, cholestasis, or may be secondary to fasting. The gallbladder wall appears relatively normal, and there is no surrounding fluid or inflammation noted.

**IMAGING PERFORMED BY**

Dr. Ebersole

**HOSPITAL NAME**

Scanvet

**REFERRING VET**

Dr. Kaltsas

**INTERPRETATION OF THE FINDINGS & FURTHER RECOMMENDATIONS**

No prominent focal lesions were visualized on today's exam. There is a small, hypoechoic nodule in the spleen. Recommend a fine needle aspirate of this lesion and 3-view thoracic radiographs.

**INVOICE**

36230

Additionally, the liver is subjectively small and slightly heterogeneous. This can be normal for some dogs, particularly in deep chested dogs. If there is concern for the liver being a source of the PU/PD reported, recommend a liver function test, screening for Leptospirosis, and possibly a fine needle aspirate of the liver.

**DATE**

3/16/22



**PATIENT**

Risa Davis

It was noted that there was pain when scanning over what appears to be the gallbladder and pancreatic region. While no inflammation was noted, you could consider running a quantitative PLI to evaluate for possible inflammation of the pancreas, which was not appreciated on today's exam.

**SPECIES**

Canine

For my initial evaluation of a PU/PD patient, I will typically recommend quantitating water intake, so it can be monitored. Recommend a urinalysis and culture, thoracic radiographs, evaluation of calcium level as well as electrolytes. If an obvious cause is not identified initially, then I will typically recommend a liver function test, screen for Addison's disease, perform abdominal imaging (already done), as well as radiographs, and work my way through the differentials. I will provide a list of differentials for PU/PD that I typically consider.

**BREED**

Mix

There is a foreign object in the stomach, which can be seen on radiographs. This is not readily seen on ultrasound, although there may be a hint. This is likely an incidental finding, but should be monitored, and could be an indication that other foreign material has been ingested.

**SEX**

Spayed Female

An obvious lesion responsible for the reported increase in thirst and urination was not visualized. Some issues such as early renal disease, cushings disease, behavioral issues, neurologic disease, dietary issues, electrolyte disturbances etc.. are not able to be diagnosed with ultrasound alone. These can be challenging cases. The top 10 differentials can be ruled in/out with routine bloodwork, urinalysis and culture. Several more can be evaluated with a good history and imaging. Unfortunately, as you work your way down the list the differentials become harder to definitively diagnose. This is the differential list I start with:

**AGE**

7 Years

**WEIGHT**

72 Pounds

- (1) Hyperadrenocorticism (may be a mixed primary PU and PD)
- (2) Hypoadrenocorticism (either Addison's or hypocortisolism)
- (3) Hypercalcemia
- (4) Diabetes Mellitus
- (5) Liver Disease (hepatic encephalopathy may be a mixed primary PU and PD)
- (6) Pyelonephritis
- (7) Leptospirosis (can present without azotemia)
- (8) Chronic Renal Disease/Renal Failure (can present pre-azotemic, especially in dogs, but expect the BUN & creatinine not to be at the low end of the reference range)
- (9) Hyperthyroidism
- (10) Hypokalemia

**INTERPRETED BY**

Kathleen Sennello DVM,  
MS, Diplomate ACVIM  
(Small Animal Internal  
Medicine)

- (11) Pyometra (including stump pyometra in spayed dogs)
- (12) Renal Tubular Diseases (glycosuria or Fanconi & Fanconi-like syndromes or RTA)
- (13) Chronic Partial Urinary Obstruction or Post-Obstructive Diuresis
- (14) Iatrogenic Disease due to medications (diuretics, phenobarbital, KBr; diets either high in salt [such as S/D] or very low in protein (such as U/D))

**IMAGING PERFORMED BY**

Dr. Ebersole

- (15) Pheochromocytoma
- (16) Polycythemia
- (17) Hypertension Acromegaly (expect these patients to have diabetes)
- (18) Paraneoplastic Syndromes (particularly splenic hemangiosarcoma?)
- (19) Pericardial Effusion

**HOSPITAL NAME**

Scanvet

**REFERRING VET**

Dr. Kaltsas

- (20) Atypical Cushing's and SARDS Psychogenic Polydipsia (as in a true behavior disorder with a compulsive element)
- (21) Primary Non-Medical Polydipsia (aka "I drink a lot because I like it or I engage in activities that promote it, but that doesn't mean I'm sick")
- (22) Psychogenic Polydipsia (as in a true behavior disorder with a compulsive element)

**INVOICE**

36230

- (23) Acromegaly (expect these patients to have diabetes)
- (24) Primary Nephrogenic Diabetes Insipidus (Congenital Nephrogenic Diabetes Insipidus, other diseases that cause primary PU other than Congenital Diabetes Insipidus would be considered Acquired Nephrogenic Diabetes Insipidus)
- (25) Central Diabetes Insipidus

**DATE**

3/16/22



**PATIENT**

Risa Davis

\*\*Keep in mind that diabetes insipidus is a VERY rare disorder and that water deprivation tests are rarely/if ever recommended-if possible consider referral to an internal medicine specialist if reaching that point.

**SPECIES**

Canine

**BREED**

Mix

**SEX**

Spayed Female

**AGE**

7 Years

**WEIGHT**

72 Pounds

**INTERPRETED BY**

Kathleen Sennello DVM,  
MS, Diplomate ACVIM  
(Small Animal Internal  
Medicine)

**IMAGING  
PERFORMED BY**

Dr. Ebersole

**HOSPITAL NAME**

Scanvet

**REFERRING VET**

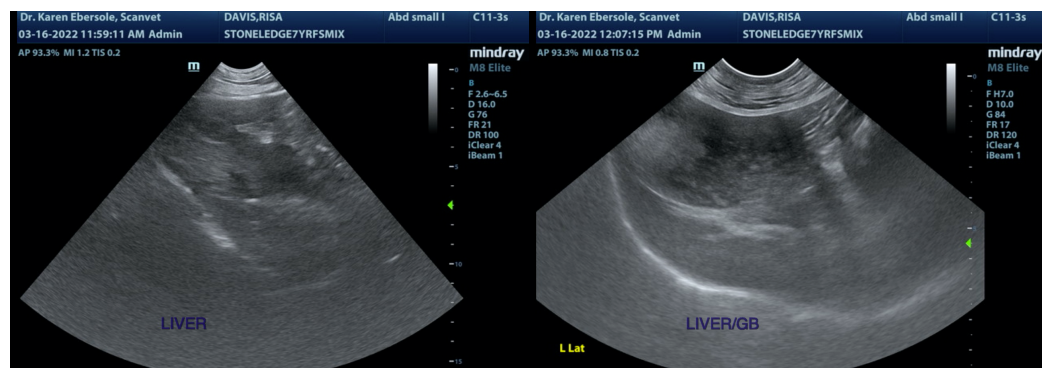
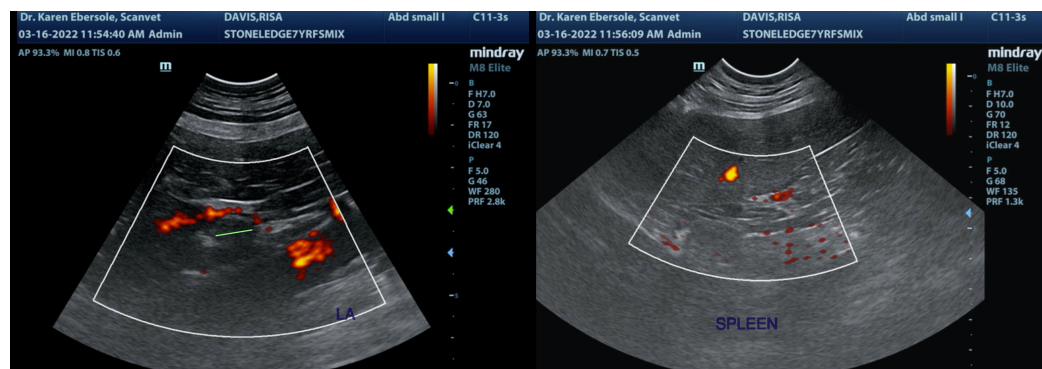
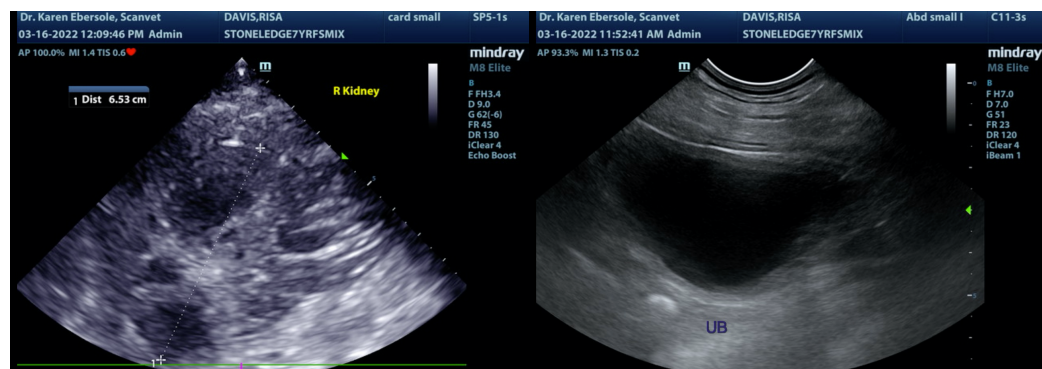
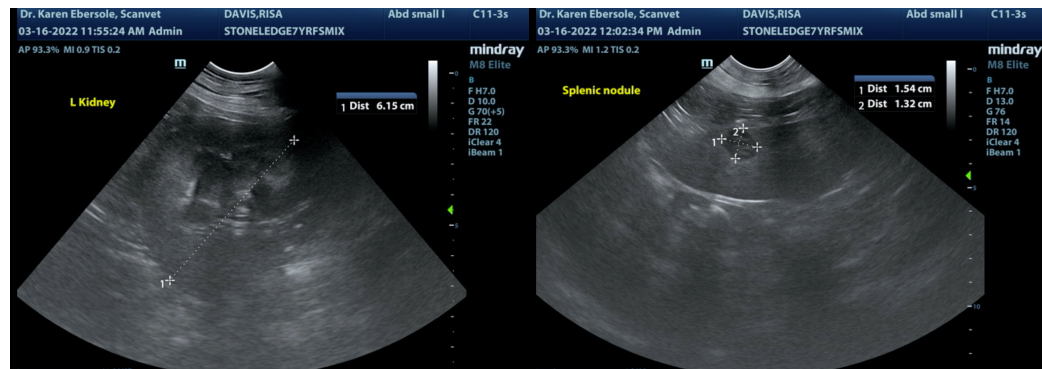
Dr. Kaltsas

**INVOICE**

36230

**DATE**

3/16/22





**PATIENT**

Risa Davis

The information and recommendations provided are based on the images presented by the referring veterinarian/sonographer. No evaluation can be communicated regarding pathology that was not visible in the image/video clips provided.

**SPECIES**

Canine

Thank you for this referral. If the clinical or image interpretation does not parallel your findings or if I can be of any further assistance please contact me.

Kathleen Sennello DVM,MS, Diplomate ACVIM (Small animal Internal Medicine)

kathleen.sennello@sonopath.com

**BREED**

Mix

**SEX**

Spayed Female

**AGE**

7 Years

**WEIGHT**

72 Pounds

**INTERPRETED BY**

Kathleen Sennello DVM,  
MS, Diplomate ACVIM  
(Small Animal Internal  
Medicine)

**IMAGING  
PERFORMED BY**

Dr. Ebersole

**HOSPITAL NAME**

Scanvet

**REFERRING VET**

Dr. Kaltsas

**INVOICE**

36230

**DATE**

3/16/22