**PATIENT**

Andy Bernard FTLOC

SPECIES

Feline

BREED

Bengal

SEX

Neutered Male

AGE

11 Years

WEIGHT

5 Pounds

INTERPRETED BYKathleen Sennello DVM,
MS, Diplomate ACVIM
(Small Animal Internal
Medicine)**IMAGING
PERFORMED BY**

Amy Mayhew, LVT

HOSPITAL NAME

SVS Imaging Michigan

REFERRING VETWixom Family Pet
Practice**INVOICE**

36207

DATE

3/15/22

PRESENTING CLINICAL SIGNS

Presents for AUS. Weight loss, intermittent decreased appetite, intermittent vomiting, and chronic diarrhea (no resolution with therapy).

Abnormal PE/Chem/CBC/UA Results: See attached record/BW. GI panel and Diarrhea PCR panel collected today and pending.

ULTRASONOGRAPHIC EXAMINATION OF THE ABDOMEN**Urinary System**

The urinary bladder is moderately distended with anechoic urine. The Bladder wall, trigone, ureteral papillae and visible urethra (to a depth of 2cm) appear normal with no evidence of wall thickening, mucosal irregularities, masses or cystic calculi.

The left kidney has a normal shape and size (3.21 cm). Overall echogenicity is slightly hyperechoic with poor corticomedullary distinction and a typical 1:3 cortex:medulla ratio. There is no evidence of perinephric inflammation or effusion. There is no evidence of pyelectasia, nephroliths, infarcts or hydroureter. Renal vasculature is normal.

The right kidney has a normal shape and size (3.39 cm). Overall echogenicity is slightly hyperechoic with poor corticomedullary distinction and a typical 1:3 cortex:medulla ratio. There is no evidence of perinephric inflammation or effusion. There is no evidence of pyelectasia, nephroliths, infarcts or hydroureter. Renal vasculature is normal.

Adrenal Glands

The left adrenal gland is normal in size measuring 0.43 cm at the caudal pole. It is observed in its normal position cranial to the left renal artery. It is normal in appearance (uniformly hypoechoic) and shape with no evidence of a mass effect.

The right adrenal gland is normal in size measuring 0.27 cm at the caudal pole. It is observed in its normal position between the cranial aspect of the right kidney and the caudal vena cava. It is normal in appearance (uniformly hypoechoic) and shape with no evidence of a mass effect.

Spleen

The spleen is subjectively normal in size, echotexture is homogenous, and the splenic capsule is smooth with no irregularities. The blood flow through the hilus and splenic parenchyma appears normal. No focal parenchymal abnormalities are visualized.

Liver

The liver is subjectively normal in size, and echogenicity with smooth peripheral margins. The parenchyma is homogenous echotexture. The visible portions of the vasculature and biliary tract appear normal. No focal nodules or cystic lesions are observed.


The gallbladder lumen is moderately distended. The wall of the gall bladder is not thickened and has a smooth mucosal surface. Luminal contents are primarily anechoic. The cystic and common bile ducts are normal/not visible.

Gastrointestinal

The stomach contains minimal luminal contents. It measures at a normal thickness of <0.36cm with some variability due to the presence of rugal folds. The distinction of the gastric wall layers is adequate and there is no impression of reduced peristaltic activity. No masses or focal lesions were observed.

IMAGING PERFORMED BY

SVS Mobile Imaging MI 734-637-7711
svsimagingmi@gmail.com



PATIENT

Andy Bernard FTLOC

SPECIES

Feline

BREED

Bengal

SEX

Neutered Male

AGE

11 Years

WEIGHT

5 Pounds

INTERPRETED BY

Kathleen Sennello DVM,
MS, Diplomate ACVIM
(Small Animal Internal
Medicine)

IMAGING PERFORMED BY

Amy Mayhew, LVT

HOSPITAL NAME

SVS Imaging Michigan

REFERRING VET

Wixom Family Pet
Practice

INVOICE

36207

DATE

3/15/22

The visualized areas of duodenum, jejunum and ileum have a uniform diameter with minimal fluid distension. Wall thickness is normal to slightly increased. Bowel loops follow a typical curvilinear path with distinct wall layering, but some areas display a prominent muscularis layer which does not display the typical 1:3 muscularis:mucosa layer ratio. Duodenum wall measured 0.32 cm. Jejunum wall measured 0.30 cm. Visualized peristalsis appears appropriate. There were no focal lesions consistent with obstruction or a mass effect observed.

The ileocecal junction was visualized and exhibited normal intact wall layering and is subjectively of normal thickness. Sections of colon are visualized with formed fecal material and gas shadowing distally. There is no observed focal or generalized colon wall thickening or loss of layering.

Pancreas

The pancreas is prominent and mottled compared to the surrounding isoechoic mesentery. There is no evidence of nodules or cystic lesions. There is no evidence of regional mesenteric inflammation or fluid.

Free Abdomen

There is a scant amount of free abdominal fluid. There are prominent mesenteric lymph nodes visualized, measuring 0.79, 0.85, and 0.51 cm. The omentum is generally of normal echogenicity.

ULTRASONOGRAPHIC FINDINGS

- Prominent, mottled pancreas – The pancreatic changes are most consistent with age-related parenchymal remodeling, potentially secondary to a prior inflammatory episode, early fibrosis or chronic pancreatitis.
- Thickened small intestine with prominent muscularis layer – The small intestinal wall changes are most consistent with an inflammatory process (i.e., inflammatory bowel disease) with a low possibility of emerging lymphoma.
- Prominent mesenteric lymph nodes – The prominent abdominal lymph nodes are most consistent with reactive lymphadenitis or lymphoid hyperplasia. Neoplastic infiltration is considered less likely.
- Scant free abdominal fluid
- Decreased corticomedullary distinction in both kidneys – Mild loss of corticomedullary distinction in both kidneys could be consistent with chronic degenerative disease or interstitial nephrosis.

INTERPRETATION OF THE FINDINGS & FURTHER RECOMMENDATIONS

No focal mass lesions or obstruction are noted associated with the GI tract. There is a mild lymphadenopathy present along with a prominent muscularis layer and mild bowel thickening, most consistent with inflammatory disease, although other differentials are possible.

- Consider a novel protein/hydrolyzed protein prescription diet.
- Recommend chronic probiotic therapy.
- Recommend a GI panel to Texas A&M for a qualitative fPLI, TLI, cobalamin and folate to further evaluate the pancreas and small intestine.
- If symptoms persist, recommend obtaining GI biopsies.
- Consider three view thoracic radiographs to rule out concurrent thoracic disease/involvement.

IMAGING PERFORMED BY

SVS Mobile Imaging MI 734-637-7711
svsimagingmi@gmail.com



PATIENT

Andy Bernard FTLOC

SPECIES

Feline

BREED

Bengal

SEX

Neutered Male

AGE

11 Years

WEIGHT

5 Pounds

INTERPRETED BY

Kathleen Sennello DVM,
MS, Diplomate ACVIM
(Small Animal Internal
Medicine)

**IMAGING
PERFORMED BY**

Amy Mayhew, LVT

HOSPITAL NAME

SVS Imaging Michigan

REFERRING VET

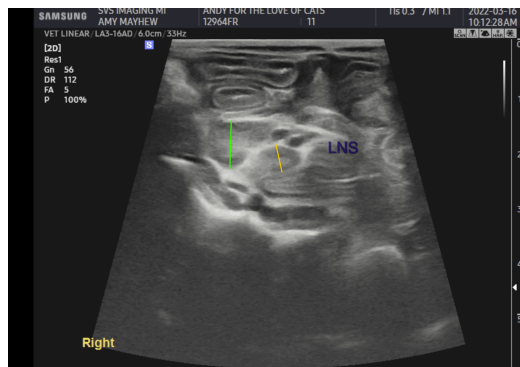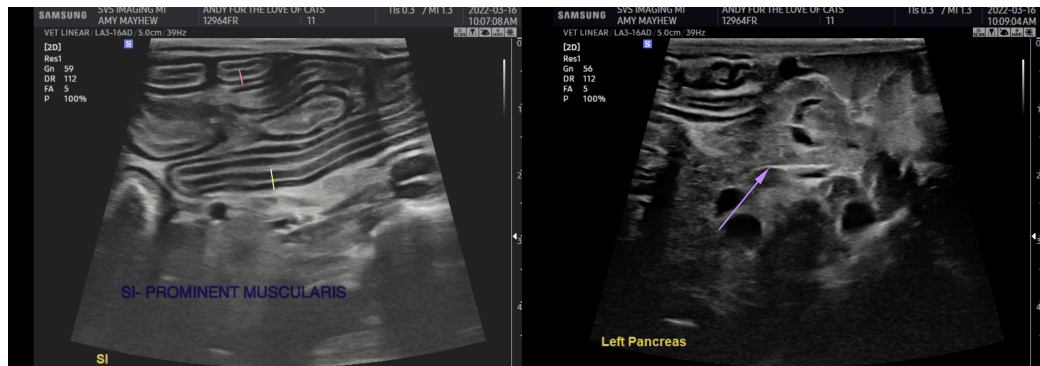
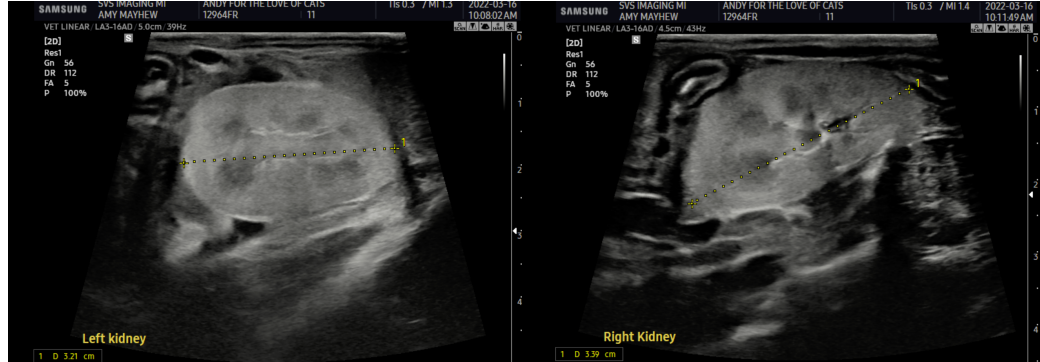
Wixom Family Pet
Practice

INVOICE

36207

DATE

3/15/22



The information and recommendations provided are based on the images presented by the referring veterinarian/sonographer. No evaluation can be communicated regarding pathology that was not visible in the image/video clips provided.

Thank you for this referral. If the clinical or image interpretation does not parallel your findings or if I can be of any further assistance please contact me.

Kathleen Sennello DVM,MS, Diplomate ACVIM (Small animal Internal Medicine)

kathleen.sennello@sonopath.com