

**DATE PRESENTING CLINICAL SIGNS**

3/15/23 Chronic hematuria. Occasional episodes of inappropriate urination in the house.

**PATIENT**

Zoey Harizopoulou

Current Medications: none currently. has been prescribed amlodipine 2.5mg sid; yunnan baiyo 1 capsule daily.

Lab Results: bp on 8.2022 measured at 180. improved after instituting amlodipine (which owner has since discontinued). last workup 8.2022: cadetBRAF negative, hematuria in several urine samples, bun 35, creat 0.7

**SPECIES**

Canine

Date of Previous IntraPet Ultrasound: No previous.

Sedation: Not required to complete full diagnostic ultrasound.

Stat Report: Not requested.

**BREED**

Shih Tzu

Imaging Performed By: Stephanie Warga RDCS, RVT.

**ULTRASONOGRAPHIC EXAMINATION OF THE ABDOMEN****SEX**

Spayed Female

**Urinary System**

The urinary bladder is mildly distended with anechoic urine. The Bladder wall appears slightly irregular, but not overtly thickened. The region of the trigone, ureteral papillae and proximal urethra appear free of any mass lesions or calculi. Consider evaluation for cystitis and reevaluation of the urinary bladder when more distended.

**AGE**

1/6/08

The left kidney has a normal shape and size (4.61 cm) with numerous small cortical cysts and mild pyelectasia at 0.22 cm. Overall echogenicity is normal with mildly reduced corticomedullary distinction and a typical 1:3 cortex:medulla ratio. There is no evidence of focal perinephric inflammation or effusion. There is no evidence of nephroliths, infarcts or hydroureter. Renal vasculature is normal.

**WEIGHT**

13.5 Pounds

The right kidney is large and irregular in shape, measuring 6.43 cm in length, with decreased corticomedullary distinction and a typical 1:3 cortex:medulla ratio. Pyelectasia is noted. There is a large mixed echogenic, partially cystic, partially mineralized mass effect on the cranial pole of the right kidney measuring 4.59 cm x 5.19 cm. The cystic fluid is somewhat echogenic and appears to communicate with the renal pelvis. This could be consistent with blood, infection, etc. There is no evidence of focal perinephric inflammation or effusion. There is no evidence of nephroliths, infarcts or hydroureter. Renal vasculature is normal.

**INTERPRETED BY**

Kathleen Sennello DVM,  
MS, Diplomate ACVIM  
(Small Animal Internal  
Medicine)

**HOSPITAL NAME**

Stevenson Village VH

**Adrenal Glands**

The left adrenal gland is normal in size measuring 0.65 cm at the caudal pole. It is observed in its normal position cranial to the left renal artery. It is normal in appearance (uniformly hypoechoic) and shape with no evidence of a mass effect.

**REFERRING VET**

Dr. Feinberg

The right adrenal gland is large in size and somewhat irregular in shape, measuring 1.34 cm in diameter at the cranial pole and 0.70 cm at the caudal pole. Length is 2.3 cm. It is observed in its normal position between the cranial aspect of the right kidney and the caudal vena cava. It appears abnormal in that the cranial pole is somewhat hypoechoic, creating the impression of a nodule measuring approximately 1.34 cm x 1.86 cm. No evidence of vascular invasion is visualized.

**INVOICE**

45930

**Spleen**

The spleen is subjectively normal in size, echotexture is homogenous, and the splenic capsule is smooth with no irregularities. The blood flow through the hilus and splenic parenchyma appears normal. No focal parenchymal abnormalities are visualized.

**Liver**

The liver is large size with smooth peripheral margins. The parenchyma is hyperechoic and heterogeneous in echotexture. The visible portions of the vasculature and biliary tract appear normal. There are numerous ill-

defined hypoechoic nodules scattered throughout the hepatic parenchyma. Additionally, there is an isoechoic nodule visualized on the left side measuring 1.26 cm x 0.70 cm.

The gall bladder lumen is moderately distended. The wall of the gall bladder is not thickened and has a smooth mucosal surface. There is a moderate amount of non-organized echogenic debris. The cystic and common bile ducts are normal/not visible.

### ***Gastrointestinal***

The stomach contains minimal luminal contents. It measures at a normal thickness of <0.7cm with some variability due to the presence of rugal folds. The distinction of the gastric wall layers is adequate and there is no impression of reduced peristaltic activity. No masses or focal lesions were observed.

The visualized areas of duodenum, jejunum and ileum have a relatively uniform diameter with minimal fluid distension. Wall thickness is normal. Bowel loops follow a curvilinear path with distinct wall layering maintaining the typical 1:3 muscularis:mucosa layer ratio. Duodenum wall measures 0.46 cm. Jejunum wall measures 0.33 cm. Visualized peristalsis appears appropriate. There were no focal lesions consistent with obstruction or a mass effect observed.

The ileocecal junction was visualized and exhibited normal intact wall layering and is subjectively of normal thickness. Sections of colon are visualized with formed fecal material and gas shadowing distally. There is no observed focal or generalized colon wall thickening or loss of layering.

### ***Pancreas***

The pancreas is normal and isoechoic to surrounding mesentery. There is no evidence of nodules or cystic lesions. There is no evidence of regional mesenteric inflammation or fluid.

### ***Free Abdomen***

Evaluation of the peritoneal cavity did not reveal any evidence of effusion, or subjective lymphadenomegaly. The Medial iliac nodes appear normal and there was no evidence of a caudal aortic thrombus at the bifurcation. The omentum is of normal uniform echogenicity.

## **PRIMARY FINDINGS**

- Decreased corticomedullary distinction in both kidneys with bilateral pyelectasia – Mild loss of corticomedullary distinction in both kidneys could be consistent with chronic degenerative disease or interstitial nephrosis. Pyelectasia of the kidney(s) could be consistent with pyelonephritis, chronic renal disease, secondary to PU/PD or fluid therapy (if applicable), other.
- Large, heterogeneous, hyperechoic liver with numerous ill-defined nodules and an isoechoic nodule – The diffuse hepatic changes are non-specific and could be consistent with vacuolar hepatopathy, nodular hyperplasia, inflammatory/immune-mediated disease, fibrosis, extramedullary hematopoiesis, toxic hepatopathy (e.g., copper), infiltrative neoplasia (less likely) or other hepatopathy. The nodules are indistinct and have a somewhat benign appearance, but underlying neoplastic change cannot be ruled out.
- Large, mixed echogenic, partially cavitated and mineralized mass effect on the cranial pole of the right kidney – Findings are concerning for a benign or neoplastic mass lesion. Consider a fine needle aspirate.
- Large cranial pole of the right adrenal gland – Adrenomegaly could be consistent with neoplasia (e.g., adenoma, carcinoma, pheochromocytoma), hyperplasia, inflammation, other.

## SECONDARY FINDINGS

- Slightly irregular, mildly distended urinary bladder – Findings could be consistent with lack of urine distention, cystitis, etc. Consider a urinalysis, culture, and reevaluation of the urinary bladder when distended.
- Moderate gallbladder debris – The significance of the aggregated gallbladder debris is unclear. This could represent an early mucocele, cholestasis, or may be secondary to fasting but seems unlikely to be causing a current issue. Recommend continued monitoring.

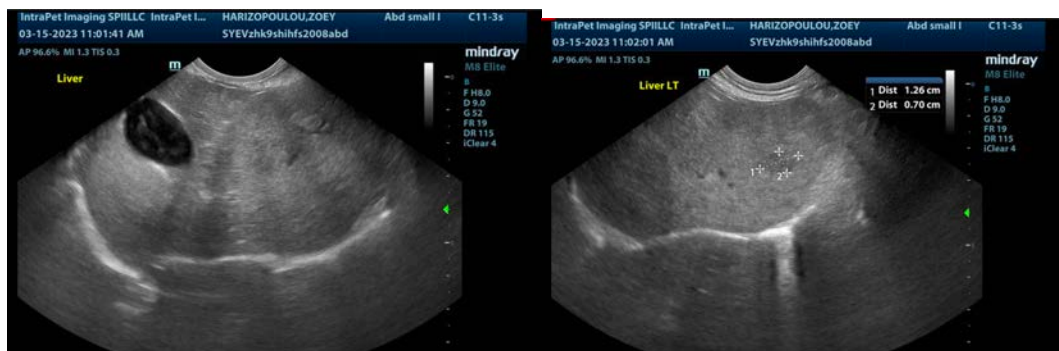
## INTERPRETATION OF THE FINDINGS & FURTHER RECOMMENDATIONS

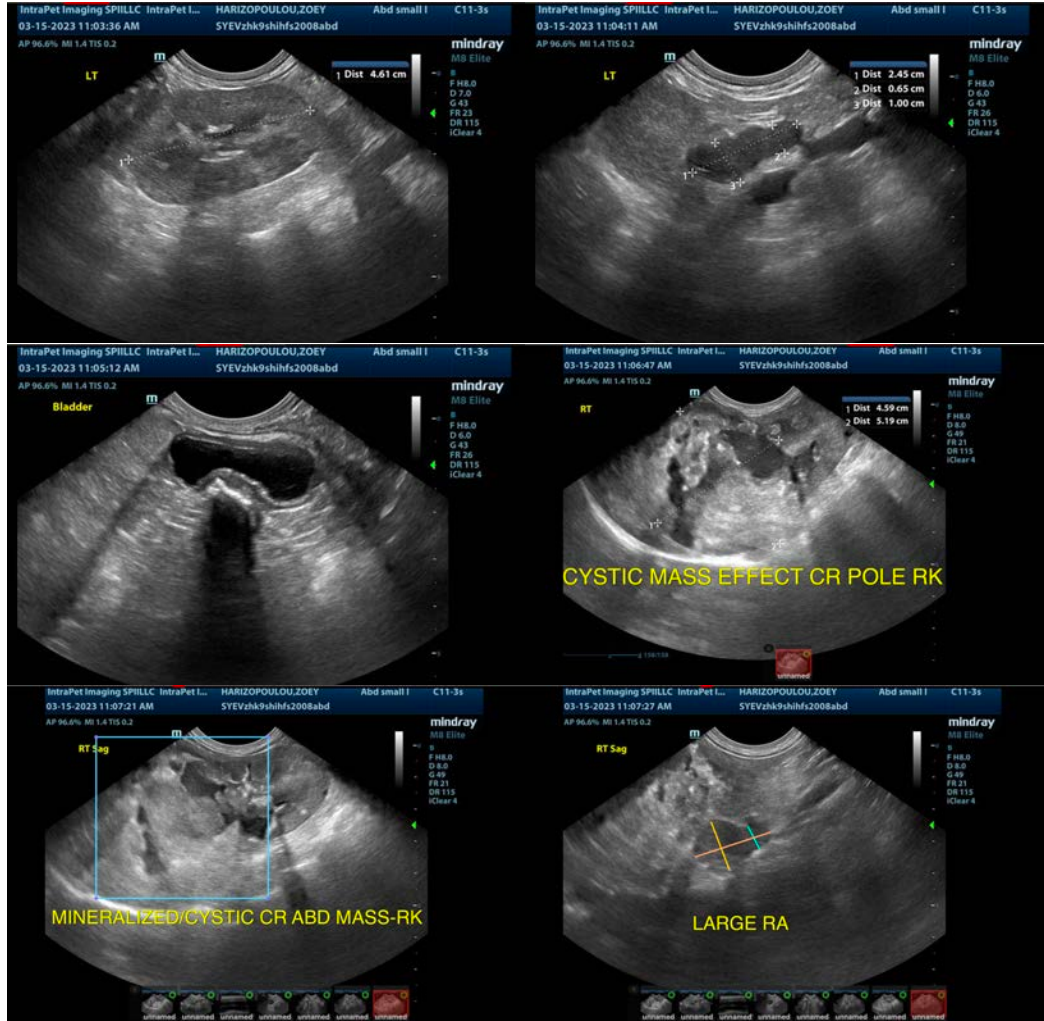
There is a large, irregular, partially cystic and mineralized mass effect on the cranial pole of the right kidney. This is concerning for the source of the hematuria noted and is concerning for a possible true mass effect (Benign or cancerous). A fine needle aspirate of a more solid region of the kidney could be considered, as long as coagulation parameters are normal and blood pressure is normal, as this would help to better determine prognosis, etc., but I suspect nephrectomy would be necessary to alleviate the hematuria regardless of the type of lesion present. If nephrectomy is considered, use caution regarding residual renal function in an older pet. Alternately, if the patient is relatively asymptomatic, palliative care could be considered. A urinalysis and culture should be performed, as secondary infection could be present.

The changes observed in the liver are non-specific. Correlate this with clinical signs and lab work values. Although there are focal nodules visualized, these could represent benign regenerative nodules, etc., although metastatic lesions from the kidney mass cannot be definitively ruled out (but seem less likely).

The right adrenal gland is enlarged. This could represent a benign or neoplastic lesion and could be secreting hormones or be non-active. Additionally, this could be contributing to the hypertension (or the renal mass could be contributing to the hypertension). Options moving forward would include advanced imaging if surgical intervention is desired. You could consider adrenal function testing if signs of Cushing's are present, but interpretation may be challenging, given the concurrent medical issues. Or, if this is relatively asymptomatic, and surgery is not desired, continued monitoring with ultrasound could be considered.

Recommend three view thoracic radiographs to evaluate for possible concurrent thoracic disease/involvement.





The information and recommendations provided are based on the images presented by the referring veterinarian/sonographer. No evaluation can be communicated regarding pathology that was not visible in the image/video clips provided.

Thank you for this referral. If the clinical or image interpretation does not parallel your findings or if I can be of any further assistance please contact me.

Kathleen Sennello DVM,MS, Diplomate ACVIM (Small animal Internal Medicine)  
 kathleen.sennello@sonopath.com